



# ACTAS Derma-Sifiliográficas

Full English text available at  
www.actasdermo.org



## CASE FOR DIAGNOSIS

### Skin Tumors Arising on Chronic Lymphedema ☆



#### Lesiones tumorales cutáneas sobre linfedema crónico

#### Medical History

An 88-year-old woman with dependence in activities of daily living presented with chronic lymphedema secondary to left breast cancer treated with radical mastectomy, ipsilateral lymphadenectomy, radiotherapy, and chemotherapy 10 years earlier. Four months before this visit, she started to develop hematoma-like lesions on her left forearm. The lesions grew fast, causing pain and bleeding and prompting her to visit the emergency department, where she was evaluated by a dermatologist.

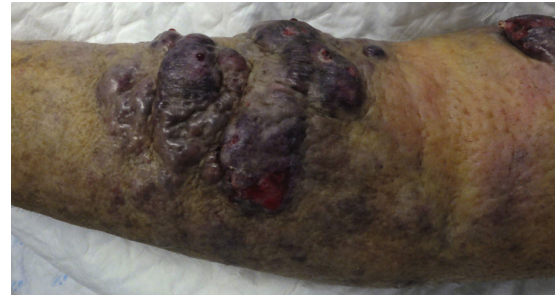

Figure 1

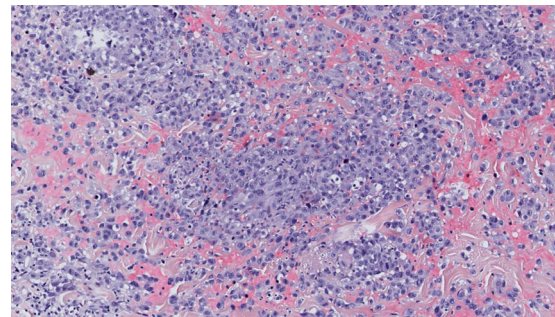


Figure 2 Hematoxylin-eosin, original magnification  $\times 40$ .

#### Physical Examination

Edematous right upper limb with multiple edematous, violaceous tumor lesions with a diameter of 3 cm to 10 cm. The lesions had an elastic-like consistency and some of them were ulcerated and bleeding (Fig. 1). In the left chest area, near the mastectomy scar, there were 2 isolated 1-cm lesions with similar characteristics.

#### Histopathology

The histopathologic study showed a dermal sheetlike proliferation of pleomorphic cells, many of which formed a solid pattern. The cells were round and had vesicular nuclei and prominent eosinophilic nucleoli. Abundant mitoses and hematic extravasation were also observed (Fig. 2). Immunohistochemical staining was positive for CD34 (Fig. 3) and ERG, and negative for cytokeratin, protein S100, GATA3, myeloperoxidase, CD56, and human herpesvirus 8. A genetic alteration in the *c-Myc* oncogene (chromosome 8q24.21) was detected by fluorescent in situ hybridization.

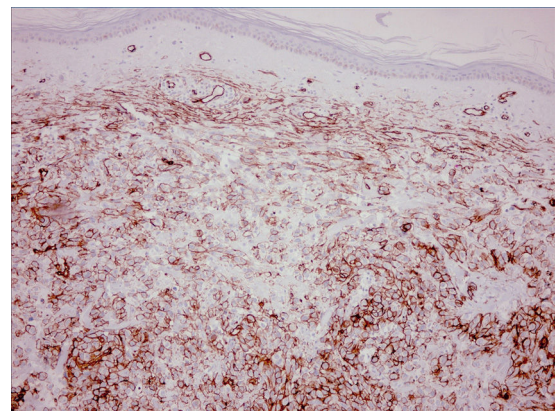


Figure 3 CD34 immunohistochemical staining (original magnification  $\times 10$ ).

### What is your diagnosis?

☆ Please cite this article as: Latour-Álvarez I, Vázquez-Rodríguez C, García-Bustinduy M. Lesiones tumorales cutáneas sobre linfedema crónico. Actas Dermosifiliogr. 2018;109:439–440.

## Diagnosis

Lymphangiosarcoma associated with chronic lymphedema (Stewart-Treves syndrome)

## Clinical Course and Treatment

Following consultation with the Sarcoma Committee, the option of intensive treatment was rejected due to the patient's baseline characteristics. The patient died 1 month after diagnosis.

## Comment

Angiosarcoma is an uncommon tumor derived from the endothelium of lymph and blood vessels. In 1948, Stewart and Treves<sup>1</sup> described an association between angiosarcoma and chronic lymphedema following lymphadenectomy due to breast cancer. Stewart-Treves syndrome has an estimated incidence of between 0.07% and 0.45%. As in our case, it tends to present with multifocal, normally ipsilateral, lesions several years after lymphadenectomy for breast cancer. The mean time to onset is approximately 10 years and the mean age of presentation is 60 years.<sup>2</sup> Although the etiology and pathogenesis are not well established, current pathogenic theories hold that lymphedema, regardless of its cause (radiation, surgery, or other), triggers an angiogenic stimulus in the area of the edema leading to the formation of new collateral lymph and blood vessels. The presence of this continuous angiogenic stimulus might then trigger the appearance of malignancies, such as Stewart-Treves syndrome or Kaposi sarcoma.<sup>3</sup>

Angiosarcoma lesions associated with chronic lymphedema or secondary to radiotherapy have relatively consistent genetic alterations. The most common alterations are amplifications in chromosome 8q24.21 (50%), 10p12.33 (33%), and 5q35.3 (11%).<sup>4</sup>

The main entities that should be contemplated in the differential diagnosis are Kaposi sarcoma, metastases

from breast cancer, and melanoma. Treatment options are limited. Radical surgery, chemotherapy, and immunotherapy have all been used, but they do not appear to have any impact on survival. Prognosis is very poor and mean survival is 20 months after diagnosis.<sup>2,3</sup> We have presented a new case of Stewart-Treves syndrome, which, while uncommon, is important to keep in mind considering the high number of lymphadenectomies performed.

## Conflicts of Interest

The authors declare that they have no conflicts of interest.

## References

1. Stewart FW, Treves N. Lymphangiosarcoma in postmastectomy lymphedema: A report of six cases in elephantiasis chirurgica. *Cancer*. 1948;1:64–81.
2. Berebichez-Fridman R, Deutsch YE, Joyal TM, Olvera PM, Benedetto PW, Rosenber AE, et al. Stewart-Treves syndrome: A case report and review of the literature. *Case Rep Oncol*. 2016;9:205–11.
3. Rodríguez-Bujaldón A, Vázquez-Bayo MC, Galán-Gutiérrez M, Jiménez-Puya R, Vélez García-Nieto A, Moreno-Giménez JC, et al. Angiosarcoma sobre linfedema crónico. *Actas Dermosifiliogr*. 2006;97:525–8.
4. Fuertes L, Santonja C, Kutzner H, Requena L. Inmunohistoquímica en dermatopatología: revisión de los anticuerpos utilizados con mayor frecuencia (parte I). *Actas Dermosifiliogr*. 2013;104:99–127.

I. Latour-Álvarez,\* C. Vázquez-Rodríguez,  
M. García-Bustínduy

*Departamento de Dermatología, Hospital Universitario de Canarias, Santa Cruz de Tenerife, Islas Canarias, España*

\* Corresponding author.

*E-mail address:* irenelatouralvarez@gmail.com

(I. Latour-Álvarez).