




ACTAS Derma-Sifiliográficas

Full English text available at
www.actasdermo.org



CASE AND RESEARCH LETTERS

Dermatopathic Lymphadenopathy: Is Our Diagnostic Approach Correct?☆



Linfadenopatía dermopática: ¿realizamos una correcta aproximación diagnóstica?

To the Editor:

Dermatopathic lymphadenopathy is a well-defined histopathologic entity with an underestimated prevalence in the general population. It is characterized by lymph node enlargement secondary to a typically pruritic skin disorder.¹ It is a form of paracortical hyperplasia that usually occurs in chronic skin diseases, but it can also be found in disorders in which the skin is not involved.² In most cases, dermatopathic lymphadenopathy clinically manifests as enlargement of the peripheral lymph nodes, although normal-sized nodes may also be seen. It should be contemplated alongside malignant, infectious, and other diseases in the differential diagnosis of peripheral lymphadenopathy. It is widely known that a palpable lymph node is a clinical sign and risk marker of a solid or lymphoproliferative tumor,³ and it is therefore essential to establish a diagnosis and monitor patients with this finding. When attending a patient with a chronic skin disorder who presents with enlarged lymph nodes, it is important to consider a broad differential diagnosis that includes autoimmune diseases,⁴ infections, and tumors.

We performed a retrospective analysis of clinically diagnosed and histologically confirmed cases of dermatopathic lymphadenopathy cases at our unit between January 2011 and December 2016. We included 4 patients, whose characteristics are summarized in Table 1. The main diagnosis for which they were under follow-up was atopic dermatitis and there was also an isolated case of lepromatous leprosy. The atopic patients had a Scoring Atopic Dermatitis (SCORAD) index score of over 40 at the time of diagnostic confirmation. They also all had active skin lesions. Palpable lymph nodes had been identified in different locations during the physical examination. They were mostly located in the axillary, groin, and neck regions, which were investigated by ultrasound and/or computed tomography (Fig. 1). Depend-

ing on their accessibility, the nodes were sampled by biopsy or fine-needle aspiration (FNA) (Figs. 2 and 3). Follow-up duration ranged from 6 months to 5 years. The lymph nodes disappeared in 3 of the 4 patients and reduced considerably in size in the fourth, whose atopic dermatitis is currently being treated with combined oral corticosteroid and intravenous immunoglobulin therapy. None of the patients have presented any signs of malignancy.

Dermatopathic lymphadenopathy is a benign entity with characteristic histologic features that is frequently seen in patients with inflammatory skin disease. It was first described by Pautrier and Woringer in 1937, but the term *dermatopathic lymphadenopathy* did not appear until 1942, when it was coined by Hurwitt.⁵ Dermatopathic lymphadenopathy should always be contemplated in patients with persistent lymph node enlargement. It can accompany different types of chronic skin disorders and is more common in patients with extensive skin involvement. Lymph node enlargement tends to be asymptomatic and mainly affects inguinal, axillary, and cervical nodes. The lymph nodes tend to be mobile and not attached to underlying structures.

The characteristic histologic findings include slightly expanded germinal centers surrounded by lymphocytes and a widened paracortical area. The follicular pattern is retained. The most characteristic finding is an expanded paracortical area and pale staining due to the presence of Langerhans cells and in particular interdigitating dendritic cells. Macrophages are a minor component, but they are characteristic because they contain cytoplasmic pigment; most of the cells contain melanin but a small proportion contain hemosiderin. Pigment deposits may also be observed in tattoos, nodal nevus cell inclusions, and melanoma metastases.⁶

A broad differential diagnosis must be considered in the case of persistent lymph node enlargement. Dermatopathic lymphadenopathy occurs in association with a variety of skin disorders ranging from infections, such as tuberculosis or fungal infections, to erythrodermas, such as psoriatic or atopic erythrodermas (like the cases in our series). Other disorders include sarcoidosis, lymphoproliferative disorders, tumor metastases,⁷ and infections (e.g., human immunodeficiency virus infection, tuberculosis, and toxoplasmosis). Dermatopathic lymphadenopathy may also be seen in exfoliative or eczematous diseases, such as toxic shock syndrome, pemphigus, neurodermatitis, and atrophica cutis senilis.⁷ Prognosis is worse when there is associated mycosis fungoides.

The first step in the diagnostic workup is nodal sampling by FNA and/or biopsy. Prior imaging can help identify the extent of disease and select the most appropriate node for

☆ Please cite this article as: Bueno-Rodríguez A, Ruiz-Villaverde R, Caba-Molina M, Tercedor-Sánchez J. Linfadenopatía dermopática: ¿realizamos una correcta aproximación diagnóstica? Actas Dermosifiliogr. 2018;109:361–363.

Table 1 Clinical, Imaging, and Histologic Characteristics of 4 Patients With Dermatopathic lymphadenopathy.

	Patient 1	Patient 2	Patient 3	Patient 4
Diagnosis	Atopic dermatitis	Atopic dermatitis	Atopic dermatitis	Atopic dermatitis
Location	Inguinal/axillary	Cervical	Cervical	Axillary
Age, y	46	56	37	28
Imaging study	CT	Ultrasound	Ultrasound	CT
Histopathologic study	FNA/biopsy	FNA/biopsy	FNA/biopsy	Biopsy
Surgical	No	No	No	Yes
Time to resolution	7 mo	6 mo	8 mo	Persistence (> 12 mo)

Abbreviations: CT, computed tomography; FNA, fine-needle aspiration.

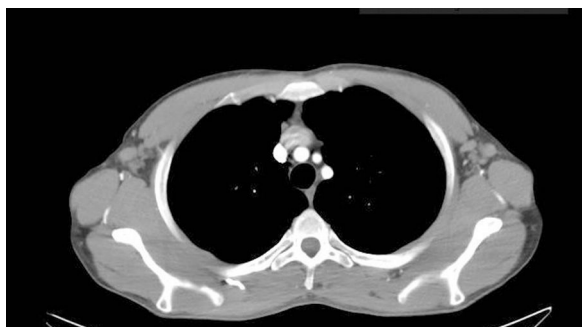

Figure 1 Patient 4. Computed tomography scan of chest and abdomen: enlarged bilateral axillary lymph nodes with a diameter of up to 13.7 mm at the narrowest point on both sides.

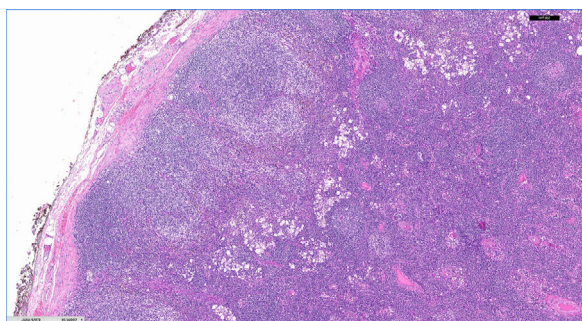


Figure 2 Patient 4 (hematoxylin-eosin original, original magnification $\times 5$): lymph node with preserved architecture presenting hyperplasia of lymphoid follicles in the cortex with pale staining in paracortical area.

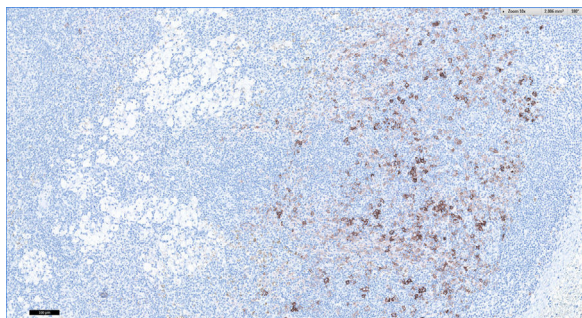


Figure 3 Patient 4 (CD1A $\times 10$), original magnification. Note the paracortical hyperplasia composed of Langerhans cells.

biopsy. Considering its increasing use as a diagnostic tool in dermatology, cutaneous ultrasound should also be considered. Inflammatory lymph nodes tend to have an ellipsoid shape with a length to width ratio of over 2, and unlike nodes that are suggestive of tumor infiltration, they tend to have intact corticohilar differentiation. Considering the risk of lymphoproliferative disease, particularly in patients with atopic dermatitis, close follow-up is recommended in the absence of an objective clinical diagnosis. Histologically, dermatopathic lymphadenopathy should be differentiated from Hodgkin lymphoma and enlarged lymph nodes associated with T-cell lymphoma.¹

Follow-up is essential. Dermatopathic lymphadenopathy is not only more common in patients with atopic dermatitis, but is also a risk factor for subsequent lymphomas.⁸

Conflicts of Interest

The authors declare that they have no conflicts of interest.

References

1. Kojima M, Nakamura S, Itoh H, Yamane Y, Shimizu K, Murayama K, et al. Clinical implication of dermatopathic lymphadenopathy among Japanese: A report of 19 cases. *Int J Surg Pathol.* 2004;12:127–32.
2. Srinivasamurthy BC, Saha K, Senapati S, Saha A. Fine needle aspiration cytology of dermatopathic lymphadenitis in an asymptomatic female: A case report. *J Cytol.* 2016;33:49–51.
3. Frederiksen H, Svaerke C, Thomsen RW, Farkas DK, Pedersen L, Weiss NS, et al. Lymph node enlargement and risk of haematological and solid cancer. *Br J Haematol.* 2013;160:599–607.
4. Lee SW1, Park MC, Kim H, Park YB, Lee SK. Dermatopathic lymphadenopathy in a patient with adult onset Still's disease. *Clin Exp Rheumatol.* 2007;25:312–4.
5. Hurwitt E. Dermatopathic lymphadenitis: Focal granulomatous lymphadenitis associated with chronic generalized skin disorder. *J Investig Dermatol.* 1942;5:197–204.
6. Monaco SE, Khalbuss WE, Pantanowitz L. Benign non-infectious causes of lymphadenopathy: A review of cytomorphology and differential diagnosis. *Diagn Cytopathol.* 2012;40:925–38.
7. Rocco N, Della Corte GA, Rispoli C, Sabatino V, Romano F, Altiero M, et al. Axillary masses in a woman with a history of breast cancer: Dermatopathic lymphadenopathy. *Int J Surg.* 2014;12:S40–3.
8. Legendre L, Barnettech T, Mazereeuw-Hautier J, Meyer N, Murrell D, Paul C. Risk of lymphoma in patients with atopic dermatitis and the role of topical treatment: A systematic review and meta-analysis. *J Am Acad Dermatol.* 2015;72:992–1002.

A. Bueno-Rodríguez,^a R. Ruiz-Villaverde,^{a,*}
M. Caba-Molina,^b J. Tercedor-Sánchez^a

^a *Unidad de Dermatología, Complejo Hospitalario de Granada, Granada, España*

^b *Unidad de Anatomía Patológica, Complejo Hospitalario de Granada, Granada, España*

* Corresponding author.

E-mail address: ismenios@hotmail.com (R. Ruiz-Villaverde).
1578-2190/

© 2017 Elsevier España, S.L.U. and AEDV. All rights reserved.

Folliculitis Decalvans Caused by Bacterial Superinfection Secondary to Erlotinib[☆]



Foliculitis decalvante por sobreinfección bacteriana secundaria a erlotinib

To the Editor:

Bacterial superinfection associated with epidermal growth factor receptor (EGFR) inhibitors is a recognizable clinical and histopathological entity that can be differentiated from the classic papulopustular rash. The different location and distribution of the lesions, together with an onset that is typically later than that of papulopustular rash, enable it to be distinguished based on clinical findings. Correct diagnosis is essential, since treatment must be selected carefully if we are to prevent severe comorbidities in cancer patients, including the potential risk of sepsis.¹

A 66-year-old woman diagnosed with metastatic pulmonary adenocarcinoma who was receiving treatment with erlotinib at an initial dose of 150 mg/d presented with grade 1 papulopustular rash that progressed to grade 2 rash during the following 3 weeks. The response to topical corticosteroids combined with doxycycline was poor. Therefore, we decided to reduce the dose of erlotinib to 100 mg/d, with good control of the papulopustular lesions. Six months later, the patient was referred to the dermatology outpatient clinic for evaluation of crusted lesions on the scalp that had first appeared 3 months previously. Physical examination revealed generalized swelling throughout the scalp over a confluent and malodorous pustular base. Given the diagnosis of bacterial superinfection associated with erlotinib, we took a sample of the exudate for culture and started doxycycline 100 mg every 12 hours. Methicillin-sensitive *Staphylococcus aureus* was isolated in culture, and treatment was adjusted according to the antibiogram. However, the patient's condition progressed over the following days, with rapid loss of tufts of hair, leaving de-epithelialized alopecic plaques with a scar-like appearance alternating with pustular areas throughout the scalp (Fig. 1). We made a diagnosis of folliculitis decalvans due to bacterial

superinfection associated with erlotinib. The patient died of acute pulmonary thromboembolism a week later.

Bacterial superinfection of papulopustular rash secondary to EGFR inhibitors is not an uncommon complication. According to a study performed in 2010 on a series of 221 patients, the complication affected 29% of those treated with these EGFR inhibitors.² As for pathophysiology, inhibition of EGFR in keratinocytes leads to epidermal thinning. Furthermore, in vitro evaluation has shown that there is a reduction in the production of antimicrobial peptides and β -defensins by keratinocytes, as well as inhibition of the activation and proliferation of T lymphocytes.^{3,4}

Braden and Anadkat⁵ correctly defined this condition in a study published in 2016 that included 157 patients treated with EGFR inhibitors who had developed classic papulopustular lesions or infections resulting from bacterial superinfection. The authors concluded that up to 23% of patients treated with these inhibitors develop symptoms compatible with bacterial superinfection, especially

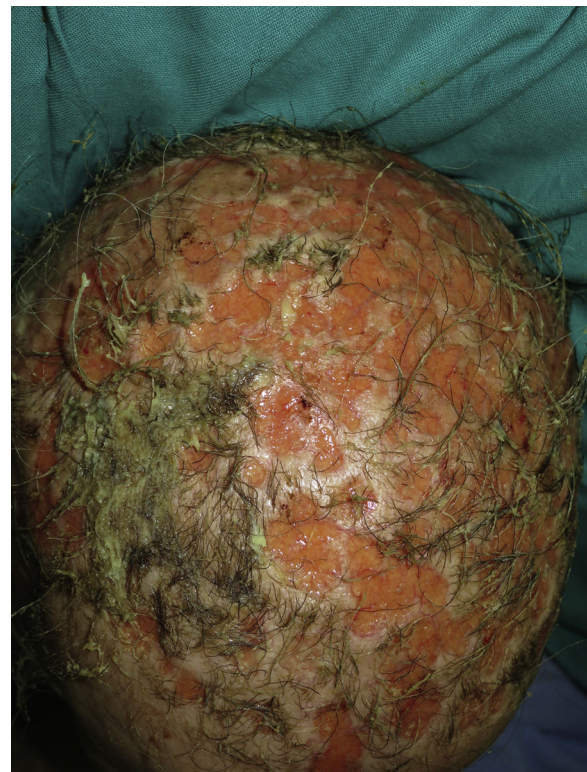


Figure 1 De-epithelialized alopecic plaques with a scar-like appearance throughout the scalp, alternating with purulent and macerated areas.

[☆] Please cite this article as: Sahuquillo-Torralla A, Escutia-Muñoz B, Rodríguez-Serna M, Botella-Estrada R. Foliculitis decalvante por sobreinfección bacteriana secundaria a erlotinib. *Actas Dermosifiligr.* 2018;109:363–364.