

Erythema Multiforme Caused by Treatment With Topical Imiquimod 5% in a Patient With Gorlin Syndrome[☆]



Eritema multiforme secundario a imiquimod tópico al 5% en paciente con síndrome de Gorlin

To the Editor:

Erythema multiforme (EM) is an acute skin disorder characterized by cutaneous lesions and variable mucosal involvement. We present a case of EM that occurred following the application of topical imiquimod to treat a basal cell carcinoma (BCC) in a woman with Gorlin syndrome.

Case Description

A 56-year-old woman with Gorlin syndrome who was seen regularly at our dermatology unit for the evaluation and treatment of BCCs developed a pruritic skin rash on her upper arm (including her palms) and ankles after applying topical imiquimod 5% cream to a BCC on the tip of her nose. In total, she had applied the cream 18 times within a once-daily Monday to Friday regimen. The patient had been taking ezetimibe 10 mg, simvastatin 20 mg, and clonazepam 0.5 mg daily for several years.

Physical examination revealed erythematous-edematous papules and plaques on the dorsum of the hands, forearms, arms, and ankles (Fig. 1) and a local inflammatory reaction in the area of the nasal dorsum where she had been applying the imiquimod cream (Fig. 2). Some of the plaques had the appearance of a target lesion but no mucosal involvement was observed.

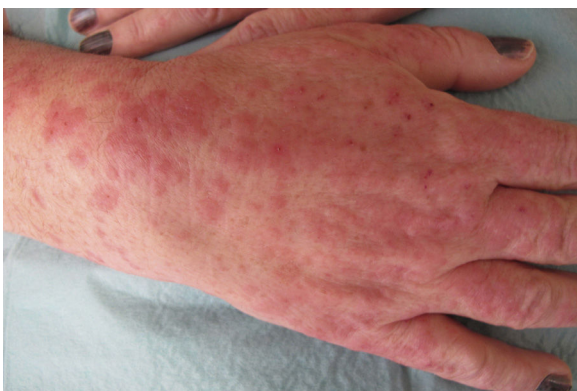

Figure 1 Erythematous-edematous lesions on the hand. Note how some of the lesions have a target appearance.

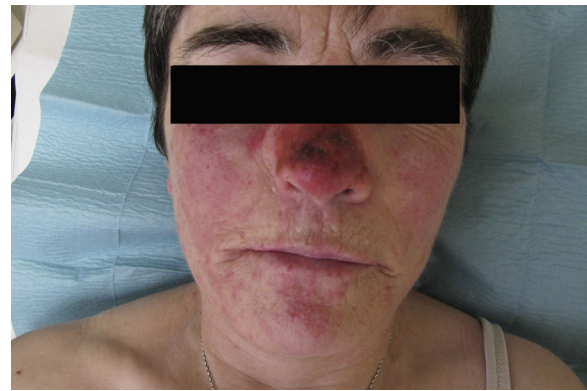

Figure 2 Erythema on the nasal pyramid (imiquimod application site) and cheeks forming confluent plaques with some necrosis in the nasal area.

Histopathologic examination of a lesion from the left elbow showed a lymphocytic inflammatory infiltrate with a predominantly perivascular distribution in the dermis, epidermal exocytosis, several areas of epithelial necrosis, and signs of incipient intraepidermal blister formation (Fig. 3), confirming the suspected diagnosis of EM. Treatment with imiquimod was interrupted and replaced with topical mometasone furoate, which resulted in complete clearance within 15 days.

Imiquimod 5% cream is a topical immunomodulator approved for the treatment of actinic keratosis, BCC, and genital warts. Its antitumor and antiviral properties are related to its ability to stimulate both innate and acquired immune responses, activating toll-like receptors 7 and 8, stimulating the secretion of proinflammatory cytokines (α -TNF, interferon alpha, interleukin 6),¹ and triggering inflammation and the destruction of tumor and virus-infected cells.

Most of the adverse effects associated with imiquimod are local, and include erythema, edema, and ulceration. Lesions occurring at a distance from the application site have also been described and include Stevens-Johnson syndrome, EM, and cutaneous lupus.

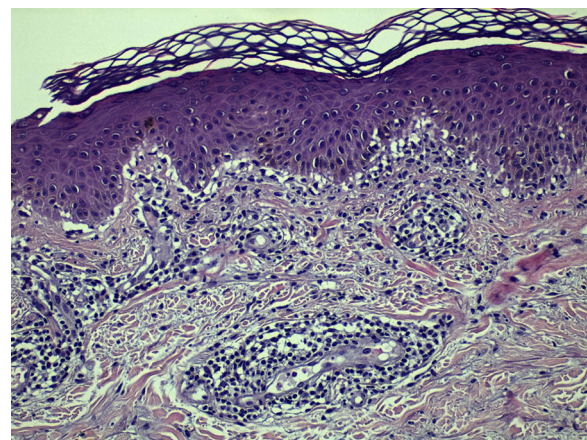


Figure 3 Perivascular lymphocytic dermal infiltrate and vacuolar degeneration of the basal layer with exocytosis (hematoxylin-eosin, original magnification x40).

[☆] Please cite this article as: Peña-López S, Suárez-Magdalena O, Monteagudo B, Cabanillas M. Eritema multiforme secundario a imiquimod tópico al 5% en paciente con síndrome de Gorlin. *Actas Dermosifiliogr.* 2018;109:277–278.

In our review of the literature, we found many drugs described in association with EM (antibiotics, corticosteroids, nonsteroidal anti-inflammatory drugs), but there were few reports linking EM to topical treatments.¹⁻³ We detected just 3 cases of EM associated with topical imiquimod, and none of the patients had Gorlin syndrome. Systemic absorption could explain why topical imiquimod causes EM, as the immunomodulatory effects of the drug could trigger a type III and/or IV hypersensitivity reaction, ultimately leading to EM. An intense local inflammatory reaction such as that experienced by our patient would probably favor this systemic absorption, predisposing patients to an EM-type skin eruption. Nonetheless, whether or not patients with Gorlin syndrome have an immune-based predisposition to EM remains to be confirmed.

Conflicts of Interest

The authors declare that they have no conflicts of interest.

References

1. García-Arpa M, Rodríguez-Vázquez M, Delgado Portela M, Vera Iglesias E. Eritema multiforme due to imiquimod 5% cream. *Actas Dermosifiliogr.* 2010;101:551-71.
2. Ballester I, Guijarro J, Niveiro M. Erythema multiforme induced by imiquimod 5% cream. *Int J Dermatol.* 2014;53:e347-66.
3. Christou E, Morrow C. Erythema multiforme to topical imiquimod 5% cream. *Australas J Dermatol.* 2012;53:32.

S. Peña-López,* O. Suárez-Magdalena, B. Monteagudo, M. Cabanillas

Servicio de Dermatología, Complejo Hospitalario Universitario de Ferrol, Ferrol, A Coruña, España

* Corresponding author.

E-mail address: Sandra.Pena.Lopez2@sergas.es (S. Peña-López).

1578-2190/

© 2017 Elsevier España, S.L.U. and AEDV. All rights reserved.

Treatment of Livedoid Vasculopathy With Rivaroxaban: A Potential Use of New Oral Anticoagulants for Dermatologists[☆]



Vasculopatía livedoide tratada con rivaroxabán. Potenciales usos de los nuevos anticoagulantes orales para el dermatólogo

To the Editor:

Livedoid vasculopathy (LV) is a noninflammatory thrombotic disease that affects the small blood vessels of the skin and

is characterized by livedo racemosa and painful skin ulcers on the lower extremities.^{1,2} We report 2 cases of LV in which treatment with rivaroxaban achieved a full and sustained response. We also review novel oral anticoagulants with potential applications in dermatology.

Case Description 1

A 53-year-old woman with no relevant past history presented with multiple skin ulcers on her feet. The ulcers were painful and had been present for 2 years. Physical examination revealed an ulcer measuring approximately 3 cm on the medial aspect of the left foot against a background of livedo racemosa and retiform purpura (Fig. 1A). The patient's

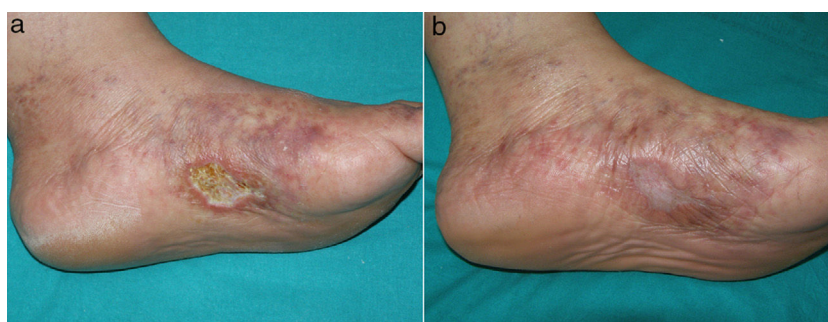

Figure 1 A, Cutaneous ulcer on the medial aspect of the left foot against a background of livedo racemosa and retiform purpura. B, Atrophic blanche due to scarring following the use of oral rivaroxaban.

[☆] Please cite this article as: Jiménez-Gallo D, Villegas-Romero I, Rodríguez-Mateos ME, Linares-Barrios M. Vasculopatía livedoide tratada con rivaroxabán. Potenciales usos de los nuevos anticoagulantes orales para el dermatólogo. *Actas Dermosifiliogr.* 2018;109:278-281.