



ACTAS Derma-Sifiliográficas

Full English text available at
www.actasdermo.org



ORIGINAL ARTICLE

Clinical and Histopathologic Findings of Cutaneous Leiomyosarcoma: Correlation With Prognosis in 12 Patients[☆]



E. Rodríguez-Lomba,^{a,*} I. Molina-López,^a V. Parra-Blanco,^b R. Suárez-Fernández,^a
A. Pulido-Pérez^a

^a Servicio de Dermatología, Hospital General Universitario Gregorio Marañón, Madrid, Spain

^b Servicio de Anatomía Patológica, Hospital General Universitario Gregorio Marañón, Madrid, Spain

Received 3 May 2017; accepted 31 August 2017

Available online 17 January 2018

KEYWORDS

Leiomyosarcoma;
Soft tissue;
Sarcoma;
Cutaneous
metastasis;
Atypical intradermal
smooth muscle
neoplasm

Abstract

Introduction: Cutaneous leiomyosarcoma is a malignant neoplasm derived from smooth muscle cells. Its low incidence hampers the development of specific protocols for diagnosis and treatment.

Objectives: To describe the clinical and histopathologic characteristics of a series of primary and secondary cutaneous leiomyosarcomas and to determine how these characteristics correlate with prognosis.

Material and methods: We performed an observational, descriptive, retrospective study based on 17 cutaneous leiomyosarcomas in 12 patients diagnosed between January 1, 2000 and December 31, 2015. We recorded demographic data, clinical and histopathologic characteristics, outcome, and response to treatment.

Results: We included 5 men and 7 women, all aged more than 50 years at diagnosis. There were 4 cutaneous leiomyosarcomas (23%) in 4 patients, 2 subcutaneous leiomyosarcomas (11.5%) in 2 patients, and 11 skin metastases of leiomyosarcoma (65%) in 6 patients. The most frequently affected sites were the scalp (41%), lower limbs (17%), and trunk (17%). During follow-up, 50% of the cutaneous leiomyosarcomas recurred, 50% of the subcutaneous leiomyosarcomas presented distant metastases, and 83% of the patients with skin metastases of leiomyosarcoma died of their disease.

Limitations: Ours was a retrospective review of a small case series at a single center.

[☆] Please cite this article as: Rodríguez-Lomba E, Molina-López I, Parra-Blanco V, Suárez-Fernández R, Pulido-Pérez A. Leiomyosarcoma cutáneo: características clínicas, histopatológicas y correlación pronóstica en 12 pacientes. Actas Dermosifiliogr. 2018;109:140–147.

* Corresponding author.

E-mail address: enriquelomba@outlook.com (E. Rodríguez-Lomba).

PALABRAS CLAVE

Leiomyosarcoma;
Partes blandas;
Sarcoma;
Metástasis cutánea;
Neoplasia atípica
intradérmica de
músculo liso

Conclusiones: Cutaneous leiomyosarcoma is an uncommon malignant neoplasm. Our approach to diagnosis and therapy must take into account the marked heterogeneity in the prognosis of the various subtypes.

© 2017 Elsevier España, S.L.U. and AEDV. All rights reserved.

Leiomyosarcoma cutáneo: características clínicas, histopatológicas y correlación pronóstica en 12 pacientes

Resumen

Introducción: El leiomyosarcoma de piel es una neoplasia maligna de estirpe muscular cuya baja incidencia dificulta el desarrollo de protocolos específicos de diagnóstico y manejo terapéutico. **Objetivos:** Describir las características clínicas e histopatológicas de una serie de leiomyosarcomas cutáneos primarios y secundarios, junto con su correlación pronóstica.

Material y métodos: Se realizó un estudio retrospectivo, descriptivo y observacional. Se seleccionaron 17 casos de leiomyosarcoma cutáneo en 12 pacientes, diagnosticados entre el 1 de enero de 2000 y el 31 de diciembre de 2015. Se recogieron sus datos demográficos, características clínicas e histopatológicas, evolución y respuesta al tratamiento.

Resultados: Se reclutaron 5 varones y 7 mujeres, todos ellos mayores de 50 años al diagnóstico. Se recogieron 4 leiomyosarcomas dérmicos (4/17, 23%) en 4 pacientes, 2 leiomyosarcomas hipodérmicos (2/17, 11,5%) en 2 pacientes, y 11 metástasis cutáneas de leiomyosarcoma (11/17, 65%) en 6 pacientes. Las localizaciones más frecuentes fueron cuero cabelludo (7/17, 41%), miembros inferiores (3/17, 17%) y tronco (3/17, 17%). Durante el seguimiento, un 50% de leiomyosarcomas dérmicos recidivaron, un 50% de leiomyosarcomas hipodérmicos presentaron metástasis a distancia y 5/6 pacientes con metástasis cutáneas de leiomyosarcoma (83%) fallecieron a causa de su enfermedad.

Limitaciones: Este estudio es una revisión retrospectiva de una serie de casos de tamaño limitado en un centro único.

Conclusiones: El leiomyosarcoma cutáneo es una neoplasia maligna poco frecuente. A la hora de adoptar una actitud diagnóstico-terapéutica en estos pacientes debemos tener en cuenta la marcada heterogeneidad pronóstica entre sus diferentes subtipos.

© 2017 Elsevier España, S.L.U. y AEDV. Todos los derechos reservados.

Introduction

Skin leiomyosarcomas are rare malignant neoplasms that derive from smooth muscle tissue. They account for around 2% to 3% of all soft-tissue sarcomas in skin and 0.04% of all neoplasms. They are currently thought to arise de novo from smooth muscle, even though there have been reports of tumors that derived from leiomyomas.¹

Leiomyosarcomas have traditionally been grouped in 3 large subtypes according to clinical and pathologic features that have prognostic implications: 1) cutaneous, or dermal forms; 2) subcutaneous, or hypodermal forms; and 3) secondary metastatic forms. The most important clinical and prognostic differences between the classes are summarized in Table 1.^{2,3}

The origin of cutaneous leiomyosarcomas seems to be the pilorector muscle in the dermis. However, there have been reports of cases in which the tumor developed in the dartos, or its equivalent muscle in the vulva, or in the areola. This form is not usually aggressive but tends to recur locally after surgical excision with narrow margins. The risk of distant metastasis is considered low (5%–10%), and these tumors have therefore been called “atypical intradermal smooth muscle neoplasms.”⁴ Subcutaneous leiomyosarcomas arise

in the smooth muscle fibers of the tunica media of arteries and veins. Unlike more superficial, or dermal forms, these leiomyosarcomas have high rates of local–regional recurrence and metastasis (30%–40%), presenting a poor prognosis. Finally, metastatic leiomyosarcoma of the skin is associated with a particularly poor prognosis. Metastasis usually derives from a primary leiomyosarcoma in the retroperitoneum, the uterus, or the subfascial soft tissue of the extremities.^{5–7} Even though the World Health Organization’s 2005 taxonomy distinguishes true cutaneous from subcutaneous forms⁸ (the latter of which are included among soft-tissue tumors⁹), this distinction can become complicated in clinical practice because of overlap of histopathologic features with prognostic implications.¹⁰ In addition, metastases of noncutaneous leiomyosarcomas to the skin simulate the features of primary subcutaneous leiomyosarcomas, a situation that makes metastasis a diagnosis of exclusion.⁶

Because prognosis is difficult in some cases of leiomyosarcoma in the skin, we analyzed features of cases diagnosed in our hospital in the past 15 years. We included all leiomyosarcomas regardless of origin of the neoplasm, that is, both primary tumors and metastatic disease.

Table 1 Characteristics of Cutaneous, Subcutaneous, and Metastatic Forms of Leiomyosarcoma.

	Cutaneous Leiomyosarcoma	Subcutaneous Leiomyosarcoma	Metastasis of Noncutaneous Leiomyosarcoma
Incidence, by sex	Men 3: women 1	Men = women	
Age at presentation	50–70 y	50–80 y	> 60 y
Origin	Piloerector muscle	Vascular tunica media	Primary tumor in extremities, retroperitoneal cavity, uterus, etc.
Size	Dartos Areola About 2–3 cm	Most often > 3 cm	Most often > 3 cm
Most common location	Lower limbs in 50%–85%	Lower limbs, in 50%–85%	Scalp (> 75%) and trunk
Recurrence	30%–40%	50%–70%	
Metastasis	5%–10%	30%–40%	
Prognosis	Good	Poor	Poor

Sources: Winchester et al,² Aneiros-Fernández et al,³ Kraft et al,⁴ and Winchester et al.⁵

Material and Methods

This retrospective, descriptive, observational study included data from adults who received a histopathologic diagnosis of leiomyosarcoma between January 1, 2000, and December 31, 2015. Cases were compiled from the skin and soft-tissue sarcoma registry of our hospital's pathology department. We included skin leiomyosarcomas whether they were primary or metastatic. We excluded subfascial and visceral tumors and cases for which the clinical history was unavailable or incomplete.

We collected the following data from the records of selected patients: age at presentation, sex, year diagnosed, clinical presentation (lesion type, number, size, and location), latency time (from diagnosis of the primary tumor until detection of metastatic disease in skin), length of follow-up, clinical course, and response to treatments (disease-free, recurrence, or death). Histologic features recorded were histologic form (cutaneous or subcutaneous primary tumor, or metastatic tumor), Ki-67 expression, mitotic index (number of mitoses per 10 high-power fields [HPF]), and positive reaction to immunohistochemical stains (including vimentin, desmin, HHF-35 [muscle-specific actin], smooth muscle actin [SMA], S100, and CD34).

Results

Clinical and histopathologic data and clinical course recorded for the included cases are shown in Table 2.

A total of 17 leiomyosarcomas in 12 patients (5 men, 41%; 7 women, 59%) were found in the registry. All patients were over 50 years of age at the time of diagnosis, and 45% were over the age of 70 years. The mean follow-up period after diagnosis of the cutaneous neoplasm (whether primary or metastatic) was 39.6 months.

There were 4 cutaneous leiomyosarcomas (23%) in 4 patients, 2 subcutaneous leiomyosarcomas (11.5%) in 2 patients, and 11 metastatic leiomyosarcomas (65%) in the remaining 6 patients. The metastatic tumors derived from primary tumors in the subfascial plane; in smooth muscle of

the uterus or bladder; or in the intra-abdominal or retroperitoneal spaces. Metastatic tumor cells were found at an average of 1.8 sites per patient during follow-up.

The most frequent location at the time of diagnosis was the scalp in both the series as a whole (7/17, 41%) and in the subgroup of metastatic leiomyosarcomas. The lower limbs (3/17, 17%) and the trunk (3/17, 17%) were the next most common sites. The mean sizes of tumors on diagnosis in all 3 categories were as follows: cutaneous leiomyosarcomas, 2.6 cm; subcutaneous leiomyosarcomas, 3.1 cm; and metastatic leiomyosarcomas, 1.8 cm.

Histology found a mean of 11 mitotic figures per 10 HPF and Ki-67 protein expression of 30% in cutaneous tumors, 7.5 mitotic figures per 10 HPF and Ki-67 expression of 60% in subcutaneous forms, and 10.2 mitotic figures per 10 HPF and Ki-67 expression of 48% in metastatic forms. Immunohistochemical staining was positive for vimentin (>25% of cases), desmin (>50%), HHF-35 (>75%), and SMA (>75%). S100 staining was focally positive in 1 cutaneous leiomyosarcoma; CD34 staining was also positive in 1 cutaneous tumor.

All the leiomyosarcomas in this series were excised surgically on diagnosis. Two of the cutaneous tumors did not recur after excision with margins greater than 1 cm. However, the remaining cutaneous tumors did recur within 2 to 3 years after excision. The recurrences were excised, followed by radiation, and no further recurrences were registered during follow-up. One patient with a subcutaneous tumor remained free of disease. The second patient with this form developed multiple node, bone and muscle metastases and at the time of writing was receiving third-line chemotherapy (trabectedin).

The first focus of metastatic leiomyosarcoma cells in the third subgroup occurred 2 to 18 months after diagnosis of the primary tumor. In 2 cases metastasis to skin preceded metastasis to other sites, whereas in 3 cases it occurred afterwards. The generalized metastasis that developed during the course of disease in the 6 patients with metastatic skin leiomyosarcoma usually involved the lung. The next most commonly involved organ was the liver (3 patients). Five of these 6 patients died within an average of 25 months

Table 2 Clinical and Histopathologic Features in 17 Cutaneous, Subcutaneous and Metastatic Leiomyosarcomas.

	Cutaneous Leiomyosarcoma (n=11)	Subcutaneous Leiomyosarcoma (n=4)	Metastatic Leiomyosarcoma (n=11)
Age, mean (range), y	62 (45–83)	70.5 (59–82)	69.1 (51–92)
Men:women	2:2	1:1	2:4
Size, mean (range), cm	2.6 (0.4–4)	3.1 (0.7–6)	1.8 (1–2.5)
Location, n (%)	4 (23.5)	2 (11.5)	11 (65)
Head and neck, n	1	1	8
Trunk, n	2	0	2
Extremities, n	1	1	1
Mitotic figures/10 HPF, mean	11	7.5	10.2
Ki-67 expression, %	30	60	48
3-y recurrence, n (%)	2/4 (50)	0/2 (0)	NA
3-y metastasis, n (%)	0/4 (0)	1/2 (50)	NA
Tumor-specific mortality, n (%)	0/4 (0)	0/2 (0)	5/6 (83)
Follow-up time, mean (range), mo	70.5 (6–120)	21 (12–30)	25.3 (5–48)

Abbreviation: HPF, high-power field; NA, not applicable.

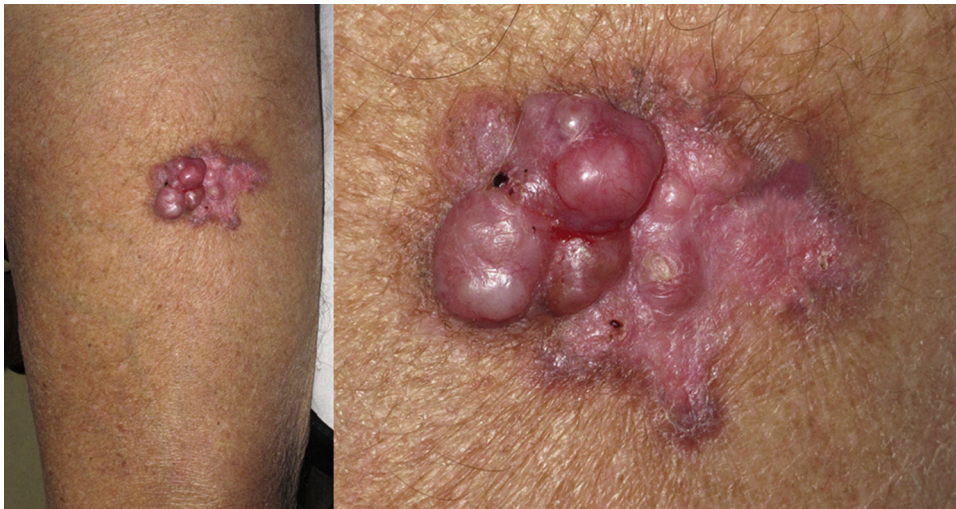

Figure 1 Reddish, infiltrated plaque measuring 6 × 3.5 cm on the front of the left thigh. Fairly solid, ulcerated nodular formations overlie the lesion. Small hemorrhagic points can be seen.

after diagnosis of their skin metastasis, in spite of chemo- and radiotherapy.

Discussion

Cutaneous soft-tissue sarcomas—and leiomyosarcomas among them—are rare tumors. Because of the low incidence of these tumors, it is difficult to develop protocols for their diagnosis and management.

Cutaneous leiomyosarcomas usually present as nodules or masses that are firm to the touch (Fig. 1) in adults over the age of 50 years. Patients often consult the physician for pain, itching, or paresthesia in the area around the lesion (Fig. 1).

Histology recognizes 2 architectural patterns. One is a nodular pattern characterized by cellularity, cell atypia, and mitotic figures. The other is a diffuse pattern with lower

cellularity and a lower mitotic index. Because cell atypia is not always evident, a histologic diagnosis should be supported by the overall architecture of the lesion (infiltrative pattern and high cellularity). It is particularly important to obtain adequate samples for histopathology, and incisional biopsies that extend below the dermis are preferred. Immunohistochemistry is an essential tool for distinguishing these neoplasms from tumors with fusiform cells and for establishing lineage¹¹ (Fig. 2).

To date most of the literature on cutaneous leiomyosarcoma in the skin consists of descriptions of single cases or small series. Prognostic factors are therefore hard to discern, as this neoplasm varies in its clinical behavior.

Winchester et al² analyzed prognostic indicators in one of the largest series of cutaneous and subcutaneous leiomyosarcomas published. They described 71 cases occurring over a period of 50 years. The most common location of both types of skin leiomyosarcoma was the extensor

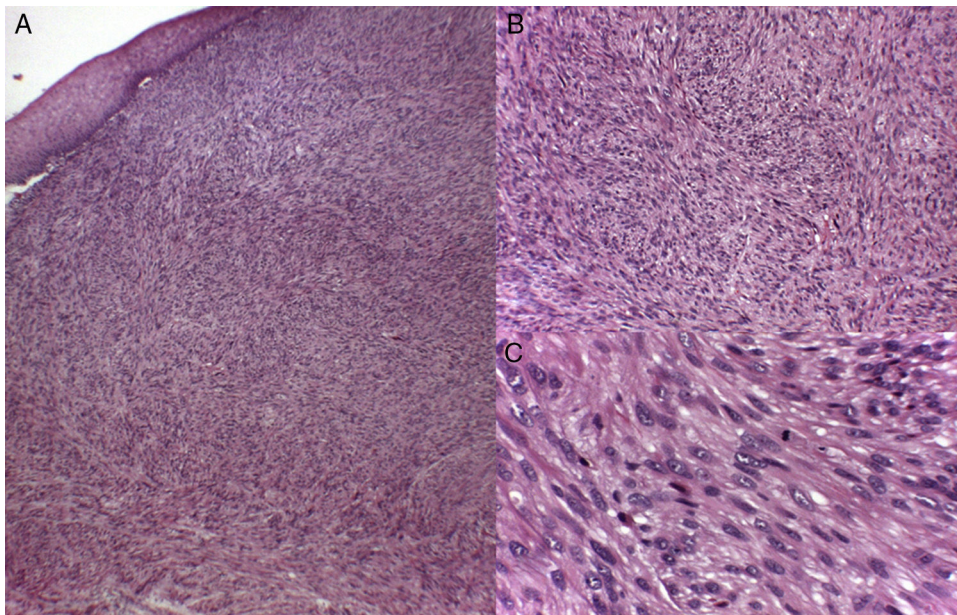


Figure 2 Diffuse, poorly defined fascicles interspersed with smooth muscle fibers composed of fusiform cells with cigar-shaped nuclei (elongated with rounded tips), marked pleomorphism, and an eosinophilic cytoplasm. Hematoxylin-eosin, magnification: A, $\times 10$; B, $\times 20$; C, $\times 40$.

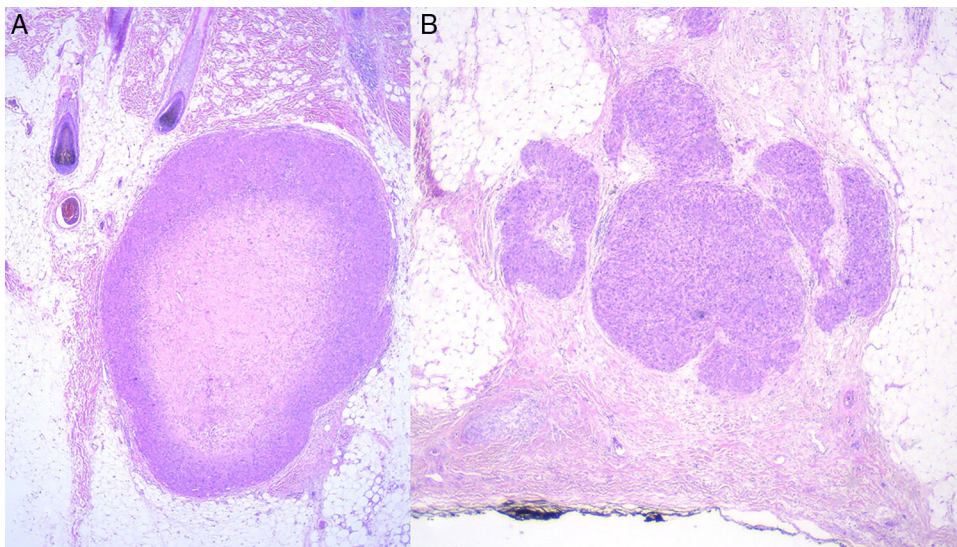


Figure 3 A, Primary subcutaneous leiomyosarcoma. B, Skin metastasis from a noncutaneous leiomyosarcoma.

surfaces of the lower limbs. The next most common was the trunk. They found significant differences in the 5-year recurrence rate between cutaneous (18%) and subcutaneous (28%) forms. The median follow-up after diagnosis was 4 years. Distant metastasis was observed for 12% percent of the cutaneous and 51% of the subcutaneous tumors. The median latency from initial diagnosis to metastasis was 3 years. They also reported specific mortality for cutaneous and subcutaneous tumors (6% and 40%, respectively). Metastasis in this retrospective cohort occurred in 10.4% of the cutaneous leiomyosarcomas, obliging the authors to question the appropriateness of the term "atypical intradermal smooth muscle neoplasms" proposed by Kraft et al.⁴ Another group,

Jensen et al,¹² also analyzed prognostic factors (among them tumor size, depth, and histologic grade) in a series of 41 cutaneous and subcutaneous leiomyosarcomas. Tumor size greater than 5 cm at diagnosis was the only independent variable to survive as a prognostic factor on multivariate analysis.

The features we report in our series are generally consistent with those earlier reports. However, the most frequent location in our patients was the head, attributable to our inclusion of metastatic leiomyosarcomas. In addition, we saw differences in the mitotic index, and the 2 recurring cutaneous leiomyosarcomas in our series had disease-free intervals of 2 and 3 years. One of our 2 patients with

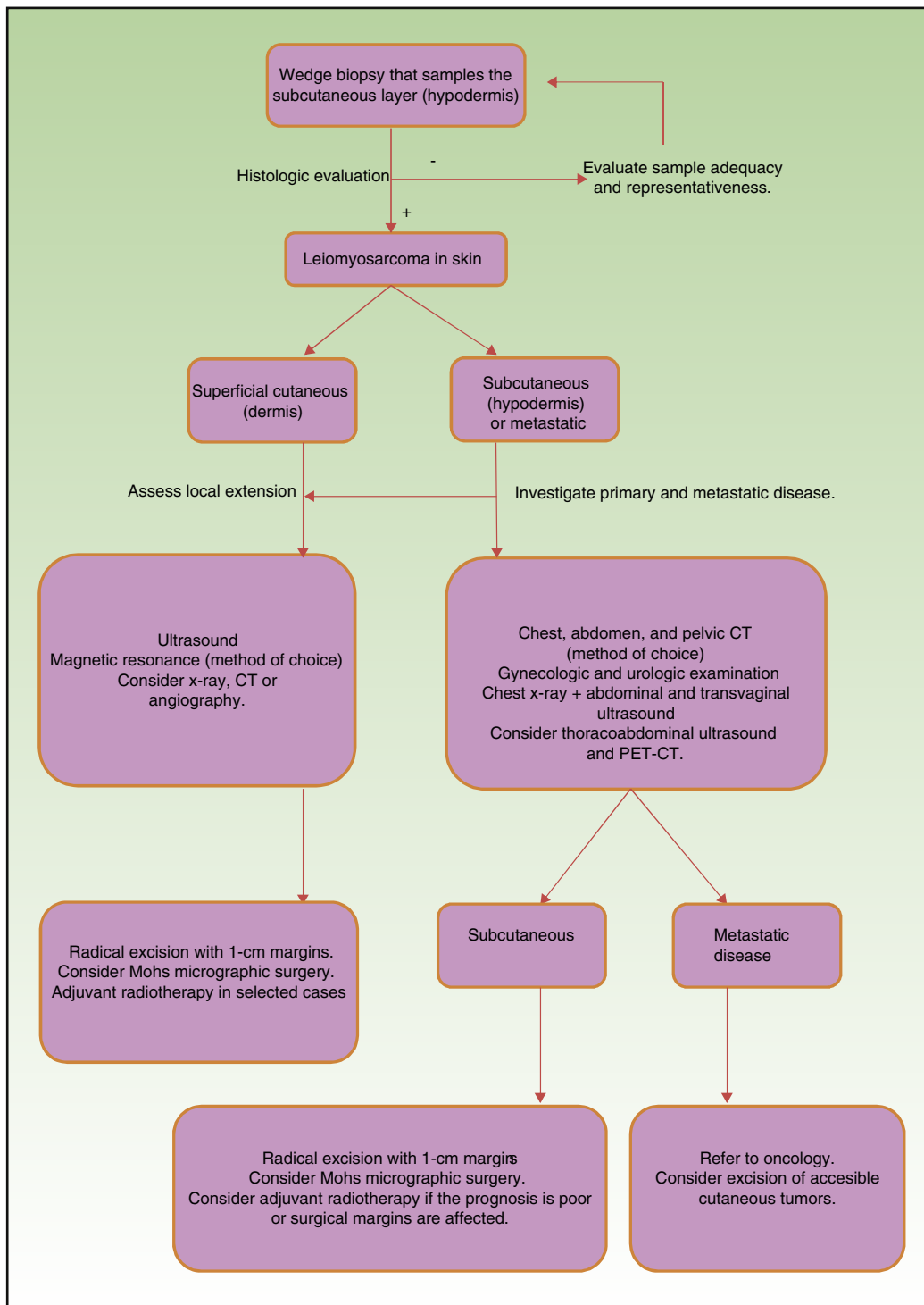


Figure 4 Algorithm to guide the diagnosis and management of leiomyosarcomas of the skin. CT refers to computed tomography; PET-CT, positron emission CT.

subcutaneous tumors remained free of disease after a year of follow-up in spite of an initial tumor size of 5 cm. The higher mean mitotic index in cutaneous versus subcutaneous and metastatic tumors in our series was an interesting finding, although it is true that we have only been able to analyze a small number of cases.

Leiomyosarcoma that metastasizes to the skin has been reported in the literature¹³⁻¹⁶ and an analysis of 21 such cases was recently published by Winchester et al.⁵ Consistent with our observations, they found that the head was the most frequent location, probably because the high degree of vascularization in the scalp facilitates spread via

the bloodstream. They also reported a mean age at diagnosis of the first metastatic tumor of 68 years, a median disease-free interval between tumor diagnosis and metastasis of 39 months, and a mean survival after the diagnosis of metastatic disease of 16 months. Our observations were similar. The mean age of our patients was 69.1 years, the median disease-free interval was 36 months after excision, and the mean survival after metastasis was 25 months—suggesting that metastasis to the skin from noncutaneous leiomyosarcomas indicates a poor prognosis.

Surgical treatment is the gold standard for localized tumors.^{17–19} However, important structural limitations make it difficult to determine the optimal size of safety margins. Aggressive surgery, with margins ranging from 3 to 5 cm are traditionally recommended, but time has shown that a more conservative approach taking margins of 1 cm can give similar results without increasing the rate of local recurrence. Mohs micrographic surgery seems to have gained special importance in this setting. During follow-up in a series of 41 leiomyosarcomas treated with Mohs surgery, only 2 cases of recurrence and no cases of metastasis were observed.^{18–21} Nevertheless, prospective studies in larger series and longer periods of follow-up are needed to confirm those findings. The role of radiotherapy in leiomyosarcoma has not been clearly defined to date, but this option can prove important when we treat deep tumors with a poor prognosis or when the margins surrounding excised tumors are not disease-free.^{17,22} Neoadjuvant, adjuvant, or palliative therapy is currently indicated for nonresectable tumors or disseminated disease, depending on tumor stage.^{17,23,24} All lesions in our series could be removed with surgical margins between 3 and 5 cm except in cases of confirmed metastasis, in which we removed tumors with 1-cm margins and prescribed chemotherapy.

Prognosis depends mainly on subtype: true cutaneous forms, cutaneous forms that penetrate subcutaneous tissue, subcutaneous forms, and metastatic forms. For this reason cutaneous leiomyosarcomas have been excluded from the World Health Organization's classification system for soft-tissue sarcomas.⁹ However, these distinctions are not present in the main diagnostic algorithms used in clinical practice (the 2016 version of the National Comprehensive Cancer Network Guidelines¹⁷), which refer to leiomyosarcomas without reference to subtypes, grouping them together with other high-grade, aggressive sarcomas. Therefore, given the lack of specific recommendations, the clinician must make individualized decisions when ordering images to evaluate tumor extension. Furthermore, even though metastatic skin involvement arising from leiomyosarcomas is even less frequent than primary leiomyosarcoma, the clinical and histopathologic differential diagnosis between these forms can be complicated (Fig. 3). The possibility of an unidentified primary visceral tumor should therefore be investigated in all cases of leiomyosarcoma confined to subcutaneous tissue. Fig. 4 shows a possible diagnostic algorithm for individualized diagnosis based on clinical and histopathologic features. The algorithm can provide guidance on choosing complementary tests and images to order early in the diagnostic process.

In conclusion, leiomyosarcoma of the skin is a rare malignancy with clearly defined prognostic differences according to histologic subtype and whether the tumor is primary or

metastatic. Even though this series analyzes few cases and data was collected retrospectively, we have been able to construct an algorithm to guide diagnosis and management that we believe will be useful to dermatologists who must treat this rare but potentially aggressive tumor.

Conflicts of Interest

The authors declare that they have no conflicts of interest.

References

- White IR, Macdonald DM. Cutaneous leiomyosarcoma with coexistent superficial angioleiomyoma. *Clin Exp Dermatol.* 1981;6:333–7.
- Winchester DS, Hocker TL, Brewer JD, Baum CL, Hochwalt PC, Arpey CJ, et al. Leiomyosarcoma of the skin: clinical, histopathologic, and prognostic factors that influence outcomes. *J Am Acad Dermatol.* 2014;71:919–25.
- Aneiros-Fernandez J, Antonio Retamero J, Husein-Elahmed H, Ovalle F, Aneiros-Cachaza J. Primary cutaneous and subcutaneous leiomyosarcomas: review of their evolution and prognostic factors. *Eur J Dermatol.* 2016;26:9–12.
- Kraft S, Fletcher CD. Atypical intradermal smooth muscle neoplasms: clinicopathologic analysis of 84 cases and a reappraisal of cutaneous leiomyosarcoma. *Am J Surg Pathol.* 2011;25:599–607.
- Winchester DS, Hocker TL, Roenigk RK. Skin metastases of leiomyosarcoma (LMS): a retrospective review of 21 cases. *J Am Acad Dermatol.* 2015;72:910–2.
- Vandergriff T, Krathen RA, Orengo L. Cutaneous metastasis of leiomyosarcoma. *Dermatol Surg.* 2007;33:634–7.
- Wang WL, Bones-Valentin RA, Prieto VG, Pollock RE, Lev DC, Lazar AJ. Sarcoma metastases to the skin: a clinicopathologic study of 65 patients. *Cancer.* 2012;118:2900–4.
- LeBoit E, Burg G, Weedon D, Sarasin A. Pathology and genetics of tumours of the skin. Lyon: IARC Press; 2005.
- Fletcher CDM, Bridge JA, Hogendoorn PCW, Mertens F. WHO Classification of Tumours of Soft Tissue and Bone. Lyon: IARC Press; 2013.
- Massi D, Franchi A, Alos L, Cook M, Di Palma S, Enguita AB, et al. Primary cutaneous leiomyosarcoma: clinicopathological analysis of 36 cases. *Histopathology.* 2010;56:251–62.
- Carvalho JC, Thomas DG, Lucas DR. Cluster analysis of immunohistochemical markers in leiomyosarcoma delineates specific anatomic and gender subgroups. *Cancer.* 2009;115:1186–95.
- Jensen ML, Jensen OM, Michalski W, Nielsen OS, Keller J. Intradermal and subcutaneous leiomyosarcoma: a clinicopathological and immunohistochemical study of 41 cases. *J Cutan Pathol.* 1996;23:454–63.
- Díaz RM, Lázaro T, Piteiro AB, Hervella M, Bergón M, Contreras F, et al. Metástasis cutáneas por leiomyosarcoma. *Actas Dermosifiliogr.* 2003;94:414–6.
- García-Arpa M, Salamanca J, Ortiz PL, Rodríguez-Peralto JL, Martín-Gallardo A, Iglesias L. Metástasis cutáneas de leiomyosarcoma de útero. *Actas Dermosifiliogr.* 2003;94:666–8.
- Tomasini D, Niccoli A, Crivelli F, Scandroglio I. Cutaneous scalp metastasis as the first indication of a clinically silent retroperitoneal leiomyosarcoma and of its further relapse as metastatic widespread disease. *Eur J Dermatol.* 2014;24:264–5.
- Alcántara-Luna S, Ferrándiz-Pulido L, Ríos-Martín JJ, Moreno-Ramírez D. Leiomyosarcoma dérmico metastásico. *Piel.* 2013;28:205–7.
- National Comprehensive Cancer Network. NCCN Clinical Practice Guidelines in Oncology (NCCN Guidelines). Soft Tissue Sarcoma. Version 2.2016 [cited 2017 Jun]. Avail-

- able from: https://www.nccn.org/professionals/physician_gls/f_guidelines.asp.
18. Bernstein SC, Roenigk RK. Leiomyosarcoma of the skin. Treatment of 34 cases. *Dermatol Surg*. 1996;22:631–5.
 19. Deneve JL, Messina JL, Bui MM, Marzban SS. Cutaneous leiomyosarcoma: treatment outcomes with a standardized margin of excision. *Cancer Control*. 2013;20:307–12.
 20. Humphries TR, Finkelstein DH, Lee JB. Superficial leiomyosarcoma treated with Mohs micrographic surgery. *Dermatol Surg*. 2004;30:108–12.
 21. Startling JJIII, Coldiron BM. Mohs micrographic surgery for the treatment of cutaneous leiomyosarcoma. *J Am Acad Dermatol*. 2011;64:1119–22.
 22. Svarvar C, Böhling T, Berlin O, Gustafson P, Folleras G, Bjerkehagen B, et al. Clinical course of nonvisceral soft tissue leiomyosarcoma in 225 patients from the Scandinavian Sarcoma Group. *Cancer*. 2007;109:282–91.
 23. Ducoulombier A, Cousin S, Kotecki N, Penel N. Gemcitabine-based chemotherapy in sarcomas: A systematic review of published trials. *Crit Rev Oncol Hematol*. 2016;98:73–80.
 24. Angarita FA, Cannel AJ, Abdul Razak AR, Dickson BC, Blackstein ME. Trabectedin for inoperable or recurrent soft tissue sarcoma in adult patients: a retrospective cohort study. *BMC Cancer*. 2016;16:30.