




ACTAS Derma-Sifiliográficas

Full English text available at
www.actasdermo.org



REVIEW

Melanoma Arising in a Melanocytic Nevus[☆]



A. Martín-Gorgojo,^{a,*} E. Nagore^b

^a Escuela de Doctorado, Universidad Católica de Valencia San Vicente Mártir, Valencia, España

^b Servicio de Dermatología, Instituto Valenciano de Oncología, Valencia, España

Received 22 February 2017; accepted 2 June 2017

Available online 1 February 2018

KEYWORDS

Melanoma;
Malignant cutaneous
melanoma;
Melanocytic nevus;
Pathology;
Molecular biology

PALABRAS CLAVE

Melanoma;
Melanoma cutáneo
maligno;
Nevus pigmentado;
Patología;
Biología molecular

Abstract The association of melanoma with a preexisting melanocytic nevus varies considerably between series, depending on whether the association is based on histological signs (4%-72%) or a clinically evident lesion (42%-85%). Histological association with a nevus correlates with favorable prognostic factors, whereas a clinical association correlates with unfavorable factors. In this review, we discuss the characteristics of nevus-associated melanoma from different perspectives: Whiteman's divergent pathway hypothesis for the development of cutaneous melanoma; and the factors involved in nevogenesis, including both the genetic and molecular factors involved in the development of the melanoma and its precursor lesions. Finally, a cumulative analysis of the 16 162 cases reported in the literature revealed that 29.8% of melanomas are histologically associated with a melanocytic nevus.

© 2017 Elsevier España, S.L.U. and AEDV. All rights reserved.

Melanoma asociado a nevo melanocítico

Resumen La asociación clínica o histológica de un melanoma con un nevo melanocítico previo varía entre las series previamente publicadas de forma prominente. Esta variación se produce tanto en función de si se tienen en cuenta los restos histológicos (4-72%) como en función de la presencia de una lesión clínicamente evidente (42-85%). La asociación histológica con un nevo se ha correlacionado con factores pronósticos favorables, mientras que la asociación clínica por el contrario lo hace con factores desfavorables. Esta revisión pretende abordar las características vinculadas con el melanoma asociado a nevo, en relación con: la teoría de las vías divergentes para el desarrollo de un melanoma cutáneo de Whiteman, los factores vinculados a nevogenia y la genética y biología molecular del melanoma y sus lesiones precursoras.

[☆] Please cite this article as: Martín-Gorgojo A, Nagore E. Melanoma asociado a nevo melanocítico. Actas Dermosifiliogr. 2018;109:123–132.

* Corresponding author.

E-mail address: alejandromartingorgojo@aedv.es (A. Martín-Gorgojo).

Adicionalmente, basado en el análisis agregado de un total de 16.162 pacientes publicados en la literatura hasta la fecha, se ha calculado la proporción total de melanomas histológicamente asociados a nevo melanocítico, cifrándose en el 29,8%.

© 2017 Elsevier España, S.L.U. y AEDV. Todos los derechos reservados.

Introduction

In 1967, Mishima¹ predicted that melanoma would ultimately be seen as 2 distinct entities he called *malignant melanocytoma*, arising from lentigo senilis, and *malignant nevocytoma*, arising from a melanocytic nevus. Since then, great strides have been made in our understanding of the molecular biology of melanocytic neoplasms. Mishima's hypothesis, which has not yet been refuted, has contributed to highlighting the importance of potential precursors of melanoma, the most notable of which are melanocytic nevi.

One theory supported by several authors is that melanocytic nevi are benign tumors that originate from the clonal expansion of a melanocyte. This transformation would occur either spontaneously or in response to external triggers (e.g., sun exposure), giving rise to a histologically symmetric, largely uniform, proliferation of cells with homogeneous mutations affecting the majority of constituent cells.² The findings of numerous studies support this clonal expansion of nevus cells³⁻⁵ (although conflicting findings have been reported)^{6,7} and have permitted the definition of melanocytic nevi as clones of melanocytes that have undergone senescence.^{5,8,9} Genetic mutations attributed a key role in melanoma development have also been found in certain nevi, indicating that these lesions may be the true precursors of melanoma, which would develop following the accumulation of additional mutations over time.¹⁰ In a series of 37 cases of melanoma with adjacent melanocytic lesions, Bastian et al.¹¹ observed a gradient in the number and type of mutations present in benign, intermediate but probably benign, intermediate but probably malignant, and malignant tumors.

The above findings suggest an evolutionary trajectory where a melanocyte would undergo clonal expansion before transitioning to a melanocytic nevus and ultimately a melanoma. This proposed melanocyte-nevus-melanoma model, however, would only be applicable to certain cases, as melanomas also occur *de novo*, i.e., in the absence of an adjacent melanocytic lesion. This evolutionary process is particularly evident in the case of 2 histologic subtypes of melanoma: lentigo maligna melanoma and acral lentiginous melanoma. Finally, nevus-associated melanoma cannot always be histologically demonstrated in patients with a clinical history suggesting a preexisting nevus.

Divergent Pathways to the Development of Melanoma

The pathogenic model that assumes that melanomas arise from a melanocytic nevus following the accumulation of genetic events would appear to be consistent with the melanocyte proliferation or cell pigment instability pathway, which is one of 2 pathways proposed by Whiteman for the development of cutaneous melanoma. This double, or

divergent, pathway was first proposed in 1998 but it has subsequently been confirmed in diverse studies (including a study by Whiteman's group¹² and a meta-analysis¹³). According to this model, there are at least 2 etiologic pathways that have a key role in the development of nonacral cutaneous melanoma (Fig. 1).

The first is the pathway of chronic sun exposure, in which the accumulation of UV radiation-induced mutations in the melanocyte would lead to the development of melanoma. It is characteristic of elderly patients with a higher constitutional sensitivity to the harmful effects of the sun (i.e., those with a low Fitzpatrick skin type) and a history of significant sun damage and nonmelanoma skin cancer. The vast majority of melanomas driven by this pathway would affect the face, neck, and lower extremities.

The second "nevogenic" or pigment cell instability pathway is characterized by a greater, genetically determined, tendency towards melanocyte proliferation. In this pathway, sun exposure in childhood, and to a lesser extent, in adulthood, would ultimately be responsible for the production of new mutations and the proliferation of genetically predisposed melanocytes to tumor cells.^{12,14} This pathway would affect younger patients with a genetic predisposition to melanocyte proliferation, i.e., patients with high nevus counts. Melanomas in such cases would generally affect areas of intermittent sun exposure.

From Melanocytic Nevus to Melanoma: Genetic and Molecular Factors

Our knowledge of genetic, epigenetic, and molecular factors involved in nevogenesis and melanoma development has advanced considerably in recent years, leading not only to a greater understanding of the biology and natural history of these lesions but also to the development of targeted therapies that have shown unprecedented success.

Melanocytic neoplasms feature genetic alterations that take the form of primary oncogenic events (typically, activation of protooncogenes in oncogenes) or secondary oncogenic events (generally, suppressed expression of genes involved in skin pigmentation or cellular senescence).² The constant interaction between aggregates of melanocytes and the epithelial microenvironment would further contribute to the development of these lesions. Factors such as inflammatory phenomena,¹⁵ hypoxia,¹⁶ and paracrine exchanges, for example, have all been implicated in melanoma progression.¹⁷ This interaction between melanocytes and the microenvironment would be additionally modified by other factors, such as UV radiation.¹⁸

Following an analysis of genetic alterations in melanoma, Curtain et al.¹⁹ claimed that the mutational profile of melanocytes may be determined by sun exposure patterns. The authors proposed classifying melanomas into 4 groups based on tumor location and increasing levels of chronic

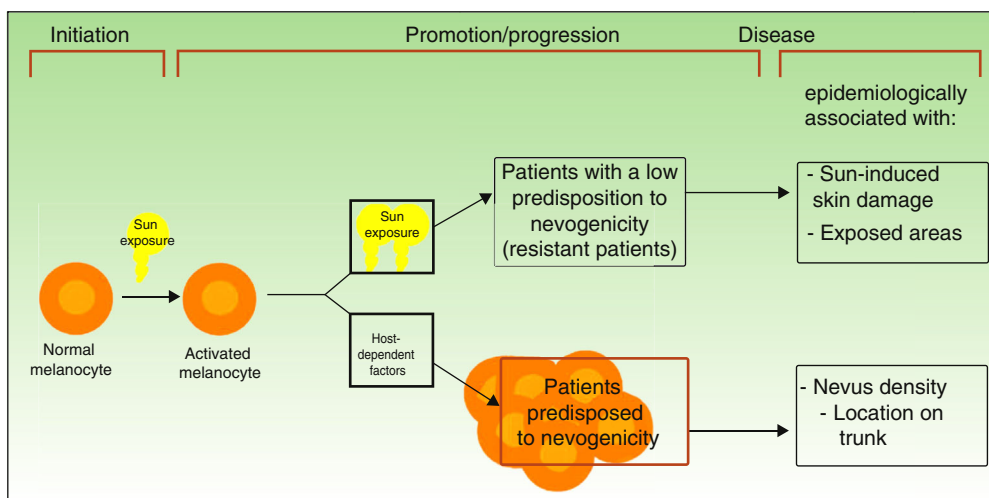


Figure 1 Pathways to melanoma development according to sun exposure and patient predisposition. Source: modified from Whiteman et al.¹²

sun-induced damage from the first to the fourth group. The criteria for the third and fourth groups also contemplated the presence of precursor or intermediate lesions. The 4 groups proposed are:

- 1) Mucosal melanomas, occurring in mucosal membranes and characterized by an absence of sun exposure.
- 2) Acral melanomas, occurring in acral locations and characterized by limited sun exposure.
- 3) Melanomas on skin without chronic sun-induced damage (absence of histologic evidence of solar elastosis), including spitzoid melanomas. Curtin et al. considered that some of the melanomas in this group might arise from benign or intermediate precursor lesions, such as acquired nevi, dysplastic nevi, Spitz nevi, and atypical Spitz tumors.
- 4) Melanomas on skin with chronic sun-induced damage (solar elastosis), including desmoplastic melanomas possibly arising in unstable solar lentigines.^{19,20}

Initiating or driver mutations have been described for all of the above melanomas. The 2 main pathways involved—the mitogen-activated protein kinase (MAPK) pathway and the phosphoinositide 3-kinase/protein kinase B/mammalian target of rapamycin (PI3K/AKT/mTOR) pathway—are shown in Figure 2.

BRAF and NRAS

The B-Raf proto-oncogene, serine/threonine kinase gene (*BRAF*) and the NRAS proto-oncogene, GTPase gene (*NRAS*) encode activator proteins at different levels of the MAPK pathway. The proteins regulate signal transduction from the surface of melanocytes for the transcription of factors that regulate cell proliferation, growth, survival, and apoptosis.^{19,23} The proportion of somatic activating *BRAF* and *NRAS* mutations reported for melanocytic lesions varies considerably from series to series.

BRAF mutations are the most common mutations associated with the pigment cell instability pathway²⁴ and have

been found in over 80% of common melanocytic nevi.^{10,25–27} They have also been identified in approximately 40% to 50% of primary melanomas and are more common in nevus-associated melanomas and superficial spreading melanomas in areas of intermittent sun exposure.^{27,28}

NRAS mutations are less common and have been observed in up to 56% of congenital melanocytic nevi²⁷ and in less than 5% of acquired nevi.^{27,29} Nevertheless, findings to date may have been confounded by the difficulty of distinguishing between acquired common nevi and small congenital nevi.³⁰ *NRAS* mutations have been observed in 20% to 30% of melanomas and are particularly common in nodular melanomas located in areas of chronic sun exposure.^{28,31}

BRAF and *NRAS* mutations may have a role in initiating the proliferation of the constituent melanocytes of pigmented lesions⁸ and in the early stages of melanoma development.¹⁰ Additional mutations, however, would be necessary to drive malignant transformation.^{10,25–27}

NF1

The neurofibromin 1 tumor suppressor gene (*NF1*) has a regulatory function in the MAPK pathway. The presence of somatic inactivating *NF1* mutations in different types of cancer generates RAS resistance through negative regulation, triggering the secondary activation of ERK. *NF1* mutations have been implicated in initiating melanoma development and are also believed to exert a negative regulatory function that results in RAF inhibitor resistance.^{32,33}

TERT

The telomerase reverse transcriptase gene (*TERT*) is essential for preventing shortening of telomeres in somatic and germinal tissues and also has a role in senescence and carcinogenesis. Telomerase expression is inhibited in most cells after birth but cancer cells display increased telomerase activity. Somatic *TERT* promoter mutations typically have the characteristic signature of UV radiation-induced mutations (generation of pyrimidine dimers).^{34,35} They have

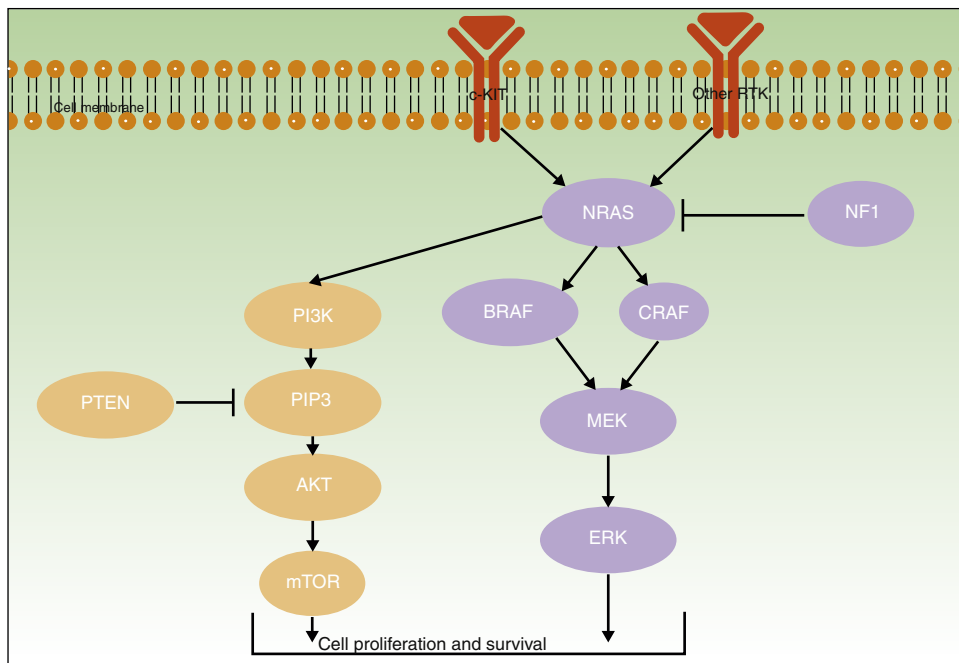


Figure 2 PI3K/AKT and RAS/MAPK pathways. RTK, receptor tyrosine-kinases. Source: adapted from Klinac et al.²¹ and Hernandez-Martin and Torrelo.²²

been identified in approximately 40% of melanomas, most of which occur in sun-exposed areas.³⁶ *TERT* mutations are associated with a worse prognosis, as they have more aggressive characteristics that determine shorter disease-free and melanoma-free survival.³⁷ They have also been linked to faster growth, particularly when accompanied by *BRAF* or *NRAS* mutations.³⁸

KIT and *PTEN*

The *KIT* proto-oncogene receptor tyrosine kinase gene (*KIT*), which has a role in the growth and proliferation of embryonic melanoblasts,³⁹ is involved in the PI3K/AKT and MAPK pathways⁴⁰ (Fig. 2). PI3K generates phosphatidylinositol-3,4,5-triphosphate, a phospholipid that activates both AKT proteins (which have a regulatory role in the cell cycle, proliferation, survival, and neoplastic transformation) and mTOR proteins (which intervene in tumorigenesis).⁴¹ Within the PI3K/AKT/mTOR pathway, special mention should be made of the phosphatase and tensin homolog tumor suppressor gene, *PTEN*, whose main function is to inhibit the activation of AKT by degrading phosphatidylinositol-3,4,5-triphosphate through its phosphatase activity.⁴²

KIT and *PTEN* mutations in the PI3K/AKT/mTOR pathway are heterogeneous, affect different genes, and may coexist with *BRAF* (17%) or *NRAS* mutations (9%).⁴³ Somatic *KIT* mutations are found in 2% of melanomas. They appear to be particularly common in acral melanomas (40% of acral lentiginous melanomas have *KIT* mutations) and mucosal melanomas (23%).⁴¹ Finally, somatic *PTEN* mutations have been detected in up to 22% of melanomas.⁴³

CDKN2A

The cyclin-dependent kinase Inhibitor 2A gene (*CDKN2A*) is located on the short arm of chromosome 9 and encodes

2 tumor suppressor proteins that have a key role in cell proliferation and senescence. The first is p14-ARF, which regulates cell proliferation through p53 stabilization, inducing the expression of the cyclin-dependent kinase inhibitor p21. The second, p16-INK4A, exerts the same role by inhibiting the association between cyclin-dependent kinases (CDK4/6) and cyclin D1 (CCND1).^{44–46} *CDKN2A* is the best-known familial melanoma locus. Germline *CDKN2A* mutations that alter the function of 1 or 2 of the proteins encoded by *CDKN2A* have been identified. In our setting, *CDKN2A* mutations are found in approximately 15% of familial melanomas.^{47,48} Somatic *CDKN2A* alterations resulting in impaired or lost function (homozygous deletions, mutations, or DNA methylation-induced epigenetic silencing) have been described in almost 90% of melanomas⁴⁹ and have been linked to invasive capacity.^{10,33} Somatic mutations are not found in common melanocytic nevi, but have been identified in 10% of dysplastic nevi.⁴⁹

One whole-exome sequencing study of dysplastic melanocytic nevi and melanoma showed that melanocytic nevi have relatively stable genomes and that progression to melanoma seems to require the presence of mutations in key tumor suppressor genes.⁵⁰ Likewise, a model for lesions at certain sites proposed the existence of a genetic-molecular continuum of melanocytic neoplasms on which benign lesions, following the accumulation of mutations in genes encoding subunits SWI/SNF and p53 (e.g., *BRAF*, *NRAS*, *TERT*, *CDKN2A*), would transition to intermediate lesions and ultimately to melanoma in situ or invasive or metastatic melanoma.¹¹

Melanocytic nevi and melanomas would therefore share genetic alterations that would accumulate along this continuum from precursor lesions (benign or intermediate malignancy) to neoplasms with metastatic potential. The main mutations currently considered to be involved in this process are summarized in Table 1.³³

Table 1 Common Genetic Mutations in Melanocytic Neoplasms and Their Role in the Transition to Melanoma.

Lesions in Which They Occur	Melanoma Subtype	Pathway	Gene	Mutation	
Nevi	Non-CSD	MAPK	<i>BRAF</i>	<i>V600E</i>	Mutations involved in initiation of tumorigenesis
Intermediate lesions and melanoma in situ	CSD		<i>BRAF</i>	<i>V600K</i> and other non- <i>V600E</i> mutations	
Intermediate lesions and melanoma in situ	CSD		<i>NRAS</i>	<i>Q61R</i> , <i>Q61K</i> , and others	
Melanomas in situ	CSD		<i>NF1</i>	Inactivating mutations and deletions	
Intermediate lesions and melanoma in situ	CSD and non-CSD	Telomerase	<i>TERT</i>	Mutations in the promotor region	Mutations involved in tumor progression
Invasive melanomas	CSD and non-CSD	Rb	<i>CDKN2A</i>	Deletions and inactivating mutations	
Invasive melanomas	CSD and non-CSD	Chromatin remodeling	<i>ARID1A</i> , <i>ARID1B</i> , and <i>ARID2</i>	Inactivating mutations and deletions	
Thicker invasive melanomas	Non-CSD	<i>PI3K</i>	<i>PTEN</i>	Inactivating mutations and deletions	Mutations involved in late progression
Thicker invasive melanomas	CSD	<i>p53</i>	<i>TP53</i>	Inactivating mutations	

Abbreviation. CSD, chronically sun-damaged (anatomic site with chronic sun damage), defined as the presence of evident histologic signs of solar elastosis as an expression of cumulative sun damage.⁵¹

Source: adapted from Shain & Bastian.³³

Nevus-Associated Melanoma

Despite the increasing recognition that the dynamic evolutionary model of melanocytic neoplasms may explain the development of some melanomas, we cannot ignore the fact that most melanomas are de novo tumors and that only a variable proportion of melanomas contain histologic remnants of a melanocytic nevus (nevus-associated melanoma).

Proportion of Nevus-Associated Melanomas

The risk of a nevus transitioning to a melanoma is generally considered to be low. The cumulative risk of transformation of any individual nevus to a melanoma over the course of 80 years has been estimated at 0.03% (1 in every 3164 nevi) in men and 0.009% (1 in every 10 800 nevi) in women.⁵²

The estimated prevalence of cutaneous melanomas clinically or histologically associated with a preexisting melanocytic nevus ranges from 4% to 85%, depending on the series. The rates are generally lower when only melanomas featuring histologic remnants of a previous nevus are taken into account (4%-72%)⁵³⁻⁸² and higher when patients report a history of a clinically evident nevus (42-85%).^{83,84} Our discussion of nevus-associated melanoma in the next section is based only on cases with objective histologic evidence of a previous nevus.

In 1988, Ackerman claimed that de novo melanomas were more common than nevus-associated melanomas. This claim was based on an analysis of over 75 000 melanomas in white patients, only 20% of which were associated with a

previous nevus.⁸⁵ The findings, however, were not applicable to black or Asian patients, most of whom had de novo tumors affecting the palms or soles or the nail apparatus.⁸⁵ A wide variety of studies conducted since then have largely shown that nevus-associated melanomas are probably more common than originally believed and do not only affect white patients.⁸⁶ The variations in estimates can be partly explained by advances in our understanding of the biology of melanocytic nevi and improvements to diagnostic criteria, particularly in the case of borderline lesions. Methodologic differences may, of course, also have led to classification biases. Given the low interobserver agreement observed for the histopathologic diagnosis of clinically suspicious pigmented lesions⁸⁷ and melanomas in situ, some dermatopathologists recommend that only invasive lesions should be considered when investigating nevus-associated melanomas.⁸⁸

A meta-analysis published in 2015 reported an estimated prevalence of 36% for nevus-associated melanoma in 10 102 patients, but this estimate fell to 32% when studies that only considered superficial spreading melanomas were excluded.⁸⁰ The meta-analysis did, however, have some limitations. It included, for example, studies that did not clearly specify the number of patients with melanoma or the proportion of patients with nevus-associated melanoma.^{85,89,90} In addition, while it logically did not take into account some of the more recent studies conducted, it also missed out on some relevant earlier publications. In an attempt to provide a more accurate estimate of the proportion of melanomas histologically associated with nevi, we conducted an exhaustive literature review that included studies

Table 2 Proportion of Melanomas Histologically Associated With a Nevus: Estimated Rates According to Published Studies.

Study	Year of Publication	No. of Patients	Nevus-Associated Melanoma (%)	Histologic Subtype ^a
Ackerman ⁵³	1948	75	4	Not specified
Couperus & Rucker ⁵⁴	1954	141	72	Not specified
Cochran ⁵⁵	1969	165	22	Not specified
Clark et al. ⁵⁶	1969	209	9.6	SSM, NM, LMM
McGovern ⁵⁷	1970	202	26.7	SSM
Rippey & Whiting ⁵⁸	1977	54	22.2	SSM, NM, and other nonspecified types
Larsen ⁵⁹	1978	60	18.3	SSM, NM, and other nonspecified types
Crucioli & Stilwell ⁶⁰	1982	129	10.9	
Rhodes et al. ⁶¹	1982	234	27.4	
Friedman et al. ⁶²	1983	557	23.3	
Sondergaard ⁶³	1983	1916	9	
Clark et al. ⁶⁴	1984	241	30.7	
Kopf et al. ⁶⁵	1987	679	31	
Black et al. ⁶⁶	1988	500	42.2	SSM
Stolz ⁶⁷	1989	150	22	
Gruber et al. ⁶⁸	1989	197	32.5	
Marks et al. ⁶⁹	1990	1101	23.3	
Urso et al. ⁷⁰	1991	233	22.7	
Sagebiel ⁷¹	1993	1954	57.6	SSM, NM
Skender-Kalnenas et al. ⁷²	1995	289	51	
Harley & Walsh ⁷³	1996	124	23	
Carli et al. ⁷⁴ and Massi et al. ⁷⁵	1999	131	20.6	
Bevona et al. ⁷⁶	2003	1606	26	
Purdue et al. ⁷⁷	2005	932	36	
Echeverría et al. ⁷⁸	2010	981	30.3	
Longo et al. ⁷⁹	2011	113	29.2	
Lin et al. ⁸⁰	2015	850	28	
Haenssle et al. ⁸¹	2016	190	54.2	
Cymerman et al. ⁸²	2016	2149	25.5	
Aggregate analysis		16 162	29.8	All subtypes

Abbreviations: LMM, lentigo maligna melanoma; NM, nodular melanoma; SSM, superficial spreading melanoma.

^a Includes all histologic subtypes of melanoma unless otherwise specified.

not analyzed in the 2015 meta-analysis. We followed a similar methodology,⁸⁰ which consisted of searching the PubMed database using the terms *melanoma*, *nevi*, *precursor*, and *pathology*. The search retrieved 169 studies published up to February 7, 2017. The abstracts of all the articles retrieved were screened. Review articles and editorials that did not present new data were excluded, but their reference lists were reviewed to identify original articles mentioning nevus-associated melanoma in the title or abstract. The estimated prevalence of nevus-associated melanoma was calculated using the data from 29 studies reporting on 16 162 patients (Table 2).

Characteristics of Nevus-Associated Melanoma

Current evidence indicates that nevus-associated melanomas, regardless of the type of benign melanocytic lesion in which they arose, share certain characteristic features (Table 3).

Melanomas containing histologic remnants of a pre-existing nevus are associated with a younger age at diagnosis,^{66,76,78,80} a high nevus count^{74,81} (or density),⁷⁷ and

a history of sunburn.⁷⁴ They are mainly located on the trunk and in areas of intermittent solar exposure^{58,68,72,74–76,78,80} (which would explain why they have fewer clinical⁷⁷ and histologic⁶⁶ signs of chronic sun damage). Nevus-associated melanomas are mostly superficial spreading melanomas^{69,71,72,76–78} and have histologic characteristics associated with a better prognosis (lower Breslow depth^{62,66,71,77,81} and absence of ulceration).^{80,82}

The above characteristics contrast with those typically observed in melanomas with clinical rather than histologic evidence of a preexisting nevus. In a study of 377 patients with melanoma, Breslow depth was greater in a subgroup of patients with a clinical history of a previous pigmented lesion (42%), although it was not associated with worse survival.⁸⁴ This link between tumor thickness and melanoma that is clinically associated with a previous nevus, however, was not corroborated by a later Spanish study that using a similar methodology analyzed 165 melanoma patients, 49% of whom reported a previous nevus.⁸³

Melanomas with histologic evidence of a preexisting nevus appear thus to have more favorable clinical and histopathologic features. Although most publications that have specifically studied nevus-associated melanomas have

Table 3 Characteristics Associated With Nevus-Associated Melanoma.

	Positive Association	Negative Association
Clinical and epidemiologic characteristics	Younger age ^{66,76,78,80} Location on trunk ^{58,68,72,74–76,78,80} History of sunburn ⁷⁴ High nevus count ^{74,81} or density ⁷⁷ Longer disease-free survival ⁶²	Older age ⁸² Greater risk of melanoma: personal or family history of dysplastic nevus syndrome, melanoma, or multiple melanoma ⁸¹ Greater (clinical) sun damage ⁷⁷ Presence of metastasis and death due to malignant melanoma ⁹¹ TNM stage > I and lower overall survival ⁸²
Histopathologic characteristics	Superficial spreading melanoma ^{69,71,72,76–78} and nodular melanoma ⁷¹ subtypes Lower Breslow depth ^{62,66,71,77,81}	Nodular melanoma ^{68,69,82,91} and lentigo malignant melanoma ^{68,72,77} subtypes Greater Clark level or Breslow depth ^{69,70} (> 1.0 mm ⁸² or > 2.25 mm ⁹¹) Presence of ulceration ^{80,82} Greater histologic evidence of sun damage ⁶⁶

not found significant differences in survival rates with respect to de novo melanomas, findings suggest that these more favorable prognostic features might be linked to longer survival. One study from 1983, for example, that analyzed 557 patients with melanoma found greater disease-free survival in a subgroup of 130 patients with nevus-associated melanoma.⁶² A later study, from 2016, of 2 cohorts of patients with melanoma from 2 different time periods (1024 and 1125 patients, of whom 198 [19.3%] and 349 [31.0%] had nevus-associated melanoma) found that patients with histologic evidence of a previous nevus had better overall survival, even after adjusting for classic prognostic factors.⁸² Finally, a recent multicenter study of 2184 patients with melanoma (that did not specifically study nevus-associated melanoma) found that patients with multiple nevi appeared to have better melanoma-specific survival.⁹²

Conclusions

Based on our pooled analysis of 16 162 patients from 29 different studies, we can conclude that close to 30% of melanomas are histologically associated with a melanocytic nevus. While nevus-associated melanomas appear to have more favorable prognostic features, most of the articles found no significant differences in survival following adjustment for the usual prognostic factors.

As discussed above, the estimated proportion of nevus-associated melanomas varies considerably from series to series, and in addition, there is low agreement between histologic and clinical diagnosis in these cases. These discrepancies could have several explanations:

- The probable existence of slow-growing melanomas with a benign clinical appearance.⁹³
- The possibility of all remnants of a nevus being completely obliterated by a growing melanoma. In line with previously suggestions,⁸⁴ we believe that this might particularly be the case with larger tumors, implying that series of thinner melanomas would have higher rates of nevus-associated melanoma.

- The consideration of atypical melanocytic proliferation at the margins of melanomas in early publications, which would explain the relative increase in the proportion of nevus-associated melanomas in more recent series.
- The possibility of missing histologic remnants of a preexisting nevus as it is not standard practise to analyze 100% of biopsy samples. Orientation of samples during processing could also lead to underdiagnosis.

Whatever the situation, current evidence suggests that patients with nevus-associated melanomas are younger and have lesions that predominantly affect the trunk, a history of sunburn, and a higher nevus count or density. It would therefore seem reasonable to recommend paying special attention to any changes in nevi in patients with multiple nevi, as is standard practice in pigmented lesion units in our setting.

Many questions remain about the biologic behavior of melanoma and its precursors and on how this influences survival. Although most studies suggest that nevus-associated melanomas are less aggressive than their de novo counterparts, it is not entirely clear whether this is due to their seemingly more favorable histologic features or to their biologic characteristics. New, more specific, studies addressing these issues are needed to guide the monitoring and treatment of patients with melanoma.

Ethical Disclosures

Protection of humans and animals. The authors declare that no tests were carried out in humans or animals for the purpose of this study.

Confidentiality of data. The authors declare that no private patient data appear in this article.

Right to privacy and informed consent. The authors declare that no private patient data appear in this article.

Conflicts of Interest

The authors declare that they have no conflicts of interest.

References

- Mishima Y. Melanocytic and nevocytic malignant melanomas. Cellular and subcellular differentiation. *Cancer*. 1967;20:632–49.
- Bastian BC. The molecular pathology of melanoma: An integrated taxonomy of melanocytic neoplasia. *Ann Rev Pathol*. 2014;9:239–71.
- Hui P, Perkins A, Glusac E. Assessment of clonality in melanocytic nevi. *J Cutan Pathol*. 2001;28:140–4.
- Indsto JO, Cachia AR, Kefford RF, Mann GJ. X inactivation DNA deletion, and microsatellite instability in common acquired melanocytic nevi. *Clin Cancer Res*. 2001;7:4054–9.
- Robinson WA, Lemon M, Elefanty A, Harrison-Smith M, Markham N, Norris D. Human acquired naevi are clonal. *Melanoma Res*. 1998;8:499–503.
- Ichii-Nakato N, Takata M, Takayanagi S, Takashima S, Lin J, Murata H, et al. High frequency of BRAF V600E mutation in acquired nevi and small congenital nevi, but low frequency of mutation in medium-sized congenital nevi. *J Invest Dermatol*. 2006;126:2111–8.
- Harada M, Suzuki M, Ikeda T, Kaneko T, Harada S, Fukayama M. Clonality in nevocellular nevus and melanoma: An expression-based clonality analysis at the x-linked genes by polymerase chain reaction. *J Invest Dermatol*. 1997;109:656–60.
- Michaloglou C, Vredeveld LC, Soengas MS, Denoyelle C, Kuilman T, van der Horst CM, et al. BRAFE600-associated senescence-like cell cycle arrest of human naevi. *Nature*. 2005;436:720–4.
- Bennett DC. Human melanocyte senescence and melanoma susceptibility genes. *Oncogene*. 2003;22:3063–9.
- Kumar R, Angelini S, Snellman E, Hemminki K. BRAF mutations are common somatic events in melanocytic nevi. *J Invest Dermatol*. 2004;122:342–8.
- Shain AH, Yeh I, Kovalyshyn I, Sriharan A, Talevich E, Gagnon A, et al. The genetic evolution of melanoma from precursor lesions. *N Engl J Med*. 2015;373:1926–36.
- Whiteman DC, Watt P, Purdie DM, Hughes MC, Hayward NK, Green AC. Melanocytic nevi, solar keratoses, and divergent pathways to cutaneous melanoma. *J Nat Cancer Inst*. 2003;95:806–12.
- Olsen CM, Zens MS, Stukel TA, Sacerdote C, Chang YM, Armstrong BK, et al. Nevus density and melanoma risk in women: A pooled analysis to test the divergent pathway hypothesis. *Int J Cancer*. 2009;124:937–44.
- Whiteman DC, Parsons PG, Green AC. P53 expression and risk factors for cutaneous melanoma: A case-control study. *Int J Cancer*. 1998;77:843–8.
- Landsberg J, Kohlmeyer J, Renn M, Bald T, Rogava M, Cron M, et al. Melanomas resist T-cell therapy through inflammation-induced reversible dedifferentiation. *Nature*. 2012;490:412–6.
- Widmer DS, Hoek KS, Cheng PF, Eichhoff OM, Biedermann T, Raaijmakers MI, et al. Hypoxia contributes to melanoma heterogeneity by triggering HIF1 α -dependent phenotype switching. *J Invest Dermatol*. 2013;133:2436–43.
- Haass NK, Ripperger D, Wladykowski E, Dawson P, Gimotty PA, Blome C, et al. Melanoma progression exhibits a significant impact on connexin expression patterns in the epidermal tumor microenvironment. *Histochem Cell Biol*. 2010;133:113–24.
- Marionnet C, Pierrard C, Golebiewski C, Bernerd F. Diversity of biological effects induced by longwave UVA rays (UVA1) in reconstructed skin. *PLoS One*. 2014;9:e105263.
- Curtin JA, Fridlyand J, Kageshita T, Patel HN, Busam KJ, Kutzner H, et al. Distinct sets of genetic alterations in melanoma. *N Engl J Med*. 2005;353:2135–47.
- Byrom L, Barksdale S, Weedon D, Muir J. Unstable solar lentigo: A defined separate entity. *Australas J Dermatol*. 2016;57:229–34.
- Klinac D, Gray ES, Millward M, Ziman M. Advances in personalized targeted treatment of metastatic melanoma and non-invasive tumor monitoring. *Front Oncol*. 2013;3:54.
- Hernandez-Martin A, Torrello A. Rasopatías: trastornos del desarrollo con predisposición al cáncer y manifestaciones cutáneas. *Actas Dermosifiliogr*. 2011;102:402–16.
- Solus JF, Kraft S. Ras, raf, and MAP kinase in melanoma. *Adv Anat Pathol*. 2013;204:217–26.
- Rivers JK. Is there more than one road to melanoma? *Lancet*. 2004;363:728–30.
- Papp T, Schipper H, Kumar K, Schiffmann D, Zimmermann R. Mutational analysis of the BRAF gene in human congenital and dysplastic melanocytic naevi. *Melanoma Res*. 2005;15:401–7.
- Pollock PM, Harper UL, Hansen KS, Yudt LM, Stark M, Robbins CM, et al. High frequency of BRAF mutations in nevi. *Nature Genet*. 2003;33:19–20.
- Poynter JN, Elder JT, Fullen DR, Nair RP, Soengas MS, Johnson TM, et al. Braf and nras mutations in melanoma and melanocytic nevi. *Melanoma Res*. 2006;16:267–73.
- Lee JH, Choi JW, Kim YS. Frequencies of BRAF and NRAS mutations are different in histological types and sites of origin of cutaneous melanoma: A meta-analysis. *Br J Dermatol*. 2011;164:776–84.
- Ross AL, Sanchez MI, Grichnik JM. Molecular neovogenesis. *Dermatol Res Pract*. 2011;2011:463184.
- Massi G, LeBoit PE. Variants of common nevus. In: Massi G, LeBoit PE, editors. *Histological diagnosis of nevi and melanoma*. Nueva York: Springer; 2014. p. 47–76.
- Goel VK, Lazar AJ, Warneke CL, Redston MS, Haluska FG. Examination of mutations in BRAF NRAS, and PTEN in primary cutaneous melanoma. *J Invest Dermatol*. 2006;126:154–60.
- Nissan MH, Pratilas CA, Jones AM, Ramirez R, Won H, Liu C, et al. Loss of NF1 in cutaneous melanoma is associated with RAS activation and MEK dependence. *Cancer Res*. 2014;74:2340–50.
- Shain AH, Bastian BC. From melanocytes to melanomas [review]. *Nat Rev Cancer*. 2016;16:345–58.
- Horn S, Figl A, Rachakonda PS, Fischer C, Sucker A, Gast A, et al. Tert promoter mutations in familial and sporadic melanoma. *Science*. 2013;339:959–61.
- Populo H, Boaventura P, Vinagre J, Batista R, Mendes A, Caldas R, et al. TERT promoter mutations in skin cancer: The effects of sun exposure and x-irradiation. *J Invest Dermatol*. 2014;134:2251–7.
- Heidenreich B, Nagore E, Rachakonda PS, Garcia-Casado Z, Requena C, Traves V, et al. Telomerase reverse transcriptase promoter mutations in primary cutaneous melanoma. *Nature Comm*. 2014;5:3401.
- Nagore E, Heidenreich B, Rachakonda S, Garcia-Casado Z, Requena C, Soriano V, et al. TERT promoter mutations in melanoma survival. *Int J Cancer*. 2016;139:75–84.
- Nagore E, Heidenreich B, Requena C, Garcia-Casado Z, Martorell-Calatayud A, Pont-Sanjuan V, et al. TERT promoter mutations associate with fast-growing melanoma. *Pigment Cell Melanoma Res*. 2016;29:236–8.
- Kunz M. Oncogenes in melanoma: An update. *Eur J Cell Biol*. 2014;93:1–10.
- Todd JR, Scurr LL, Becker TM, Kefford RF, Rizos H. The MAPK pathway functions as a redundant survival signal that reinforces the PI3K cascade in c-Kit mutant melanoma. *Oncogene*. 2014;33:236–45.

41. Merkel EA, Gerami P. Malignant melanoma of sun-protected sites: a review of clinical, histological, and molecular features. *Lab Invest.* 2017;97:630–5.
42. Wu H, Goel V, Haluska FG. PTEN signaling pathways in melanoma. *Oncogene.* 2003;22:3113–22.
43. Shull AY, Latham-Schwark A, Ramasamy P, Leskoske K, Oroian D, Birtwistle MR, et al. Novel somatic mutations to PI3K pathway genes in metastatic melanoma. *PLoS One.* 2012;7:e43369.
44. Griewank KG, Scolyer RA, Thompson JF, Flaherty KT, Schadendorf D, Murali R. Genetic alterations and personalized medicine in melanoma: Progress and future prospects. *J Nat Cancer Inst.* 2014;106:djt435.
45. Piepkorn M. Melanoma genetics: An update with focus on the CDKN2A(p16)/ARF tumor suppressors. *J Am Acad Dermatol.* 2000;42:705–22.
46. van der Rhee JI, Krijnen P, Gruis NA, de Snoo FA, Vasen HF, Putter H, et al. Clinical and histologic characteristics of malignant melanoma in families with a germline mutation in CDKN2A. *J Am Acad Dermatol.* 2011;65:281–8.
47. De Torre C, Garcia-Casado Z, Martinez-Escribano JA, Botella-Estrada R, Banuls J, Oliver V, et al. Influence of loss of function MC1R variants in genetic susceptibility of familial melanoma in Spain. *Melanoma Res.* 2010;20:342–8.
48. Puig S, Potrony M, Cuellar F, Puig-Butille JA, Carrera C, Aguilera P, et al. Characterization of individuals at high risk of developing melanoma in Latin America: Bases for genetic counseling in melanoma. *Genet Med.* 2016;18:727–36.
49. Bennett DC. Genetics of melanoma progression: The rise and fall of cell senescence. *Pigment Cell Melanoma Res.* 2016;29:122–40.
50. Melamed RD, Aydin IT, Rajan GS, Phelps R, Silvers DN, Emmett KJ, et al. Genomic characterization of dysplastic nevi unveils implications for diagnosis of melanoma. *J Invest Dermatol.* 2017;137:905–9.
51. Landi MT, Bauer J, Pfeiffer RM, Elder DE, Hulley B, Minghetti P, et al. Mc1r germline variants confer risk for BRAF-mutant melanoma. *Science.* 2006;313:521–2.
52. Tsao H, Bevona C, Goggins W, Quinn T. The transformation rate of moles (melanocytic nevi) into cutaneous melanoma: A population-based estimate. *Arch Dermatol.* 2003;139:282–8.
53. Ackerman LV. Malignant melanoma of the skin; clinical and pathologic analysis of 75 cases. *Am J Clin Pathol.* 1948;18:602–24.
54. Couperus M, Rucker RC. Histopathological diagnosis of malignant melanoma. *AMA Arch Dermatol Syphiliol.* 1954;70:199–216.
55. Cochran AJ. Histology and prognosis in malignant melanoma. *J Pathol.* 1969;97:459–68.
56. Clark WH Jr, From L, Bernardino EA, Mihm MC. The histogenesis and biologic behavior of primary human malignant melanomas of the skin. *Cancer Res.* 1969;29:705–27.
57. McGovern VJ. The classification of melanoma and its relationship with prognosis. *Pathology.* 1970;2:85–98.
58. Rippey JJ, Whiting DA. Moles and melanomas. *Lancet.* 1977;2:137.
59. Larsen TE. The classification of primary cutaneous malignant melanoma. A prospective study of 60 cases using Clark's classification. *Acta Pathol Microbiol Scand A.* 1978;86A:451–9.
60. Cruciali V, Stilwell J. The histogenesis of malignant melanoma in relation to pre-existing pigmented lesions. *J Cutan Pathol.* 1982;9:396–404.
61. Rhodes AR, Harrist TJ, Day CL, Mihm MC Jr, Fitzpatrick TB, Sober AJ. Dysplastic melanocytic nevi in histologic association with 234 primary cutaneous melanomas. *J Am Acad Dermatol.* 1983;9:563–74.
62. Friedman RJ, Rigel DS, Kopf AW, Liebllich L, Lew R, Harris MN, et al. Favorable prognosis for malignant melanomas associated with acquired melanocytic nevi. *Arch Dermatol.* 1983;119:455–62.
63. Sondergaard K. Histological type and biological behavior of primary cutaneous malignant melanoma 1. An analysis of 1,916 cases. *Virchows Arch A Pathol Anat Histopathol.* 1983;401:315–31.
64. Clark WH Jr, Elder DE, Guerry DT, Epstein MN, Greene MH, Van Horn M. A study of tumor progression: The precursor lesions of superficial spreading and nodular melanoma. *Hum Pathol.* 1984;15:1147–65.
65. Kopf AW, Welkovich B, Frankel RE, Stoppelman EJ, Bart RS, Rogers GS, et al. Thickness of malignant melanoma: Global analysis of related factors. *J Dermatol Surg Oncol.* 1987;13:401–20.
66. Black WC. Residual dysplastic and other nevi in superficial spreading melanoma. Clinical correlations and association with sun damage. *Cancer.* 1988;62:163–73.
67. Stolz W, Schmoeckel C, Landthaler M, Braun-Falco O. Association of early malignant melanoma with nevocytic nevi. *Cancer.* 1989;63:550–5.
68. Gruber SB, Barnhill RL, Stenn KS, Roush GC. Nevomelanocytic proliferations in association with cutaneous malignant melanoma: A multivariate analysis. *J Am Acad Dermatol.* 1989;21:773–80.
69. Marks R, Dorevitch AP, Mason G. Do all melanomas come from "moles"? A study of the histological association between melanocytic naevi and melanoma. *Australas J Dermatol.* 1990;31:77–80.
70. Urso C, Giannotti V, Reali UM, Giannotti B, Bondi R. Spatial association of melanocytic naevus and melanoma. *Melanoma Res.* 1991;1:245–9.
71. Sagebiel RW. Melanocytic nevi in histologic association with primary cutaneous melanoma of superficial spreading and nodular types: Effect of tumor thickness. *The J Invest Dermatol.* 1993;100:322S–5S.
72. Skender-Kalnenas TM, English DR, Heenan PJ. Benign melanocytic lesions: Risk markers or precursors of cutaneous melanoma? *J Am Acad Dermatol.* 1995;33:1000–7.
73. Harley S, Walsh N. A new look at nevus-associated melanomas. *Am J Dermatopathol.* 1996;18:137–41.
74. Carli P, Massi D, Santucci M, Biggeri A, Giannotti B. Cutaneous melanoma histologically associated with a nevus and melanoma de novo have a different profile of risk: Results from a case-control study. *J Am Acad Dermatol.* 1999;40:549–57.
75. Massi D, Carli P, Franchi A, Santucci M. Naevus-associated melanomas: Cause or chance? *Melanoma Res.* 1999;9:85–91.
76. Bevona C, Goggins W, Quinn T, Fullerton J, Tsao H. Cutaneous melanomas associated with nevi. *Arch Dermatol.* 2003;139:1620–4.
77. Purdue MP, From L, Armstrong BK, Kricker A, Gallagher RP, McLaughlin JR, et al. Etiologic and other factors predicting nevus-associated cutaneous malignant melanoma. *Cancer Epidemiol Biomarkers Prev.* 2005;14:2015–22.
78. Echeverría B, Botella-Estrada R, Serra-Guillen C, Martorell A, Traves V, Requena C, et al. Riesgo aumentado del desarrollo de un segundo melanoma cutáneo primario sobre un nevo en pacientes diagnosticados previamente de melanoma cutáneo primario sobre nevo. *Actas Dermosifiliogr.* 2010;101:710–6.
79. Longo C, Rito C, Beretti F, Cesinaro AM, Pineiro-Maceira J, Seidenari S, et al. De novo melanoma and melanoma arising from pre-existing nevus: In vivo morphologic differences as evaluated by confocal microscopy. *J Am Acad Dermatol.* 2011;65:604–14.
80. Lin WM, Luo S, Muzikansky A, Lobo AZ, Tanabe KK, Sober AJ, et al. Outcome of patients with de novo versus nevus-associated melanoma. *J Am Acad Dermatol.* 2015;72:54–8.
81. Haenssle HA, Mograby N, Ngassa A, Buhl T, Emmert S, Schon MP, et al. Association of patient risk factors and frequency of nevus-associated cutaneous melanomas. *JAMA Dermatol.* 2016;152:291–8.

82. Cymerman RM, Shao Y, Wang K, Zhang Y, Murzaku EC, Penn LA, et al. De novo vs nevus-associated melanomas: Differences in associations with prognostic indicators and survival. *J Nat Cancer Inst.* 2016;108.
83. Garcia-Cruz A, Florez A, de la Torre-Fraga C, Cruces Prado M. Observational cross-sectional study comparing Breslow thickness of melanoma arising from naevi and melanoma de novo. *Br J Dermatol.* 2009;161:700–2.
84. Weatherhead SC, Haniffa M, Lawrence CM. Melanomas arising from naevi and de novo melanomas—does origin matter? *Br J Dermatol.* 2007;156:72–6.
85. Ackerman AB. What naevus is dysplastic a syndrome and the commonest precursor of malignant melanoma? A riddle and an answer. *Histopathol.* 1988;13:241–56.
86. Togawa Y, Nakamura Y, Kamada N, Kambe N, Takahashi Y, Matsue H. Melanoma in association with acquired melanocytic nevus in japan: A review of cases in the literature. *Int J Dermatol.* 2010;49:1362–7.
87. Brochez L, Verhaeghe E, Grosshans E, Haneke E, Pierard G, Ruitter D, et al. Inter-observer variation in the histopathological diagnosis of clinically suspicious pigmented skin lesions. *J Pathol.* 2002;196:459–66.
88. Massi G, LeBoit PE. Melanoma arising in a pre-existent nevus. In: Massi G, LeBoit PE, editors. *Histological diagnosis of nevi and melanoma.* Nueva York: Springer; 2014. p. 619–32.
89. Masri GD, Clark WH Jr, Guerry DT, Halpern A, Thompson CJ, Elder DE. Screening and surveillance of patients at high risk for malignant melanoma result in detection of earlier disease. *J Am Acad Dermatol.* 1990;22:1042–8.
90. Rigel DS, Rivers JK, Kopf AW, Friedman RJ, Vinokur AF, Heilman ER, et al. Dysplastic nevi. Markers for increased risk for melanoma. *Cancer.* 1989;63:386–9.
91. Rhodes AR, Sober AJ, Day CL, Melski JW, Harrist TJ, Mihm MC Jr, et al. The malignant potential of small congenital nevocellular nevi. An estimate of association based on a histologic study of 234 primary cutaneous melanomas. *J Am Acad Dermatol.* 1982;6:230–41.
92. Ribero S, Davies JR, Requena C, Carrera C, Glass D, Rull R, et al. High nevus counts confer a favorable prognosis in melanoma patients. *Int J Cancer.* 2015;137:1691–8.
93. Argenziano G, Kittler H, Ferrara G, Rubegni P, Malvehy J, Puig S, et al. Slow-growing melanoma: A dermoscopy follow-up study. *Br J Dermatol.* 2010;162:267–73.