

## First Sonographic Description of Idiopathic Cutaneous Angiosarcoma of the Head and Neck<sup>☆</sup>



### Primera Descripción Ecográfica del Angiosarcoma Cutáneo Idiopático de Cabeza y Cuello

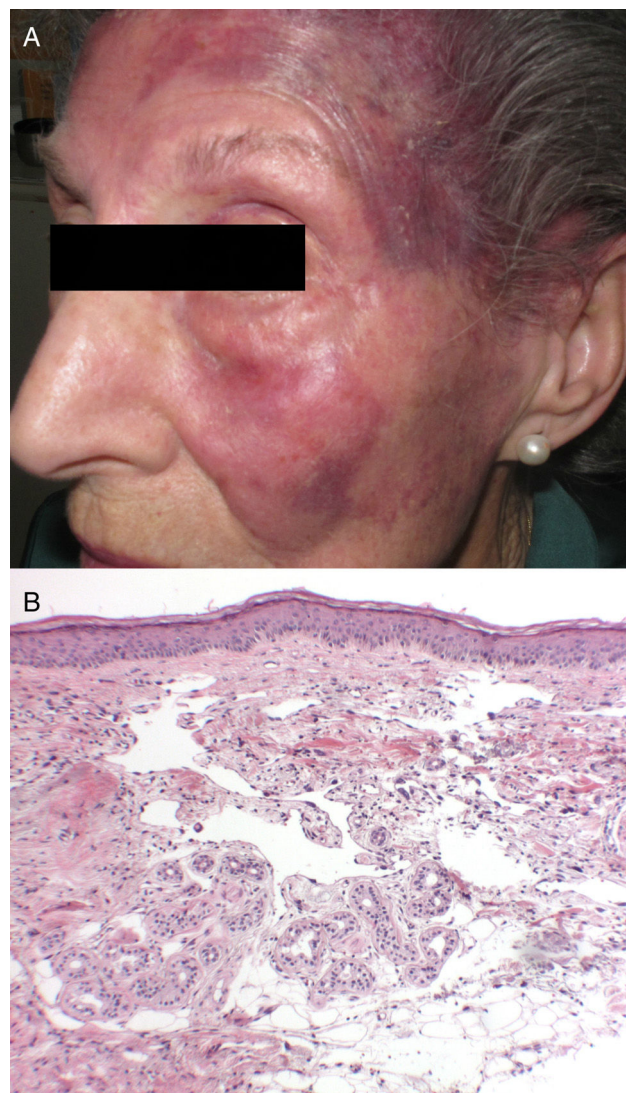
To the Editor:

An 89-year-old woman, with a past history of systemic hypertension, aortic stenosis, and iron deficiency anemia and on treatment with hydrochlorothiazide, lisinopril, and acetylsalicylic acid, was seen for an asymptomatic lesion that had arisen a month earlier in her left frontoparietal region. She had been treated with topical corticosteroids, which were prescribed for suspected contact eczema to hair dye. Physical examination revealed an erythematous-violaceous plaque that extended down to her cheek. The surface of the lesion presented a small nodule of vascular appearance (Fig. 1, A and B).

B-mode ultrasound (18 MHz probe, eSaote, MyLab25Gold) showed a predominantly hypoechoic nodule of 3.7 mm × 16.5 mm with well-defined borders, situated in the deep dermis and subcutaneous cellular tissue (Fig. 2A). The periphery of the lesion presented mixed echogenicity, in contrast to the more hypoechoic central area. In the deep region of the lesions was a hyperechoic area that may have been posterior enhancement. The epidermis appeared as a hyperechoic band. The lesion extended diffusely peripherally, and it was more difficult to identify its borders in this plane (Fig. 2, B and C). At the lateral borders of the lesion and in the non-nodular part of the tumor, areas of mixed echogenicity predominated over the hypoechoic areas. Color Doppler showed an irregular asymmetric neovascularization at the periphery of the lesion (Fig. 2, B and C).

Histology performed on an ultrasound-guided punch biopsy revealed a poorly defined neoplastic proliferation in the dermis, forming of anastomosing vascular spaces growing between the collagen bundles and skin appendages; the spaces were lined by endothelial cells with nuclear hyperchromatism and nucleomegaly, with frequent pleomorphic nuclei (Fig. 1B). Stain for human herpesvirus 8 was negative. Based on the clinical, ultrasound, and histopathological findings, we made a diagnosis of idiopathic angiosarcoma of the head and neck.

Idiopathic angiosarcoma of the head and neck is a rare neoplasm first described by Caro and Stubenrauch in 1945. It is formed of proliferations of cells with endothelial differentiation. The lesions initially appear as erythematous plaques that rapidly progress to violaceous nodules that bleed easily. This type of angiosarcoma grows centrifugally, and can

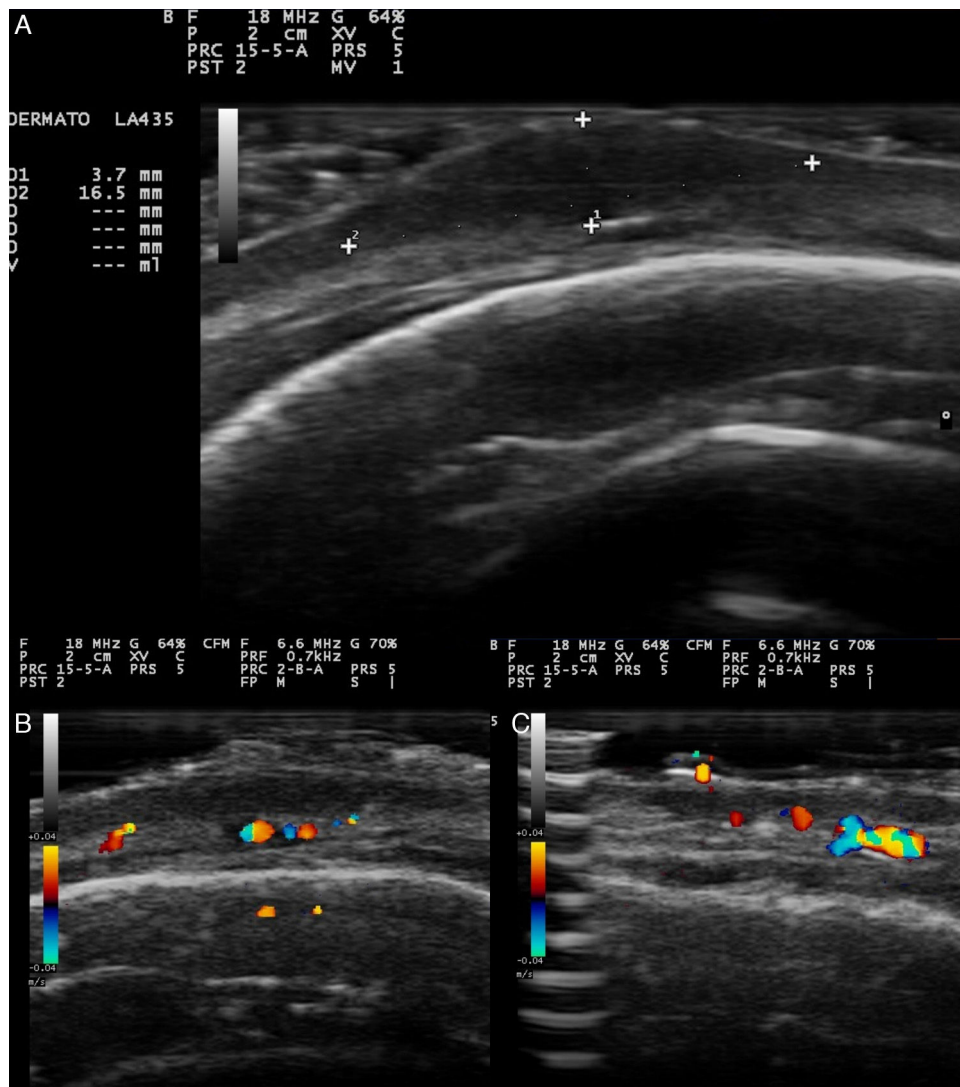


**Figure 1** A, Erythematous-violaceous plaque with well-defined borders in the frontotemporal region. B, Proliferation of neoplastic endothelial cells with nuclear hyperchromatism and nucleomegaly, forming vascular spaces that dissect between the collagen bundles in the dermis. Hematoxylin and eosin, original magnification, x10.

occupy large areas of the face and neck.<sup>1</sup> The clinical differential diagnosis should include entities such as rosacea,<sup>2,3</sup> lymphoma, skin metastases, pyogenic granuloma, and Kaposi sarcoma. The prognosis is poor, with a 5-year survival of less than 15%.<sup>4,5</sup> Surgical excision, when possible, is the treatment of choice. Chemotherapy with taxanes and palliative radiotherapy are second line treatment.<sup>6</sup> Because of our patient's advanced age and the size of the lesion, it was decided to start treatment with weekly paclitaxel at a dose of 60 mg/m<sup>2</sup>, with a poor response.

Cutaneous angiosarcoma presents histologically as a poorly defined dermal tumor with vascular tracts that infiltrate the dermis and subcutaneous cellular tissue. The endothelium can be several layers thick and contain mitotic cells. The tumor usually dissects between the collagen fibers. Ultrasound reveals hypoechoic nodules

<sup>☆</sup> Please cite this article as: Boas PV, Martínez AR, Rodríguez OB, Blanco CC. Primera descripción ecográfica del angiosarcoma cutáneo idiopático de cabeza y cuello. *Actas Dermosifiliogr.* 2017;108:960-962.



**Figure 2** A, Hypoechoic nodule with well-defined borders that are slightly more echogenic than the center of the nodule. B, Color Doppler showed increased vascularity and asymmetrically distributed medium-sized vessels in the base of the nodule. C, Increased vascularity in the non-nodular area of the lesion.

with a mixed peripheral echogenicity. The lower echogenicity of the center of the nodules may correlate with greater tumor mass and cellularity in this central region, characteristic of neof ormation. The mixed peripheral echogenicity may indicate reduced cellularity in this peripheral area and dissection of the collagen bundles by tumor cells.

Ultrasound enables us to clarify the differential diagnosis with certain other conditions, such as dermatofibrosarcoma protuberans, which is characterized by lesions with distinct echogenicity and a lobulated appearance with pseudopodia, and a weak Doppler signal peripherally.<sup>7</sup> Kaposi sarcoma is seen as a hypoechoic lesion with an increased Doppler signal within the lesion, in contrast to angiosarcoma, in which the Doppler signal is increased peripherally.<sup>7,8</sup> Pyogenic granuloma presents as a well-defined, oval hypoechoic lesion in the dermis and subcutaneous cellular

tissue, with low-flow central and peripheral vascularity on Doppler study.<sup>7</sup> Lymphangiomas are poorly vascular lesions, and this is evident on ultrasound.<sup>8</sup> Angiosarcoma of the breast has been reported to present hypoechoic images in the dermis and in the subcutaneous cellular tissue, with a contour showing lobules and spicules<sup>8</sup> (Table 1).

In the literature reviewed, we found no reports that describe the ultrasound characteristics of idiopathic angiosarcoma of the head and neck; the only available descriptions are of angiosarcoma of the breast.<sup>8</sup> In this first description of the ultrasound findings in cutaneous angiosarcoma of the head and neck, ultrasound made guided skin biopsy possible, improving the yield and avoiding the possible complications of blind biopsy. When surgical excision is a therapeutic option, ultrasound could be an interesting tool to help define the borders of the lesion.

**Table 1** Ultrasound Characteristics of the Main Conditions to be Included in the Differential Diagnosis.

	B Mode		Doppler	
	Appearance	Echogenicity		Site
DFSP	Lobules and pseudopodia	Hypoechoic or mixed	+	Periphery
KS	Lobulated	Hypoechoic	+	Center of the lesion
AS	Round nodule	Hypoechoic centrally, mixed peripherally	+	Periphery
PG	Round nodule	Hypoechoic	+	Center and periphery
LA	Nodule	Mixed with hypoechoic areas	-	-

Abbreviations: AS, angiosarcoma; DFSP, dermatofibrosarcoma protuberans; KS, Kaposi sarcoma; LA, lymphangioma; PG, pyogenic granuloma.

## Conflicts of Interest

The authors declare that they have no conflicts of interest.

## References

1. Mark RJ, Poen JC, Tran LM, Fu YS, Juillard GF. Angiosarcoma. A report of 67 patients and a review of the literature. *Cancer*. 1996;77:2400–6.
2. Mentzel T, Kutzner H, Wollina U. Cutaneous angiosarcoma of the face: clinicopathologic and immunohistochemical study of a case resembling rosacea clinically. *J Am Acad Dermatol*. 1998;38:837–40.
3. Choi WT, Stetsenko GY, Zhang J, Olerud JE, Argenyi ZB, George E. Cutaneous angiosarcoma clinically presenting as progressive solid facial edema in a 43-year-old male. *Dermatol Online J*. 2013;19:14.
4. Dettenborn T, Wermker K, Schulze H-J, Klein M, Schwipper V, Hallermann C. Prognostic features in angiosarcoma of the head and neck: A retrospective monocenter study. *J Craniomaxillofac Surg*. 2014;42:1623–8.
5. Shin JY, Roh S-G, Lee N-H, Yang K-M. Predisposing factors for poor prognosis of angiosarcoma of the scalp and face: Systematic review and meta-analysis. *Head Neck*. 2016;39:380–6.
6. Abraham JA, Hornicek FJ, Kaufman AM, Harmon DC, Springfield DS, Raskin KA, et al. Treatment and outcome of 82 patients with angiosarcoma. *Ann Surg Oncol*. 2007;14:1953–67.
7. De Troya Martín M, Alfageme Roldán F. Ecografía dermatológica: una nueva aproximación al conocimiento de la piel. *Actas Dermosifiliogr*. 2015;106:1–106.
8. Alfageme Roldán F, Salgüero Fernández I, Zamanta Muñoz Garza F, Roustán Gullón G. Actualización en ecografía de las anomalías vasculares. *Actas Dermosifiliogr*. 2016;107:284–93.

Pedro Vilas Boas,\* Antonio Ruedas-Martínez, Ofelia Baniandrés-Rodríguez, Cristina Ciudad-Blanco

*Servicio de Dermatología, Hospital General Universitario Gregorio Marañón, Madrid, Spain*

\* Corresponding author.

*E-mail address:* [Pedro.22.pvb@gmail.com](mailto:Pedro.22.pvb@gmail.com) (P. Vilas Boas). 1578-2190/

© 2017 Elsevier España, S.L.U. and AEDV. All rights reserved.

## Usefulness of Ultrasound in the Diagnosis and Follow-up of Pyoderma Gangrenosum<sup>☆</sup>



### Utilidad de la ecografía en el diagnóstico y seguimiento del pioderma gangrenoso

*To the Editor:*

A 78-year-old woman, with a past history of systemic hypertension and a chronic myeloproliferative syndrome, came to the dermatology emergency room for the presence of 2 painful, erythematous-purpuric lesions that had arisen on her left lower limb a week earlier. She stated that the lesions were increasing in size and that the pain now

interfered with walking. She did not report fever or other associated symptoms. Dermatologic examination revealed 2 poorly defined, tender erythematous-violaceous nodules on her left leg (Fig. 1A).

Additional tests included skin ultrasound with a linear 18MHz probe (Esaote MylabGold 25), which revealed a well-defined, hypoechoic subepidermal structure measuring 3.29 × 1.14 cm. This area was continuous with an irregular, heterogeneous hypoechoic area that formed tracts that extended into a destructured hypodermis. Color Doppler showed increased local vascularity. Other additional tests included a complete blood count, which showed no evidence of infection, cultures, which were negative, and a skin biopsy from one of the lesions, which revealed an abundant neutrophilic inflammatory infiltrate in the dermis and that extended into the subcutaneous cellular tissue, as well as foci of abscess formation in the dermis, dissecting through the tissue (Fig. 3). Based on these findings, we made a diagnosis of chronic myeloproliferative syndrome-associated pyoderma gangrenosum (PG) and started treatment with oral prednisone at a dose of 1 mg/kg/d.

The patient's clinical follow-up (Fig. 1, B and C) included serial ultrasound studies. After a week of treatment,

<sup>☆</sup> Please cite this article as: Pousa-Martínez M, Sánchez-Aguilar D, Aliste C, Vázquez-Veiga H. Utilidad de la ecografía en el diagnóstico y seguimiento del pioderma gangrenoso. *Actas Dermosifiliogr*. 2017;108:962–964.