

E. Errichetti,^{a,*} S. Pizzolitto,^b G. Stinco^a

^a Department of Experimental and Clinical Medicine, Institute of Dermatology, University of Udine, Italy

^b Department of Pathology, Santa Maria della Misericordia Hospital, Udine, Italy

*Corresponding author.

E-mail address: enzoerri@yahoo.it (E. Errichetti).

<http://dx.doi.org/10.1016/j.adengl.2017.04.010>
1578-2190/

© 2017 Elsevier España, S.L.U. and AEDV. All rights reserved.

Hyperkeratotic lesions on legs



Lesiones hiperqueratósicas en piernas

Dear Editor,

Skin hyperkeratosis is a common pathology in dermatological consultation. From localized pathology, such as corns or common warts, to diseases with a more diffuse effect such as psoriasis and ichthyosis, diagnosis is usually easy, in response to the history and location of lesions. But sometimes histological or analytical study is essential.

We report a 71-year-old male with multimorbidity (hypertension, diabetes mellitus, ischemic heart disease, mitral regurgitation, left bundle branch block, hepatic steatosis, fibrosing alveolitis, COPD, hypercholesterolemia, hyperuricemia and glaucoma) who presented hyperkeratotic lesions on the legs (Fig. 1). The patient had worked ten years

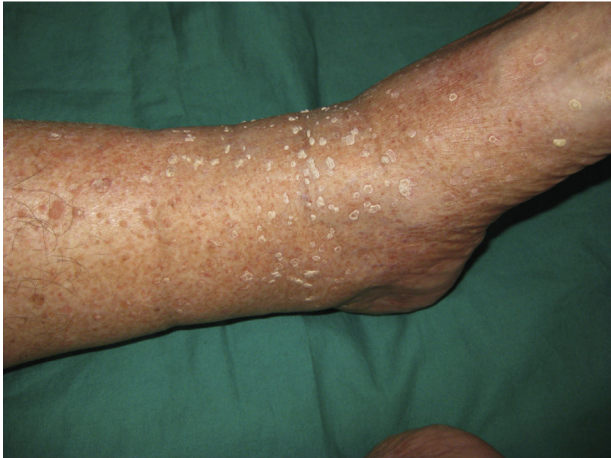

Figure 1 Hyperkeratotic lesion on the legs.

in a photographic laboratory and twenty as carpenter. The lesions were asymptomatic and he had them for more than twenty years. They were located only on the front side of the legs and other skin was respected. Lesions were 2–6 mm in diameter and were very adherent. Some had peripheral reinforcement. The patient showed no other symptoms and denied use of cosmetics or chemicals in the area. He had not suffered weight loss or anorexia. He had no history of contact dermatitis, burns or trauma. There was low actinic exposure in the area. No family member had similar injuries.

The patient had a history of working in a carpentry workshop for more than twenty years.

With suspicion of perforating skin disease, actinic keratosis, or porokeratosis, we carried out a 4 mm punch of one of the lesions. Histology showed orthokeratotic papillomatosis with focal lymphoid infiltrate in papillary dermis. The sample showed no atypia. The pathology guided us to keratotic lesions with a 'church spire' pattern (Fig. 2). This pattern

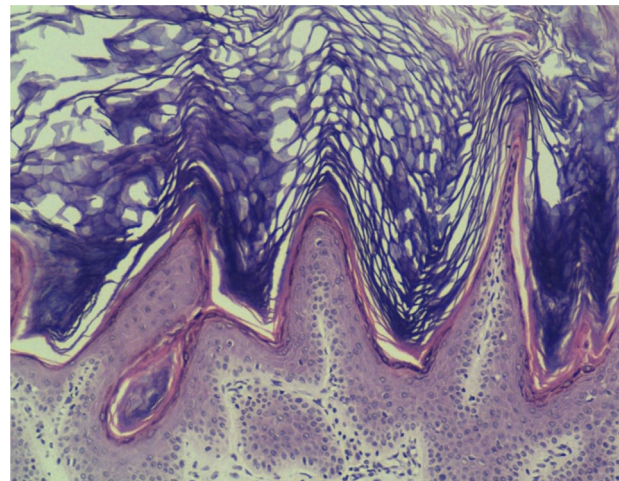


Figure 2 Hematoxylin-eosin (×100). Orthokeratotic papillomatosis with focal lymphoid infiltrate in papillary dermis and church spire pattern.

suggests multiple diagnostic possibilities: arsenic poisoning or tars, nutritional deficits (phrynoderma), digitata keratosis, Hopf verruciformis acrokeratosis, or stucco keratosis. Chest radiography was normal but analytical research showed urinary arsenic levels of 317 µg/g creatinine (normal levels in occupationally exposed people <100 µg/g creatinine). The patient was diagnosed with chronic arsenic poisoning.

Arsenic poisoning has, as its main cause, ingestion of contaminated water.¹ This is a significant public health problem in areas of South and Southeast Asia (India, China, Taiwan, Philippines, Thailand, Bangladesh) and the Americas (Argentina, Chile, Mexico, and the USA) where arsenical products are detected either naturally or occasionally by industrial waste. As a second etiologic factor there is workplace exposure. Health damage results from inorganic arsenic (the toxic form) in pesticides, herbicides, mining and galvanized microchips. Occasionally wood preservatives contain arsenic derivatives.² This could explain our case.

Our patient had long worked with wood in a carpentry workshop that, he admitted, was not ventilated. As a final cause we have to consider poisoning or drugs (in traditional Chinese medicine,³ certain antileukemia drugs,⁴ and, until 1960, Fowler's solution as an antiasthmatic).

Chronic arsenic poisoning has a latency period of years⁵ before showing clinical signs, but when it does, it may affect multiple systems: cardiovascular (increased QT, T-wave alteration, ST segment alteration), renal and hepatic dysfunction, peripheral neuropathy, blindness, alterations of blood count, electrolytes and acid-base balance, and neoplasms of the lung, bladder, and kidney.^{6,7} In skin it usually manifests as dotted, symmetrical palmoplantar keratotic lesions of 2–10mm, which may coalesce into plaques. Outside the palms and soles it is characteristic to find mottled pigmentation with hypopigmented areas. It should be noted that there is also increased risk of non-melanoma skin cancer, especially Bowen's disease, in these patients.

Arsenical dermatosis usually shows a pathology with marked hyperkeratosis, scattered parakeratosis, and mild keratinocyte atypia. Adnexal structures are spared while vacuolation of keratinocytes may be noted.

Chelators (dimercaprol and dimercaptosuccinic acid) are used mainly in the treatment of acute poisoning⁸ but these treatments have proven ineffective in chronic forms.^{9,10} The use of retinoids has been suggested to prevent the formation of epidermoid carcinomas and Bowen's disease in patients with multiple keratoses. But in chronic forms, the most important action is to avoid toxic exposure, ensuring arsenic-free sources of water and limiting occupational exposure.

Hyperkeratotic lesions, so common in the dermatology consultation, tend to be easily diagnosed. The pattern of injury (location, number of lesions, and form) usually gives us an accurate and rapid diagnosis but occasionally we may have difficulties. In these cases we must take into account less common causes such as congenital forms of hyperkeratosis, perforating diseases, paraneoplastic syndrome, or poisoning. We present this case as a reminder and to illustrate one of those rare cases of pathology that we may see in our medical consultation.

Conflict of interest

The authors declare that they have no conflicts of interest.

References

1. Majumdar KK, Ghose A, Ghose N, Biswas A, Guha Mazumder DN. Effect of safe water on arsenicosis: a follow-up study. *J Fam Med Prim Care*. 2014;3:124–8.
2. Rosenberg MJ, Landrigan PJ, Crowley S. Low-level arsenic exposure in wood processing plants. *Am J Ind Med*. 1980;1:99–107.
3. Seok J, Park KY, Li K, Kim BJ, Shim JH, Seo SJ, et al. Squamous cell carcinoma and multiple Bowen's disease in a patient with a history of consumption of traditional Chinese herbal balls. *Case Rep Dermatol*. 2015;7, July:151–5.
4. El Eit RM, Iskandarani AN, Saliba JL, Jabbour MN, Mahfouz RA, Bitar NM, et al. Effective targeting of chronic myeloid leukemia initiating activity with the combination of arsenic trioxide and interferon alpha. *Int J Cancer*. 2014;134:988–96.
5. Karagas MR, Gossai A, Pierce B, Ahsan H. Drinking water arsenic contamination, skin lesions, and malignancies: a systematic review of the global evidence. *Curr Environ Health Rep*. 2015;2:52–68.
6. Hong YS, Song KH, Chung JY. Health effects of chronic arsenic exposure. *J Prev Med Public Health*. 2014;47:245–52.
7. Hsu LI, Chen GS, Lee CH, Yang TY, Chen YH, Wang YH, et al. Use of arsenic-induced palmoplantar hyperkeratosis and skin cancers to predict risk of subsequent internal malignancy. *Am J Epidemiol*. 2013;177:202–12.
8. Kalia K, Flora SJ. Strategies for safe and effective therapeutic measures for chronic arsenic and lead poisoning. *J Occup Health*. 2005;47:1–21.
9. Kosnett MJ. The role of chelation in the treatment of arsenic and mercury poisoning. *J Med Toxicol*. 2013;9:347–54.
10. Sears ME. Chelation: harnessing and enhancing heavy metal detoxification. A review. *Sci World J*. 2013;2:19840.

J.M. Sánchez Sánchez,^{a,*} J. Molinero Caturla,^a
J.R. Ferreres Riera,^a R.M. Penín Mosquera^b

^a *Departamento de Dermatología Médico-Quirúrgica y Venereología, Hospital Universitario de Bellvitge, L'Hospitalet de Llobregat, Barcelona, Spain*

^b *Departamento de Anatomía Patológica, Hospital Universitario de Bellvitge, L'Hospitalet de Llobregat, Barcelona, Spain*

* Corresponding author.

E-mail address: joaquinazul2@yahoo.es
(J.M. Sánchez Sánchez).

<http://dx.doi.org/10.1016/j.adengl.2017.05.021>
1578-2190/

© 2017 Elsevier España, S.L.U. and AEDV. All rights reserved.