

dehiscence. Closure is performed by tissue planes, with a V-Y suture.

Close follow-up is required in the immediate postoperative period, with regular wound care.

The cosmetic result of the double hatchet flap can be excellent, as tissue of similar characteristics is used, with preservation of hair, texture, and thickness,³ rapid healing, and minimal scarring and comorbidity. Possible complications include flap necrosis, dehiscence, and the formation of hypertrophic scars.^{1,2,4,5}

For all these reasons, the double hatchet flap is one of the best techniques for its simplicity of design, speed of performance, ease of postoperative care, and excellent result in the medium and long term.⁵

Conflicts of Interest

The authors declare that they have no conflicts of interest.

References

- Schultheis K, Kaufmann R, Meissner M. The double hatchet flap as a potential alternative closure technique for scalp defects. *J Dtsch Dermatol Ges.* 2015;13:73–5.

- Cecchi R, Bartoli L, Brunetti L, Troiano G. Double hatchet flap for scalp defect reconstruction. *J Cutan Aesthet Surg.* 2016;9:45–7.
- Fernández-Calderón M, Casado-Sánchez C, Cabrera-Sánchez E, Casado-Pérez C. Versatilidad de colgajos en hacha en defectos del cuero cabelludo. *Actas Dermosifiliogr.* 2012;103:629–31.
- Sowerby LJ, Taylor M, Moore CC. The double hatchet flap. *Arch Facial Plast Surg.* 2010;12:198–201.
- Redondo-Bellón P, Redondo-Bellón P. Cirugía del cuero cabelludo. In: *Atlas Práctico de Cirugía Dermatológica.* 2nd ed. Madrid: Grupo Aula Médica; 2014.

A. Varela-Veiga,* O. Suárez-Magdalena, Ó. Suárez-Amor, B. Monteagudo

Servicio de Dermatología, Complejo Hospitalario Universitario de Ferrol, Ferrol, A Coruña, Spain

* Corresponding author.

E-mail address: ana.varela.veiga@sergas.es

(A. Varela-Veiga).

1578-2190/

© 2017 Elsevier España, S.L.U. and AEDV. All rights reserved.

Linear IgA Bullous Dermatitis Presenting as Toxic Epidermal Necrolysis[☆]



Dermatitis ampollosa IgA lineal con presentación clínica de necrólisis epidérmica tóxica

To the Editor:

Linear immunoglobulin (Ig) A dermatitis (LAD) is a rare autoimmune bullous disease characterized by the formation of subepidermal blisters with linear deposits of IgA along the basement membrane, visible on direct immunofluorescence.^{1–3} Cases of LAD mimicking other blistering diseases, such as bullous pemphigoid, pemphigus vulgaris, dermatitis herpetiformis, and impetigo, and nonbullous diseases have been reported.^{4,5}

We present the case of an 88-year-old woman receiving palliative care for metastatic squamous cell carcinoma of the vulva. She was admitted to internal medicine for cellulitis of the right lower limb, for which the portal of entry was an ulcer in the right inguinal region. Computed tomography revealed a right inguinal fluid collection of 11 cm in diameter, with gas, and osteomyelitis of the pubis that required urgent surgical debridement. The patient devel-

oped sepsis and treatment was started with ertapenem and vancomycin. Five days later, the dermatology department was consulted for the appearance of widespread desquamating erythematous lesions on the face, trunk, and limbs (Fig. 1A). Despite withdrawal of the vancomycin for suspected toxic epidermal necrolysis (TEN), LAD, or other drug-related hypersensitivity syndromes, the condition progressed to erythroderma in the space of 24 hours, with tense blisters, erosions, and epidermal separation in pressure areas (Figs. 1B and 2A), with involvement of the oral mucosa, but not of other mucosae. In view of the patient's basal situation, she was not a candidate for transfer to a specialist burns unit. Treatment was started with systemic corticosteroids and, given the lack of response, it was decided to administer immunoglobulins at a dose of 0.4 g/kg/d for 5 days. However, the condition progressed to widespread epidermal detachment (Fig. 2B) and the patient died 7 days later. Skin biopsy (Fig. 3A) revealed an epidermis with a normal maturation gradient and subepidermal vesicles full of a fibrinoid material with polymorphonuclear cells and eosinophils; these findings were consistent with a diagnosis of LAD. The superficial dermis showed a mild perivascular lymphocytic and eosinophilic inflammatory infiltrate. On direct immunofluorescence (Fig. 3B), a linear deposit of IgA was visible along the dermoepidermal junction, with no other pathological deposits with the antisera tested (fibrinogen, IgG, IgM, and complement component C3). Indirect immunofluorescence on 1 M sodium chloride-separated skin, showed the deposits to be on the epidermal side of the vesicles.

The first descriptions of LAD are attributed to Bowen in 1901, although it was not until 1979 when it was considered a separate entity from dermatitis herpetiformis.⁵ LAD is a clinically and histologically heterogeneous condition that

[☆] Please cite this article as: Ruiz-Rivero J, Hernández-Aragüés I, Pulido-Pérez A, Suárez-Fernández R. Dermatitis ampollosa IgA lineal con presentación clínica de necrólisis epidérmica tóxica. *Actas Dermosifiliogr.* 2017;108:880–882.

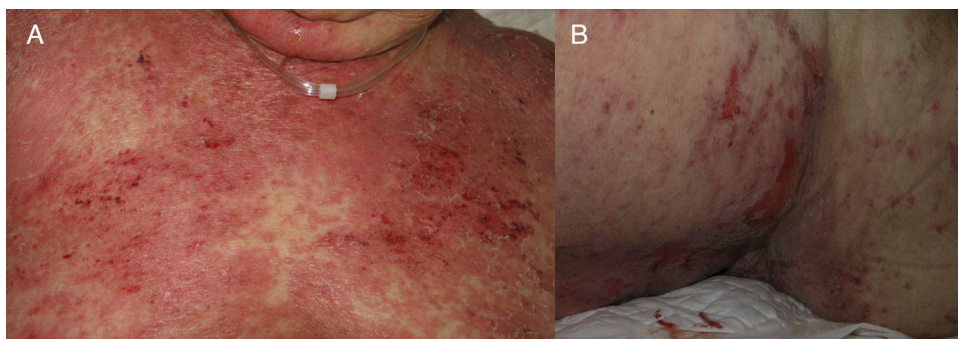


Figure 1 A, Onset of the lesions as large desquamating erythematous plaques. B, Subsequent formation of erosions.

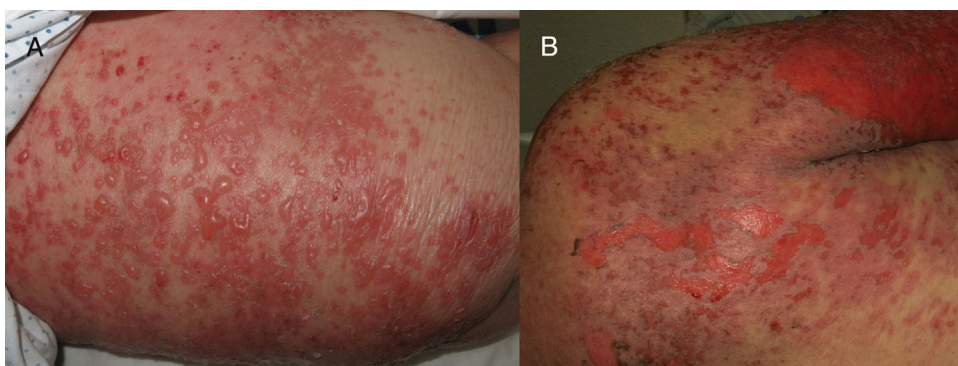


Figure 2 A, Formation of tense blisters on the thigh. B, Final stage of widespread epidermal detachment.

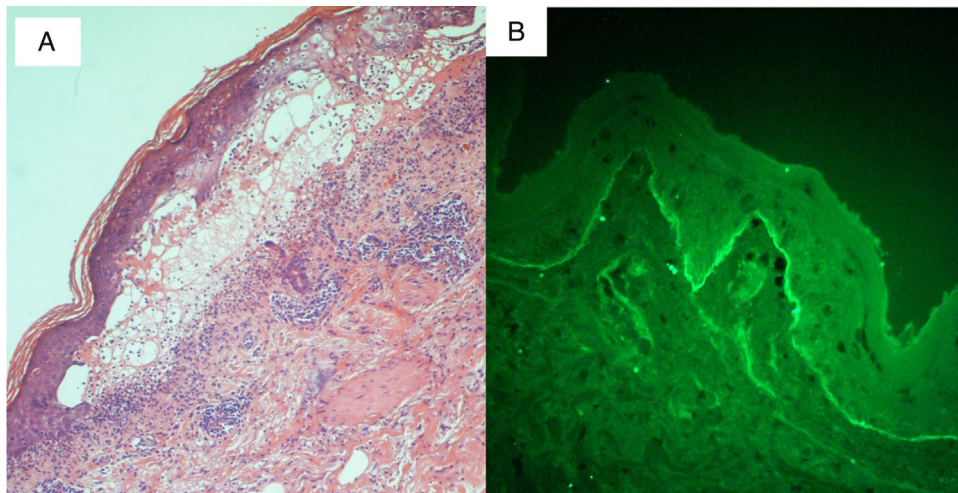


Figure 3 A, Histology. A subepidermal blister is visible, containing fibrinoid elements and polymorphonuclear cells and eosinophils. Hematoxylin and eosin, original magnification $\times 10$. B, Direct immunofluorescence. Linear deposits of immunoglobulin A are visible along the dermoepidermal junction.

includes disorders with distinct clinical courses and whose diagnostic criteria continue under discussion.⁶ There are 2 main forms. The infantile form of LAD is characterized by erythematous plaques with tense peripheral blisters with the *string of pearls* sign; this form preferentially affects the trunk, perineum, and perioral region. Although the clinical course is variable, infantile LAD tends to resolve spontaneously before puberty.^{1,3} The adult form is much more

variable and is sometimes considered to mimic other diseases.

A number of antigens have been reported to be implicated in the etiology of LAD, most importantly BP180, BP230, LAD1, and LAD97 localized on the epidermal side on indirect immunofluorescence of separated skin, and collagen VII, localized on the dermal side^{2,4,7}; it is this diversity of antigens that is thought to explain the clinical het-

erogeneity of the disease.⁷ Drug-induced and idiopathic forms are traditionally recognized. The drug-related form, occurring most commonly with vancomycin, followed by phenytoin,^{4,8,9} develops between 1 and 30 days after starting treatment. The possibility of a tumor-related form (particularly with hematologic tumors) has also been suggested. The form similar to TEN is perhaps the most striking mode of clinical presentation of LAD, as it is most commonly associated with erythroderma, a positive Nikolsky sign, and palmoplantar and mucosal involvement; vancomycin also the most frequently implicated drug.⁷

The treatment of choice is dapsone, though corticosteroids, azathioprine, methotrexate, ciclosporin, and immunoglobulins are occasionally used.^{2,3,10} The treatment of LAD that presents as TEN is no different from that of other forms of LAD, although the greater extension and severity of the skin lesions requires greater attention to physical measures. Withdrawal of the suspected drug, when there is one, is the first and sometimes only step. On other occasions it is necessary to resort to systemic corticosteroids. The prognosis will also depend on the patient's basal situation and comorbid conditions.^{2,3,7} The use of immunoglobulins in LAD, as in other blistering diseases,¹⁰ is reserved for severe and refractory cases.

In summary, LAD is a heterogeneous entity that, among its numerous forms of presentation, can mimic TEN.^{4,5,7,9} It is important to include LAD in the differential diagnosis of vesiculobullous dermatoses and of TEN, making it advisable routinely to perform not only histological study in these cases but also immunofluorescence.

Conflicts of Interest

The authors declare that they have no conflicts of interest.

References

1. Lings K, Bygum A. Linear IgA bullous dermatosis: A retrospective study of 23 patients in Denmark. *Acta Derm Venereol.* 2015;95:466–71.

2. Chaudhari S, Mobini N. Linear IgA bullous dermatosis: A rare clinicopathologic entity with an unusual presentation. *J Clin Aesthet Dermatol.* 2015;8:43–6.
3. Souza BC, Fregonesi NCFP, Tebcherani AJ, Sanchez APG, Aoki V, Fernandes JC. Linear IgA bullous dermatosis: Report of an exuberant case. *An Bras Dermatol.* 2013;88 Suppl 6: S67–70.
4. Waldman MA, Black RD, Callen JP. Vancomycin-induced linear IgA bullous disease presenting as toxic epidermal necrolysis. *Clin Exp Dermatol.* 2004;29:633–6.
5. Schroeder D, Saada D, Rafea M, Ingen-Housz-Oro S, Valeyrie-Allanore L, Sigal ML. Dermatose à IgA linéaire induite par le verapamil: présentation inhabituelle à type de nécrolyse épidermique toxique. *Ann Dermatol Venerol.* 2011;138: 302–6.
6. Antiga E, Caproni M, Fabbri P. Linear immunoglobulin A bullous dermatosis: Need for an agreement on diagnostic criteria. *Dermatology.* 2013;226:329–32.
7. Kakar R, Paugh H, Jaworsky C. Linear IgA bullous disease presenting as toxic epidermal necrolysis: A case report and review of the literature. *Dermatology.* 2013;227: 209–13.
8. Kang MJ, Kim HO, Park YM. Vancomycin-induced linear IgA bullous dermatosis: A case report and review of the literature. *Ann Dermatol.* 2008;20:102–6.
9. Tran D, Kossard S, Shumack S. Phenytoin-induced linear IgA dermatosis mimicking toxic epidermal necrolysis. *Australas J Dermatol.* 2003;44:284–6.
10. Czernik A, Toosi S, Bystryń JC, Grando SA. Intravenous immunoglobulin in the treatment of autoimmune bullous dermatoses: An update. *Autoimmunity.* 2012;45:111–8.

J. Ruiz-Rivero,* I. Hernández-Aragüés, A. Pulido-Pérez, R. Suárez-Fernández

*Servicio de Dermatología y Venereología
Médico-Quirúrgica, Hospital General Universitario
Gregorio Marañón, Madrid, Spain*

* Corresponding author.

E-mail address: juncalrr@gmail.com (J. Ruiz-Rivero).

1578-2190/

© 2017 Elsevier España, S.L.U. and AEDV. All rights reserved.

Lichen Striatus in Childhood: Is It Associated With Atopic Dermatitis?[☆]



Liquen estriado en la infancia. ¿Una entidad relacionada con la dermatitis atópica?

To the Editor:

Lichen striatus (LS) is an uncommon asymptomatic acquired dermatosis that mainly affects children.

The diagnosis is usually clinical, as the histologic findings are variable and depend on the phase of the disease. It presents with flat-topped, desquamating erythematous papules with a linear distribution along the Blaschko lines (Fig. 1).

A possible association with atopic dermatitis has been suggested.^{1–5} We designed this retrospective study in order to describe the characteristics of children with this disease and to determine whether a higher prevalence of atopic dermatitis existed in our population.

We present a case series of children diagnosed with LS at our centre in Valencia, Spain, from January 2008 to the present time, including all patients under 18 years old with compatible clinical manifestations.

Socio-demographic, clinical, histological, and therapeutic variables were analyzed, as well any relationship with possible triggering factors, including in particular atopic

[☆] Please cite this article as: García-Briz MI, Santos-Alarcón S, Fuertes-Prosper MD, Mateu-Puchades A. Liquen estriado en la infancia. ¿Una entidad relacionada con la dermatitis atópica? *Actas Dermosifiliogr.* 2017;108:882–884.