



ACTAS Derma-Sifiliográficas

Full English text available at
www.actasdermo.org



IMAGES IN DERMATOLOGY

Superficial Temporal Artery Pseudoaneurysm[☆]



Pseudoaneurisma de la arteria temporal superficial

R. Pigem,^{*} C. Baliu-Piqué, A. Bennàsar

Servicio de Dermatología, Hospital Clínic, Barcelona, Spain

Pseudoaneurysm is a rare but well-known complication of accidental or iatrogenic trauma. The large majority of those that appear on the head arise from the superficial temporal artery or its branches, although aneurysms arising from the nasal or angular arteries have also been described.

We present the case of a man who was seen in our department for a rapidly growing, soft, pulsatile nodule in the area of a skin biopsy performed 3 weeks earlier for suspected squamous cell carcinoma in the right temporal region. The lesion was asymptomatic and there were no other associated symptoms. His medical history revealed anticoagulant and antiplatelet treatment. On physical examination, we observed a nodule measuring 5 mm in diameter and with no specific pattern (Fig. 1). The nodule had a large afferent vascular structure coinciding with the path of the frontal branch of the superficial temporal artery. On dermoscopy, the nodule had a blue color with a nonspecific pattern (Fig. 2). Based on the clinical findings and the anatomical site, we made a diagnosis of pseudoaneurysm secondary to the previous intervention. Without any additional imaging studies, we ligated the afferent branch of the pseudoaneurysm and excised the lesion, leading to its resolution with no subsequent recurrence. It is important to be aware of this

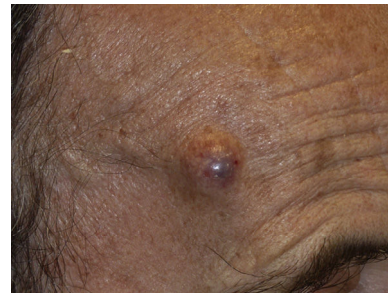

Figure 1

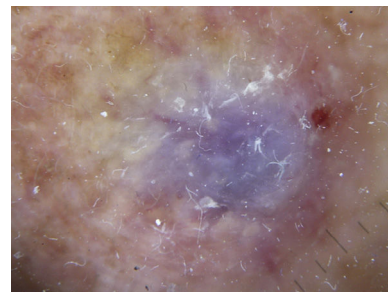


Figure 2

[☆] Please cite this article as: Pigem R, Baliu-Piqué C, Bennàsar A. Pseudoaneurisma de la arteria temporal superficial. Actas Dermosifiliogr. 2017;108:585.

^{*} Corresponding author.

E-mail addresses: RPIGEM@clinic.ub.es,
ramon.pigem@gmail.com (R. Pigem).

complication to be able to orient diagnosis and plan the most suitable treatment. Although numerous strategies have been described, surgery with ligation of the afferent and efferent vessels and excision of the pseudoaneurysm is considered to be the treatment of choice.