

atypical form of acral erythema and of its management as, in disabling cases, it can require dose reduction or a temporary interruption of the chemotherapy treatment. It is notable that all 3 of our patients were on combined treatment with cyclophosphamide and docetaxel for adenocarcinoma of the breast, and the possibility that the combination may have increased the cutaneous morbidity compared with the administration of docetaxel in monotherapy cannot therefore be excluded.

Conflicts of Interest

The authors declare that they have no conflicts of interest.

References

1. Reyes-Habito CM, Roh EK. Cutaneous reactions to chemotherapeutic drugs and targeted therapies for cancer: Part I. Conventional chemotherapeutic drugs. *J Am Acad Dermatol*. 2014;71, 203.e1-203e12.
2. Childress J, Lokich J. Cutaneous hand and foot toxicity associated with cancer chemotherapy. *Am J Clin Oncol*. 2003;26:435–6.
3. Garbe C. Antimicrotubule agents. In: Lacouture ME, editor. *Dermatologic principles and practice in oncology: Conditions of the skin, hair and nails in cancer patients*. 1st ed Philadelphia: Wiley-Blackwell; 2014. p. 208–14.
4. Miller KK, Gorcey L, McLellan BN. Chemotherapy-induced hand-foot syndrome and nail changes: A review of clinical presentation, etiology, pathogenesis, and management. *J Am Acad Dermatol*. 2014;71:787–94.
5. Minisini AM, Tosti A, Sobrero AF, Mansutti M, Piraccini BM, Sacco C, et al. Taxane-induced nail changes: Incidence, clinical presentation and outcome. *Ann Oncol*. 2003;14:333–7.
6. Winther D, Saunte DM, Knap M, Haahr V, Jensen AB. Nail changes due to docetaxel—a neglected side effect and nuisance for the patient. *Support Care Cancer*. 2007;15:1191–7.
7. Hueso L, Sanmartín O, Nagore E, Botella-Estrada R, Requena C, Llombart B, et al. Chemotherapy-induced acral erythema: A clinical and histopathologic study of 44 cases. *Actas Dermosifiliogr*. 2008;99:281–90.
8. Farr KP, Safwat A. Palmar-plantar erythrodysesthesia associated with chemotherapy and its treatment. *Case Rep Oncol*. 2011;4:229–35.
9. Scotte F, Banu E, Medioni J, Levy E, Ebenezer C, Marsan S, et al. Matched case-control phase 2 study to evaluate the use of a frozen sock to prevent docetaxel-induced onycholysis and cutaneous toxicity of the foot. *Cancer*. 2008;112:1625–31.
10. Scotte F, Tourani JM, Banu E, Peyromaure M, Levy E, Marsan S, et al. Multicenter study of a frozen glove to prevent docetaxel-induced onycholysis and cutaneous toxicity of the hand. *J Clin Oncol*. 2005;23:4424–9.

E. Rodríguez-Lomba,* I. Molina-López, R. Suárez-Fernández, O. Baniandrés-Rodríguez

Servicio de Dermatología, Hospital General Universitario Gregorio Marañón, Madrid, Spain

* Corresponding author.

E-mail address: enriquerlomba@outlook.com (E. Rodríguez-Lomba).

1578-2190/

© 2016 Elsevier España, S.L.U. and AEDV. All rights reserved.

Oral Oxybutynin for Local and Multifocal Hyperhidrosis: A Multicenter Study[☆]



Estudio multicéntrico sobre el uso de oxibutinina oral en hiperhidrosis local y multifocal

To the Editor,

Although the psychosocial consequences of hyperhidrosis are well known, the impact of this disease has traditionally been underestimated by the medical community. Oxybutynin chloride is an effective, safe, and well-tolerated treatment for hyperhidrosis that has been increasingly used since 2006. Most authors recommend a starting dose of 2.5 mg/d and a maximum dose of 15 mg/d. The safety of oxybutynin has been demonstrated in patients with hyperhidrosis.¹

However, despite its effectiveness, favorable adverse effect profile, and affordable price, this drug is not as widely used as would be expected.

We present a series of 56 patients with primary hyperhidrosis treated with oxybutynin (5-mg tablets) at 5 Spanish hospitals between May 2013 and February 2016. The patients began by taking half a tablet at breakfast and another half at lunchtime for a week. When this dosage did not achieve control of the sweating, the daily dose was increased by 2.5 mg and maintained for a week. This increase was repeated weekly until a maximum dose of 15 mg/d was reached.

The following variables were studied: sex, age, hyperhidrosis sites (palms and axillae, soles and axillae, palms and soles), starting dose (5 mg in all cases), maintenance dose, adverse effects, and, when reported, the adverse effect that caused the greatest discomfort. Patients aged over 14 years with hyperhidrosis at one or more sites that had not been treated with anything other than topical agents were included. Exclusion criteria were failure to meet the previous criteria, a contraindication for treatment with oral anticholinergics, and previous use of iontophoresis, botulinum toxin, or systemic drugs to treat their condition. All the patients or their legal representatives signed an informed consent form agreeing to the off-label use of oxybutynin.

The patients were assessed with the Hyperhidrosis Disease Severity Scale (HDSS) at the start of treatment and

[☆] Please cite this article as: Toledo-Pastrana T, Márquez-Enríquez J, Millán-Cayetano JF. Estudio multicéntrico sobre el uso de oxibutinina oral en hiperhidrosis local y multifocal. *Actas Dermosifiliogr*. 2017;108:597–599.

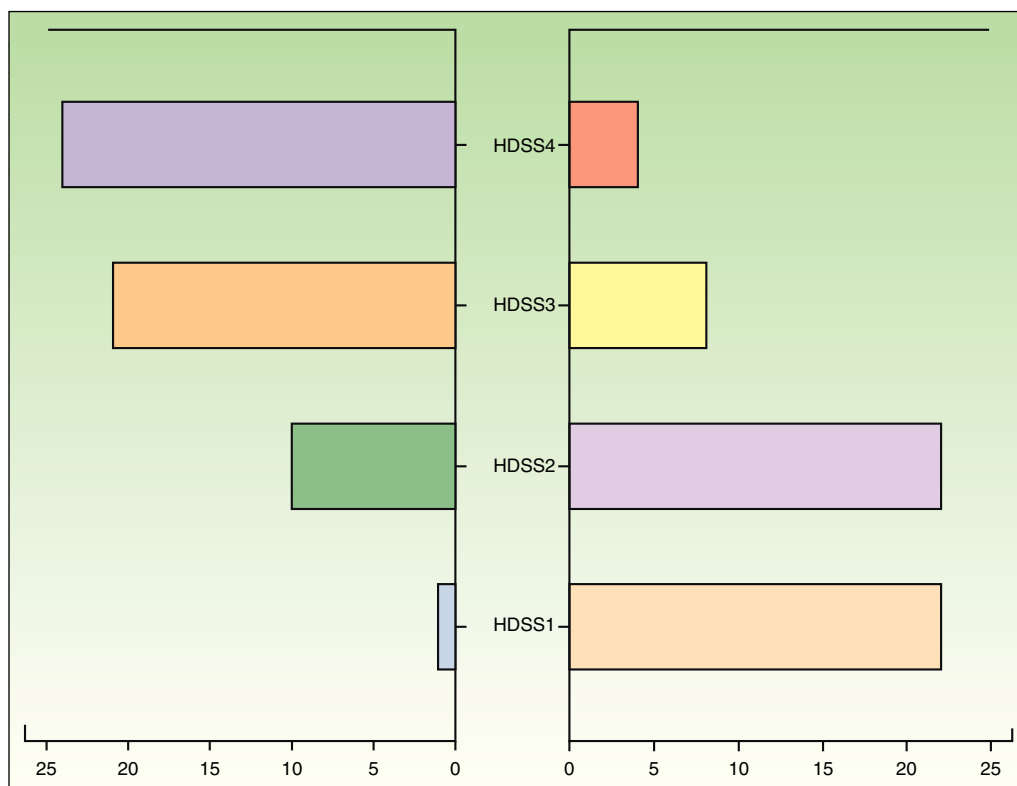


Figure 1 Numbers of patients with given Hyperhidrosis Disease Severity Scale (HDSS) scores before (left) and after (right) treatment.

at 3 months (follow-up time: 3 months from treatment initiation). We performed a descriptive analysis of the study variables and a quasi-experimental before-after-type study of changes in HDSS scores using the Wilcoxon rank-sum test. We also performed Probit regression with the aim of establishing the minimum effective dose that produces a beneficial treatment outcome. The statistical analyses were performed in SPSS (v.19.0).

We studied 56 patients (35 females and 21 males) from the following hospitals: Hospital de Jerez (n = 19), Hospital Universitario Donostia (n = 12), Hospital Quirón Sagrado Corazón (n = 10), Hospital Costa del Sol (n = 8), and Hospital de Día Quirón Donostia (n = 7). The mean age of the patients was 23.54 years (range, 14-37 years). The affected sites were the palms and axillae in 37 patients, the palms and soles in 13, and the soles and axillae in 6. No significant differences were found between the different sites in patients who responded to treatment. The most frequently used maintenance dose was 10 mg/d (Table 1).

Forty-eight patients (85.71%) showed an improvement, which was defined as a reduction in HDSS score of at

Table 1 Maintenance Dose in Patients Who Showed Improvement After 3 Months of Treatment With Oxybutynin.

5 mg	7.5 mg	10 mg	12.5 mg	15 mg	Total
4	6	17	11	5	43

Defined as a decrease in Hyperhidrosis Disease Severity Scale score of at least 2 points with respect to the score before treatment.

least 2 points (Fig. 1), 7 (12.5%) showed no change, and 1 (1.79%) showed worsening. No adverse effects were reported for 43 (76.87%) of the patients. The most common adverse effect (reported in 10.5% of cases) was a "sensation of medicalization" related to having to take the drug every 8 hours, although strictly speaking, this would be an inconvenience rather than an adverse effect. The next most common effects reported were xerosis (n = 6), nausea (n = 2), headache (n = 1), constipation (n = 1), and acute urine retention (n = 1). No statistically significant differences were observed in the Probit model, and we were therefore unable to estimate a minimum dose after which to expect desired treatment effects or adverse effects.

Until recently, oral anticholinergics were used only in patients with hyperhidrosis that proved refractory to other treatments,^{2,3} even though they are a safe and well-tolerated option. The adverse effect that caused the greatest discomfort in our series was the sensation of medicalization, felt by many patients in relation to having to indefinitely take half a tablet or a full tablet every 8 or 12 hours. As with xerosis, this effect can be controlled by taking a single dose at night.^{4,5}

We have also seen that some patients prefer not to use oxybutynin as maintenance therapy, despite its effectiveness, but rather to take it occasionally, for example when their hyperhidrosis may be less tolerable, such as before a social or work event, or at certain times of the year.

In summary, we consider that oxybutynin is an effective and efficient treatment for primary hyperhidrosis. It causes few adverse effects and can be used as occasional treatment

or as maintenance therapy. It should be considered as a possible first-line treatment for patients with focal hyperhidrosis affecting 2 or more sites or for generalized hyperhidrosis. Its price (€4.15 for 60 tablets in May 2016) is another obvious advantage, particularly for public health care systems. Larger series are needed to demonstrate the true value of this drug.

Conflicts of Interest

The authors declare that they have no conflicts of interest.

References

1. Del Boz J. Tratamiento sistémico de la hiperhidrosis. *Actas Dermosifiliogr.* 2015;106:271–7.
2. Toledo-Pastrana T. Nuevas perspectivas en hiperhidrosis. *Piel.* 2016;31:360–4.
3. Schollhammer M, Brenaut E, Menard-Andivot N, Pillette-Delaurie M, Zagnoli A, Chassain-Le Lay M, et al. Oxybutynin as a treatment for generalized hyperhidrosis: A randomized, placebo-controlled trial. *Br J Dermatol.* 2015;173:1163–8.
4. Wolosker N, Krutman M, Teivelis MP, Campbell TP, Kauffman P, de Campos JR, et al. Quality of life before hyperhidrosis

treatment as a predictive factor for oxybutynin treatment outcomes in palmar and axillary hyperhidrosis. *Ann Vasc Surg.* 2014;28:970–6.

5. Millan-Cayetano JF, del Boz J, Rivas-Ruiz F, Blázquez-Sánchez N, Hernández Ibáñez C, de Troya-Martín M. Oral oxybutynin for the treatment of hyperhidrosis: Outcomes after one-year follow-up. *Australas J Dermatol.* 2016. <http://dx.doi.org/10.1111/ajd.12473>.

T. Toledo-Pastrana,^{a,*} J. Márquez-Enríquez,^b
J.F. Millán-Cayetano^c

^a *Servicio de Dermatología, Hospital Universitario Donostia, San Sebastián, Guipúzcoa, Spain*

^b *Unidad de Gestión Clínica de Medicina Interna-Dermatología, Hospital de Jerez, Jerez de la Frontera, Cádiz, Spain*

^c *Servicio de Dermatología, Hospital Costa del Sol, Marbella, Málaga, Spain*

*Corresponding author.

E-mail address: ttoledop@gmail.com (T. Toledo-Pastrana).
1578-2190/

© 2016 Elsevier España, S.L.U. and AEDV. All rights reserved.

Sorafenib-induced Acute Generalized Exanthematous Pustulosis: An Increasing Association?



Pustulosis exantemática generalizada aguda por sorafenib: ¿una relación en aumento?

Dear Editor,

Acute Generalized Exanthematous Pustulosis (AGEP) is an acute eruption considered as a severe cutaneous adverse reaction (SCAR) related to drugs. Although antibiotics are the most common triggers, many other drugs have been associated with AGEP. More rarely, cases of non-drug-related AGEP have been reported, due to viral or bacterial

infections, spider bites or mercury hypersensitivity.¹ Here, we present the case of an AGEP triggered by the kinase-inhibitor Sorafenib and we expose a brief review of similar cases reported.

A 78-year-old woman presented to the Emergency Department with a 6-week history of an extensive, pruriginous exanthema consisting of erythematous and edematous plaques in the face, chest and upper extremities, with small isolated pustules (Fig. 1). Mucous membrane involvement was confined to the lips. Neither fever nor other systemic symptoms were evident. Two months before, she had initiated treatment with sorafenib due to an unresectable hepatocarcinoma. Skin reaction developed gradually two days after initiating the treatment.

Laboratory examination revealed a hypereosinophilia of $1.4 \times 10^9/L$. A skin biopsy was performed, rendering typical histological features of AGEP (Fig. 2). Attending to the

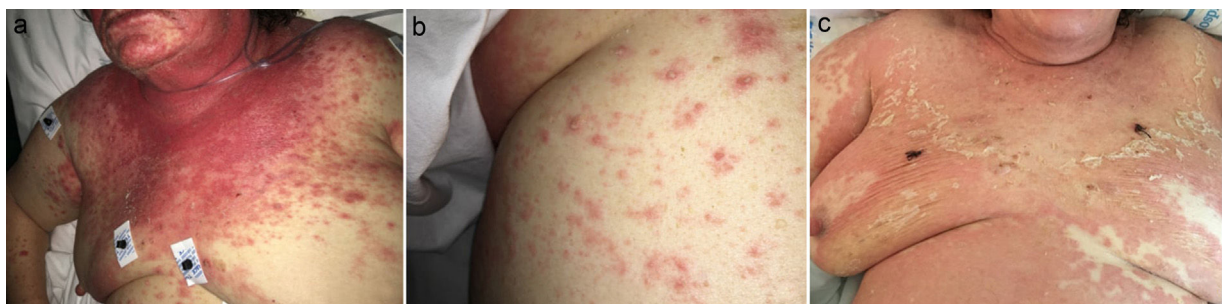

Figure 1 Clinical evolution. (a) Exanthema affecting mainly face, upper trunk, superior limbs with isolated patches on abdomen and lower extremities. (b) Closer image showing isolated pustules surrounded by erythema. (c) Evolution of the exanthema 5 days after Sorafenib discontinuation. Mild erythema and desquamation on upper trunk with pustules resolution.