

- Xanthoma-like change of the tumor after radiotherapy. *Laryngoscope*. 1983;93:202–4.
3. Ashfaq R, Timmons CF. Xanthomatous pseudotumor of the small intestine following treatment for Burkitt's lymphoma. *Arch Pathol Lab Med*. 1992;116:299–301.
  4. Chung HG, Chung YL, Kang JM, Yang WI, Suh CO, Hahn JS, et al. CD30 (Ki-1)-positive large-cell cutaneous T-cell lymphoma with secondary xanthomatous changes after radiation therapy. *J Am Acad Dermatol*. 2003;48 Suppl 2:S28–30.
  5. Tan KB, Thamboo TP, Raju GC. Xanthomatous pseudotumor. An unusual postchemotherapy phenomenon in breast cancer. *Arch Pathol Lab Med*. 2003;127:739–41.
  6. Chumsri S, Tummala MK, Khna AM, Zhao XF, Rapoport AP. Persistent positron emission tomography positivity secondary to benign histiocytic proliferation after treatment of Hodgkin lymphoma. *Leuk Lymphoma*. 2007;48:616–8.
  7. Chandra P, Wen YH, Tuli S, Raphael BG, Amorosi EL, Medeiros LJ, et al. Postchemotherapy histiocyte-rich pseudotumor involving the spleen. *Am J Clin Pathol*. 2009;132:342–8.
  8. Otto M, Shulkin BL, Kundu M, Sandlund JT, Snyder SE, Metzger ML. Histiocyte-rich xanthomatous pseudotumor mimicking relapse on positron emission tomography imaging in an adolescent with primary mediastinal diffuse large B-cell lymphoma. *J Pediatr Hematol Oncol*. 2012;34:232–5.
  9. Turrión-Merino L, Perez-Gala S, Hermosa-Zarza E, Urech-García-de-la-Vega M, Carrillo-Guijón R, Jaén-Olasolo P. Primary cutaneous CD30<sup>+</sup> anaplastic large cell lymphoma treated with radiotherapy and methotrexate with development of xanthomas at the sites of prior disease. *J Cutan Pathol*. 2016;43:400–5.
  10. Bisceglia M, Fusilli S, Zaffarano L, Fiorentino F, Tardio B. Inflammatory pseudotumor of the breast. Report of a case and review of the literature. *Pathologica*. 1995;87:59–64.
- M. González-Sabín,<sup>a,\*</sup> S. Mallo-García,<sup>a</sup> E. Rodríguez-Díaz,<sup>a</sup> P. Gonzalvo-Rodríguez<sup>b</sup>
- <sup>a</sup> *Servicio de Dermatología, Hospital de Cabueñes, Gijón, Asturias, Spain*  
<sup>b</sup> *Servicio de Anatomía Patológica, Hospital de Cabueñes, Gijón, Asturias, Spain*
- \* Corresponding author.  
*E-mail address:* martagonzalezsabin@gmail.com (M. González-Sabín).  
 1578-2190/  
 © 2016 Elsevier España, S.L.U. and AEDV. All rights reserved.

## Morphea in a Patient With Psoriasis on Treatment With Ustekinumab: Comorbidity or Adverse Effect?<sup>☆</sup>



## Morfea en una paciente con psoriasis en tratamiento con ustekinumab: ¿coexistencia o efecto adverso?

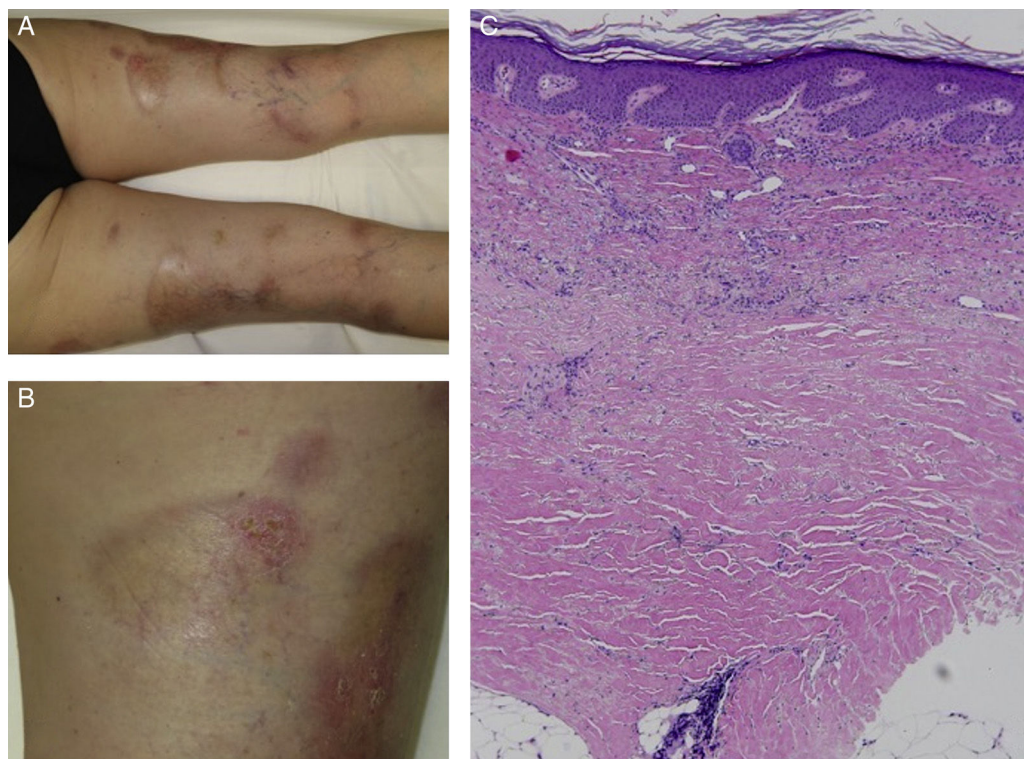
*To the Editor:*

We report the case of a 63-year-old woman with a history of pustular and plaque psoriasis that had first appeared 4 years earlier. The patient had previously received treatment with topical clobetasol, calcipotriene-betamethasone, and oral acitretin at a dose of 25 mg/d, as well as narrowband UV-B phototherapy. Because of the persistence of the lesions, we decided to initiate systemic therapy with ustekinumab. At a follow-up appointment 6 months after the start of biologic therapy, the psoriasis had improved. However, on the back of both legs, several hard, pearly plaques with violaceous edges had appeared in lightened areas of older psoriasis plaques (Figures 1A and 1B). Localized morphea was clinically suspected. A biopsy specimen was taken from one of the lesions and histologic examination resulted in a diagnosis of morphea (Figure 1C).

The coexistence of morphea and psoriasis is a rare finding in routine clinical practice. To date, 19 cases have been described in the literature (Table 1).<sup>1–8</sup> Nevertheless, psoriasis is the autoimmune disease most frequently associated with morphea, accounting for 11.6% of cases in which an immune-mediated disease occurs in conjunction with morphea.<sup>1</sup> The small number of case reports and the lack of knowledge about the pathophysiologic mechanisms of both entities make it difficult to understand this phenomenon. Nevertheless, we have developed several hypotheses.

First, our patient could have developed morphea concomitantly with psoriasis due to a common immunologic basis of the 2 entities. Multiple helper T (T<sub>H</sub>) cell differentiation pathways besides those mentioned in this article have been described; 3 such pathways are of special interest in our case.<sup>9,10</sup> The T<sub>H</sub>1 pathway and its associated interleukins (IL)—IL-2, IL-12, and interferon (IFN)  $\gamma$ —regulate cellular immunity and are associated with conditions such as psoriasis, inflammatory bowel disease, and graft-versus-host disease. The T<sub>H</sub>2 pathway—which is associated with IL-4, IL-5, and IL-13—is involved in humoral immunity and is, to date, the main pathway known to be involved in morphea. A third, recently described pathway—T<sub>H</sub>17, associated with IL-17, IL-22, and IL-23—is believed to play a more important role in immune-mediated diseases. This pathway appears to interact with the 2 pathways mentioned above. Several authors have argued that dysregulation of these pathways could be responsible for the coexistence of morphea and psoriasis in the same patient.<sup>3,4,11</sup> The immunologic environment of psoriasis, dominated by the T<sub>H</sub>1 pathway, could mask manifestations of sclerosing diseases such as morphea, which are dominated by T<sub>H</sub>2. Along these lines, Bezalel et al.<sup>11</sup> reported the case of a patient who developed plaques of morphea while receiving IFN treatment for multiple sclerosis. The authors concluded that IFN-induced activation of

<sup>☆</sup> Please cite this article as: Corral Magaña O. Morfea en una paciente con psoriasis en tratamiento con ustekinumab: ¿coexistencia o efecto adverso?. *Actas Dermosifiliogr*. 2017;108:486–488.



**Figure 1** Clinical and histologic images of the patient. A, Hard, pearly plaques with violaceous edges (lilac ring) underneath older psoriasis plaques on the lower limbs. B, More detailed image showing the coexistence of morpheaform plaques and erythematous plaques with a psoriasiform appearance. C, Densely packed collagen bands in the deep reticular dermis, parallel to the dermoepidermal junction (hematoxylin-eosin, original magnification  $\times 10$ ).

the  $T_H2/IL-4$  pathway could have triggered the appearance of morphealike lesions.

The immunogenic hypothesis is also supported by the fact that antinuclear antibody positivity is more prevalent in patients with both psoriasis and morphea.<sup>4</sup>

Taking into account the information outlined above, it is also possible that the introduction of ustekinumab, an anti-IL-12/23 monoclonal IgG1 antibody, could have blocked the  $T_H1$  signaling pathway, leading to increased expression of  $T_H2$  and consequently the formation of morphea plaques in a predisposed patient. Therefore, we cannot rule out the possibility that the development of morphea in our patient was an adverse effect of ustekinumab. This drug was approved by the US Food and Drug Administration in June 2008. We have found no reports to date of ustekinumab being associated with the development of morphea. However, an association between etanercept and morphea plaques—extending from the injection site—has been reported in a patient with psoriasis.<sup>6</sup>

Finally, in a predisposed patient, the psoriasis itself could have triggered the morphea—an example of the Wolf isotopic response.

In conclusion, we cannot rule out any of the 3 hypotheses: immunologic, pharmacologic, and the Wolf isotopic response. Likewise, it is impossible to know whether the morphea was previously present under the psoriasis plaques. Nevertheless, we believe that the 3 hypotheses are not mutually exclusive; the interaction of the drug with an

**Table 1** Cases Reported in Indexed Journals of Psoriasis and Morphea in the Same Patient.

Case No.	Age, y <sup>a</sup>	Sex	Initial Diagnosis
1-5 <sup>1</sup>	—	—	—
6 <sup>2</sup>	65	M	Morphea
7 <sup>3</sup>	62	F	Psoriasis
8 <sup>4</sup>	24	F	Psoriasis
9-16 <sup>5</sup>	—	—	—
17 <sup>b,6</sup>	45	F	Psoriasis
18 <sup>7</sup>	—	—	—
19 <sup>8</sup>	45	F	Morphea

Abbreviations: M, male; F, female.

<sup>a</sup> Age at first diagnosis.

<sup>b</sup> Patient was being treated with etanercept at the time of the diagnosis of morphea.

altered immune system could have caused the development of morphea in our patient. Reports of similar new cases and a better understanding of the pathophysiologic mechanisms of both diseases could shed light on this enigma.

### Conflicts of Interest

The authors declare that they have no conflicts of interest.

## References

- Leitenberger JJ, Cayce RL, Haley RW, Adams-Huet B, Bergstresser PR, Jacobe HT. Distinct autoimmune syndromes in morphea: A review of 245 adult and pediatric cases. *Arch Dermatol*. 2009;145:545–50.
- Burns DA, Sarkany I. Generalized morphea with bullous lesions and psoriasis. *Br J Dermatol*. 1976;95 Suppl 14:33–4.
- Bilen N, Apaydin R, Erçin C, Harova G, Ba F, Bayramgiirler D. Coexistence of morphea and psoriasis responding to acitretin treatment. *J Eur Acad Dermatol Venereol*. 1999;13:113–7.
- Saleh Z, Arayssi T, Saleh Z, Ghosn S. Superficial morphea: 20-year follow-up in a patient with concomitant psoriasis vulgaris. *J Cutan Pathol*. 2009;36:1105–8.
- Walls AC, Qureshi AA. Psoriasis and concomitant fibrosing disorders: Lichen sclerosis, morphea, and systemic sclerosis. *J Am Acad Dermatol*. 2010;67:1079–83.
- Stewart FA, Gavino AC, Elewski BE. New side effect of TNF-alpha inhibitors: Morphea. *Skinmed*. 2013;11:59–60.
- Shevliakov LV, Koncha AI. Combination of focal scleroderma and psoriasis. *Vestn Dermatol Venerol*. 1987;7:70 [Article in Russian].
- Aounallah A, Zaraq I, El Euch D, Chelly I, Haouet S, Mokni M, et al. Lipomembranous panniculitis associated with venous insufficiency, morphea, and psoriasis. *Skinmed*. 2016;14:127–9, eCollection 2016.
- Cuesta-Montero L, Belinchón I. Conectivopatías y psoriasis. *Actas Dermosifiliogr*. 2011;102:487–97.
- Akdis M, Palomares O, van de Veen W, van Splunter M, Akdis CA. Th17 and Th22 cells: A confusion of antimicrobial response with tissue inflammation versus protection. *J Allergy Clin Immunol*. 2012;129:1438–49.
- Bezalel SA, Strober BE, Ferenczi K. Interferon beta-1a-induced morphea. *JAAD Case Rep*. 2015;1:15–7.

O. Corral Magaña, J. Escalas Taberner,\*  
M.M. Escudero Góngora, A. Giacaman Contreras  
*Servicio de Dermatología, Hospital Universitario Son Espases, Palma de Mallorca, Islas Baleares, Spain*

\* Corresponding author.

E-mail address: [jetpalma@hotmail.com](mailto:jetpalma@hotmail.com)

(J. Escalas Taberner).

1578-2190/

© 2016 Elsevier España, S.L.U. and AEDV. All rights reserved.

## Chondrocutaneous Graft for Reconstruction of the Ala Nasi<sup>☆</sup>



### Reconstrucción del ala nasal mediante injerto condrocútáneo

To the Editor:

The external nose is a sun-exposed area with a high incidence of skin tumors. These tumors are treated surgically in the majority of cases. The nasal ala, composed of mucosa, cartilage, and skin, is an anatomically complex structure and its reconstruction is thus also complex.<sup>1</sup> During reconstruction of defects of the ala we must take into account the size and thickness of the defect, the color and texture of the surrounding skin, symmetry with the contralateral ala, and the condition of the perilesional tissues. We must also evaluate the characteristics of possible donor sites and the patient's past history. The main objective is to preserve the valve function and the cosmetic appearance of the external nose.

We describe the case of a 77-year-old woman with a complex past history. She presented biopsy-confirmed recurrence of basal cell carcinoma on the right nasal ala.

The tumor recurrence (Fig. 1A) was treated using Mohs micrographic surgery (Fig. 1B), with complete excision being achieved in a single stage. This surgery left a full-thickness

defect of the nasal ala measuring  $0.8 \times 1$  cm, affecting the free border of the ala.

To repair the defect we decided to use a composite chondrocutaneous graft from the base of the helix. In this situation, the ideal donor site is the auricle of the ear not only for color and texture, but also because the anterior region of the helix permits simple graft extraction and direct closure.<sup>2</sup> The graft obtained presents cartilage between 2 skin surfaces. The cartilage provides mechanical stability and form to the graft and to the nasal ala, preventing collapse of the graft with respiratory movements.<sup>3</sup> Additionally, the cartilage prevents scar retraction and secondarily preserves valve function.

In our patient, we first designed and excised a V-shaped en bloc graft from the base of the helix, 1 mm larger than the defect (Fig. 1C).<sup>4</sup> The resulting defect in the helix was closed using interrupted sutures (Fig. 2B).

To fix the graft to the receptor site, we first sutured the tissue to the internal surface of the nasal ala using an absorbable 5/0 suture. The graft was then immobilized using a nasal pack. Finally, the skin of the external surface was sutured with 5/0 silk (Fig. 2A).<sup>3</sup>

The use of a composite graft from the auricle of the ear to reconstruct the external nose was first described by König<sup>5</sup> in 1902. Its main advantages are that surgery can be performed in a single stage, with an en bloc graft, allowing the procedure to be completed in a single operation.

Factors that can reduce chondrocutaneous graft survival include smoking, alteration of the vascular supply by previous radiotherapy, the presence of scars, diabetes, and severe arteriosclerosis. Large grafts have high metabolic demands, reducing their likelihood of survival. Previous reports have therefore recommended a maximum diameter of 10 mm for chondrocutaneous grafts.<sup>3,4,6</sup> However, good results have been reported with grafts up to  $10 \times 18$  mm.<sup>7</sup>

<sup>☆</sup> Please cite this article as: Kueder-Pajares T, Prada-García C, Sanchez-Sambucety P, Rodríguez-Prieto MA. Reconstrucción del ala nasal mediante injerto condrocútáneo. *Actas Dermosifiliogr*. 2017;108:488–490.