



ACTAS Derma-Sifiliográficas

Full English text available at
www.actasdermo.org



IMAGES IN DERMATOLOGY

Bullous Pemphigoid on the Areola of Breast[☆]

Penfigoide ampoloso localizado en la aréola mamaria



P. López Jiménez, Á. Vargas Nevado,* E. Herrera Ceballos

Servicio de Dermatología, Hospital Universitario Virgen de la Victoria, Málaga, Spain

A woman aged 84 years with a past history of hypertension consulted for the appearance of vesiculobullous lesions on her left areola (Fig. 1A). The lesions, which had appeared about 20 days earlier, were pruritic but were not associated with systemic symptoms. Initial treatment with topical antibiotics did not produce a response. Physical examination revealed tense vesicles and blisters with a serous or blood-stained content, and residues of blisters that had ruptured and erosions covered by serosanguinous scabs.

Skin biopsy showed a subepidermal blister with edema of the papillary dermis and an inflammatory infiltrate with abundant eosinophils. Direct immunofluorescence revealed

linear deposits of immunoglobulin G and complement along the basement membrane (Fig. 1B). Based on these findings, we made a diagnosis of localized bullous pemphigoid. Treatment was started with topical high-strength corticosteroids; improvement was observed after 2 weeks of treatment and no new lesions appeared over 2 years of follow-up. Mammography and screening for tumor markers were performed to exclude underlying neoplastic disease.

Localized bullous pemphigoid is a rare variant. With regard to its presentation only on the breast, triggers that have been suggested include trauma, UV exposure, and radiotherapy related to breast cancer.

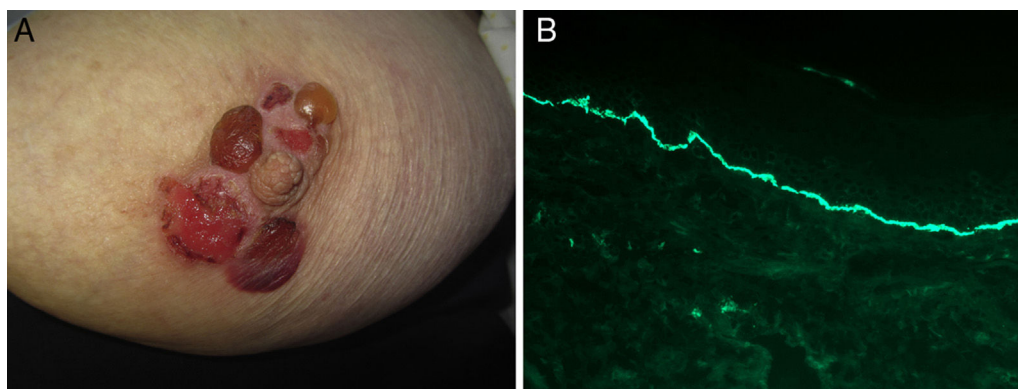


Figure 1

[☆] Please cite this article as: Jiménez PL, Nevado ÁV, Ceballos EH. Penfigoide ampoloso localizado en la aréola mamaria. Actas Dermosifiliogr. 2017;108:260.

* Corresponding author.

E-mail address: avargasn88@gmail.com (Á.V. Nevado).