




ACTAS Derma-Sifiliográficas

Full English text available at
www.actasdermo.org



REVIEW

Inflammatory Skin Conditions Associated With Radiotherapy[☆]



I. Hernández Aragüés,^{*} A. Pulido Pérez, R. Suárez Fernández

Servicio de Dermatología, Hospital General Universitario Gregorio Marañón, Madrid, Spain

Received 12 April 2016; accepted 11 September 2016

Available online 24 February 2017

KEYWORDS

Radiotherapy;
Radiation-induced skin reactions;
Radiotherapy-induced skin reactions;
Radiodermatitis;
Erythema multiforme after radiation;
Eosinophilic polymorphic pruritic eruption associated with radiotherapy syndrome;
Recall phenomenon; erythema multiforme associated with phenytoin and cranial radiation therapy syndrome;
Radiation-induced morphea;
Sclerodermiform-like panniculitis after radiation

Abstract Radiotherapy for cancer is used increasingly. Because skin cells undergo rapid turnover, the ionizing radiation of radiotherapy has collateral effects that are often expressed in inflammatory reactions. Some of these reactions—radiodermatitis and recall phenomenon, for example—are very familiar to dermatologists. Other, less common radiotherapy-associated skin conditions are often underdiagnosed but must also be recognized.
© 2016 Elsevier España, S.L.U. and AEDV. All rights reserved.

[☆] Please cite this article as: Hernández Aragüés I, Pulido Pérez A, Suárez Fernández R. Dermatitis inflamatorias asociadas a radioterapia. Actas Dermosifiliogr. 2017;108:209–220.

^{*} Corresponding author.

E-mail address: ignaciohdezaragues@gmail.com (I. Hernández Aragüés).

PALABRAS CLAVE

Radioterapia;
 Dermatitis
 radioinducidas;
 Dermatitis
 radioterapia;
 Radiodermatitis;
 Eritema multiforme
 posradioterapia;
 Síndrome erupción
 pruriginosa polimorfa
 eosinofílica asociada
 a radioterapia;
 Fenómeno de recall;
 Síndrome *erythema
 multiforme
 associated with
 phenytoin and cranial
 radiation therapy*;
 Morfea radioterapia;
 Paniculitis pseu-
 doesclerodermiforme
 postirradiación

Dermatitis inflamatorias asociadas a radioterapia

Resumen La radioterapia es una técnica de uso creciente en el campo de la oncología. Debido al alto recambio celular cutáneo, la radiación ionizante afecta colateralmente a la piel y encontramos de forma frecuente dermatosis inflamatorias asociadas a radioterapia. Algunos de estos cuadros, como la radiodermatitis o el fenómeno de recall, son bien conocidos por el dermatólogo. Es importante reconocer otros cuadros cutáneos asociados a radioterapia que aparecen de forma menos frecuente y que en muchas ocasiones son infradiagnosticados.

© 2016 Elsevier España, S.L.U. y AEDV. Todos los derechos reservados.

Introduction

Radiotherapy is used often in oncology: it is prescribed for nearly half of cancer patients as monotherapy or in combination with other treatments. In the skin, where the rate of cell turnover is high, ionizing radiation has collateral effects that make adverse reactions very common. Up to half of patients reportedly develop at least mild radiodermatitis,¹ and there is a small percentage of patients who also present more serious skin conditions affecting large surface areas.

We propose a classification system for skin conditions that appear exclusively in the context of radiotherapy and that may or may not be dose dependent (Table 1). Thus, we also discuss radiation-induced or radiation-exacerbated conditions without a clear dose-dependent relationship.

Although this review focuses on inflammatory dermatoses that follow radiotherapy, we also warn of the long-term risk for secondary tumors in the irradiated field² and for angiosarcoma in breast cancer patients who receive radiotherapy³ as well as risk for so-called atypical vascular lesions⁴ and acquired lymphangiectasis.⁵

Because many of these conditions are probably underdiagnosed or erroneously assumed to be more widely known syndromes like radiodermatitis, it is important to be aware of their individual clinical features. Beyond the issue of diagnosis itself, we should remember that appropriate

initial management of some of these conditions can improve prognosis.

Table 1 Proposed Classification System for Inflammatory Skin Conditions Associated With Radiotherapy.

Conditions induced exclusively by radiotherapy*Dose dependent conditions*

Radiodermatitis (acute, chronic)

Conditions without clear dose dependency

Recall phenomenon

Radiotherapy-associated eosinophilic, polymorphous, pruritic eruption syndrome

Sclerodermiform-like panniculitis

Skin conditions triggered or exacerbated by radiotherapy

Exudative erythema multiforme, Stevens–Johnson syndrome, postradiation toxic epidermal necrolysis

EMPACT syndrome

Radiation-induced autoimmune blistering diseases

Radiation-induced lichen planus

Radiation-induced morphea

Other: Lupus erythematosus, neutrophilic dermatosis, GVHD, milium cysts, lichen sclerosus et atrophicus

Abbreviation: EMPACT, erythema multiforme associated with phenytoin and cranial radiation therapy; GVHD, graft-vs-host disease

Skin Conditions Induced Exclusively by Radiotherapy

Dose-Dependent Conditions

Radiodermatitis

Radiodermatitis consists of a set of cutaneous manifestations secondary to exposure to ionizing radiation and linked to individual risk factors (Table 2), total dose received, and depth of penetration.⁶

The acute form develops within 90 days of therapy and the chronic form appears later.

Acute radiodermatitis. The acute form generally appears in the irradiated zone an average of 10 to 14 days after radiotherapy.⁶ Currently, the clinical manifestations are mild to moderate in their intensity, attributable to advances in modern devices such as linear accelerators and megavoltage units that assist in delineating the radiation field (conformal radiotherapy) and in appropriately fractioning the dose.

The severity of acute radiodermatitis is usually classified in 4 levels according to the fourth version of the unified criteria of the National Cancer Institute⁷ (Table 3). The initial stages are marked by desquamation and limited extension. The rash then becomes progressively more exudative, extends beyond skin folds, and finally causes cutaneous necrosis and ulceration.

The synergy between chemotherapy and radiotherapy in treating malignant tumors sometimes increases toxic skin effects. New targeted therapy drugs, such as anti-epithelial growth factor agents (cetuximab, panitumumab) associated with radiation usually trigger high-grade acute radiodermatitis early because these drugs have radiosensitizing effects.⁸ A higher rate of late cutaneous fibrosis has also been described in association with their use.⁹

The immediate appearance of acute radiodermatitis is the result of structural changes that occur when ionizing radiation leads to the release of free radicals that damage DNA and alter the maturation and reproduction

of basal stem cells in the epidermis.¹⁰ This process alters the barrier function of the epidermis, leading to greater transdermal loss of water and partial or total epidermal necrosis. A proinflammatory environment is also generated through local recruitment of white blood cells and sustained production of interleukin (IL) 1.¹¹ Angiogenesis, fibrogenesis, and the formation of granulation tissue also change during the process.^{12,13} The loss of Langerhans cells combined with a proinflammatory environment and impairment of the epidermal barrier function can invite superinfections.¹⁴

Reduced mitotic activity of the germ cells of sebaceous glands, hair follicles, and the epidermis accounts for the dryness, hair loss and other manifestations associated with radiotherapy.

Histopathology reveals epidermal changes, including vacuolar degeneration of the basement membrane and necrotic keratinocytes as well as the presence of spongiosis that can lead to subepidermal blister formation.¹⁵ Perivascular inflammatory infiltrates, dilated blood vessels with thrombi, and dermal edema can also be observed.

Recent systematic reviews of means to prevent and treat acute radiodermatitis describe management strategies in detail and include the following recommendations^{1,16}:

- Wash the irradiated areas with a mild shampoo or soap to prevent superinfection.
- Although deodorants containing aluminum salts or pads containing metals were formerly believed to increase radiotherapeutic toxicity and were therefore contraindicated, clinical trials have demonstrated that these products do not exacerbate the severity of radiodermatitis (evidence level IA).^{16,17}
- The use of topical corticosteroids, for their anti-inflammatory effect, is controversial. Medium to high potency corticosteroids are effective in treating already established radiodermatitis,¹⁸ but trials have been unable to demonstrate their efficacy in reducing the severity of radiodermatitis when used prophylactically. However,

Table 2 Risk Factors for Radiodermatitis.

External Factors	Patient Factors
<i>Radiotherapy protocol</i>	<i>Genetic diseases</i>
Total dose	Ataxia–telangiectasia, ATM heterozygosity
Dose fractioning	Gorlin syndrome
Surface and volume of application	Fanconi anemia
Type of radiation	Bloom syndrome
<i>Radiosensitizing drugs</i>	Xeroderma pigmentosum
Increased cell damage	<i>Connective tissue disease</i>
<i>Physical factors</i>	Systemic lupus erythematosus
Obesity (marked skin folds)	Scleroderma
Smoking	Rheumatoid arthritis
Malnutrition	<i>Infectious diseases</i>
Prior actinic damage	Human immunodeficiency virus infection
Sun exposure	

Abbreviation: ATM, ataxia telangiectasia mutated gene protein.

Table 3 Acute Radiodermatitis Severity Scale According to the National Cancer Institute (Version 4).





	Grade 1	Grade 2	Grade 3	Grade 4
Skin lesions	Faint erythema Dry scaling	Moderate-brisk erythema Moist desquamation	Intense erythema Pitting edema Moist desquamation	Ulceration Necrotic plaques
Epidermal necrosis	No	No	Superficial	Full thickness dermis
Location	Initially follicular	Mostly confined to skin folds	Not confined to skin folds	Not confined to skin folds
Other	Depigmentation, hair loss	Moderate edema	Hemorrhagic zones after trauma	Spontaneous bleeding
Examples				

Table 4 Chronic Radiodermatitis Severity Scale^a

	Grade 1	Grade 2	Grade 3	Grade 4
Skin	Slight atrophy Some hair loss Hyper- or Hypopigmentation	Patch atrophy Total hair loss Telangiectasia	Marked atrophy Gross telangiectasia	Ulceration
Subcutaneous cellular tissue	Slight induration (fibrosis) and partial loss of tissue	Moderate fibrosis (asymptomatic) Field contracture < 10% linear reduction	Severe induration and loss of subcutaneous tissue Field contracture > 10% linear reduction	Necrosis
Mucous membrane	Slight atrophy Slight dryness	Moderate atrophy Telangiectasia	Marked atrophy with associated intense dryness Thick telangiectasia	Ulceration

^a Source: Adapted from Toxicity Criteria of the Radiation Therapy Oncology Group and the European Organization for Research and Treatment of Cancer, 1995.²⁰

they do improve quality of life by reducing itching and burning.¹⁶

- If a superinfection is suspected, a bacterial culture should be started, along with topical (silver sulfadiazine cream) or systemic (antibiotic) treatment.

Special precautions should be taken with gynecologic or anal canal tumors because they are associated with grade 3 or 4 severity and greater risk of superinfection.

- Skin folds should be exposed to air because they are more often affected by radiodermatitis,⁶ Restrictive clothing, exposure to sunlight, and injury are to be avoided.

Aloe vera, trolamine salicylate creams, hyaluronic acid, and silver or sucralfate dressings have not proven useful for preventing or treating radiodermatitis.¹⁶

A lower grade of erythema was reportedly achieved in a single open-label trial of amifostine, used because of its cytoprotective role in radiotherapy and cisplatin chemotherapy.¹⁹ The trial enrolled 30 patients.

Chronic radiodermatitis. The chronic form of radiodermatitis appears months or years after irradiation. This condition must be distinguished from so-called late effects of radiotherapy, which are the result of a failure to previously cure high-grade acute radiodermatitis.

There are various stages of chronic radiodermatitis according to the classification of the Radiation Therapy Oncology Group and the European Organization for Research and Treatment of Cancer,²⁰ whose system is based on the extension and severity of cutaneous changes (Table 4).

The condition presents with poikiloderma, hyper- or hypopigmented areas, atrophy, and telangiectasia (Fig. 1). Probably related to microvascular damage, telangiectasia is more common in grade 3 or higher, especially after a booster dose of radiation.²¹ Desquamation, hyperkeratosis, and xerosis are also common. Loss of nails, hair and skin adnexa may occur and sweating may be impaired in some parts of the body.

Localized or generalized cutaneous fibrosis is another form of presentation. Retraction and associated impence

of movement may develop. Fibrosis is triggered by various factors, but the role of transforming growth factor (TGF) β stands out. This factor activates fibroblasts, which synthesize and secrete procollagen and other components of the extracellular matrix.²²

On histology, epidermal atrophy, endothelial hyperplasia, and sclerotic or thrombosed vessels can be observed. If cutaneous fibrosis develops, the dermis and subcutaneous tissue will be replaced by fibrous tissue and atypical fibroblasts.²³

Pulsed laser therapy has been reported to be useful in treating persistent telangiectasia.²⁴ Fibrosis is the most difficult cutaneous complication to treat. Pentoxifylline has been tried at a dose of 800 mg/d on its own or in combination with vitamin E.²⁵ This peripheral vasodilator also has antifibrotic properties related to a reduction in TGF- β expression and the phenotypic normalization of altered fibroblasts. Studies in humans that clearly demonstrate the efficacy of this approach are scarce, however.¹⁶ There are anecdotal reports of attempts to use other therapeutic

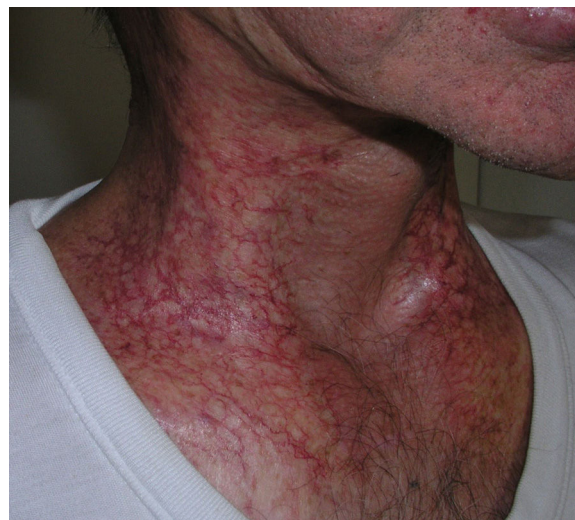

Figure 1 Chronic radiodermatitis with marked skin atrophy and numerous telangiectases.

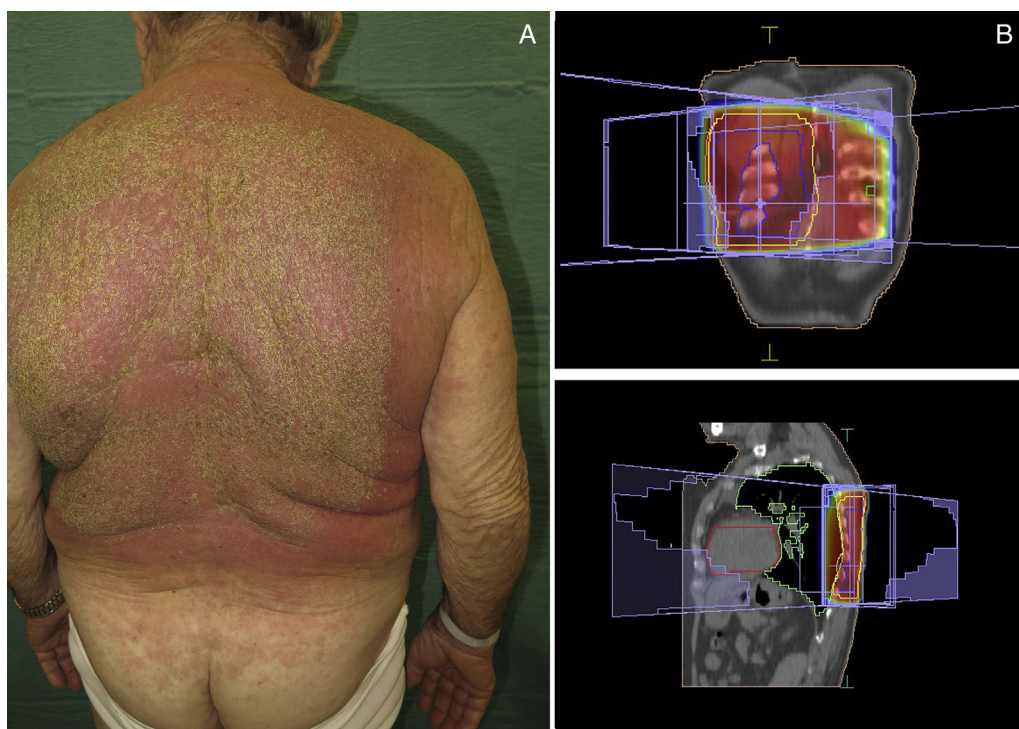


Figure 2 A, Recall Phenomenon in a patient irradiated for soft-tissue sarcoma. B, Map of the irradiated field.

modalities, such as intramuscular injections of liposomal copper/zinc superoxide dismutase 3 weeks after onset of fibrosis²⁶ and low-dose interferon- γ based on its inhibition of dermal fibroblasts.²⁷

Conditions Without a Clear Dose-Dependent Relationship

Recall Phenomenon

A rash confined to previously irradiated skin, recall phenomenon is triggered by certain drugs, mainly chemotherapy agents. A variable amount of time (from days to years) during which the skin appears healthy, without associated radiodermatitis, may pass before signs appear.²⁸ A minimum of 7 days between radiotherapy and drug intake is required for a diagnosis of recall phenomenon, since certain clinical pictures that emerge before that time might be triggered by radiosensitizing substances. Cases of recall phenomenon have been described up to 7 years after radiotherapy.²⁹ The median interval, however, is 39.5 days.²⁸

The skin is affected in 2 out of every 3 patients, but recall has also presented as pneumonitis, mucositis, and esophagitis; the central nervous system and small intestine have also been affected.²⁸

Drugs that trigger the recall phenomenon are usually chemotherapy agents, most often taxanes (paclitaxel, docetaxel) and anthracyclines (adriamycin, doxorubicin), which together account for half the described cases. Other implicated chemotherapeutic agents are bleomycin, actinomycin D, gemcitabine, 5-fluorouracil, methotrexate, and vinblastine. Medications that are not cytotoxic, such

as antituberculosis drugs,³⁰ tamoxifen,³¹ antibiotics,³² and simvastatin³³ have also been blamed.

Clinical manifestations, which overlap those of acute radiodermatitis, involve an erythematous plaque that is more or less exudative and has well defined edges coinciding with the irradiated field (Fig. 2). Recall can be distinguished, however, by the fact that radiodermatitis or other lesions need not have developed previously in the irradiated field (Table 5). Depending on severity of the eruption, blisters, ulcers, hemorrhagic zones, or necrosis might develop. Signs and symptoms are more intense when the interval between the use of radiotherapy and the chemical trigger is shorter.²⁸





There seems to be a radiation dose threshold that must be reached for recall dermatitis to develop. Patients who received radiation on several fields at different doses have been reported to develop a recall phenomenon only on more intensely treated fields.³⁴

Likewise, the time elapsing between therapy and the appearance of a recall phenomenon also seems to be dose dependent, as higher doses lead to more rapid reactions.²⁸ In addition, intravenous administration of the trigger drug produces a more rapid recall phenomenon than oral administration.

Histologic findings overlap those of both acute and chronic forms of radiodermatitis. The fairly nonspecific findings described include vacuolar degeneration of the basement membrane, necrotic keratinocytes, and superficial vascular ectasia.³⁵ A mixed inflammatory infiltrate, dermal sclerosis, and a psoriasiform pattern of dermatitis are also common.³⁶

Pathophysiologic observations described in the context of recall phenomenon have included vascular injury in the

Table 5 Differential Diagnosis of Eruptions in Patients Exposed to Radiation.

	Radiodermatitis	Recall Phenomenon	Erythema Multiforme	SJS/TEN/SJS-TEN
Extension	Irradiated field	Irradiated field	Irradiated field + dissemination	Irradiated field + dissemination
Rash type	Erythema/desquamation/ulceration	Erythema/desquamation/edema	Maculopapular	Maculopapular + mucositis
Latency period, after radiotherapy	2 wk	1 wk to months	10–20 d	10–20 d
Fever	Yes/no	No	Yes/no	Yes/no
Mechanism	Cytotoxicity	Possible hypersensitivity	Hypersensitivity	Hypersensitivity
				

Abbreviations: SJS, Stevens–Johnson syndrome; TEN, toxic epidermal necrolysis.

irradiated zone³¹ and cellular reduction or changes in the basement membrane of the epidermis.³⁷

Currently the most widely accepted theory holds that recall phenomenon is a hypersensitivity drug reaction³⁵ similar to a fixed drug eruption. According to this view, it would be a nonimmunologically mediated inflammatory reaction. Supporting the theory is the high frequency of onset after first exposure to a trigger drug in HIV-infected patients with CD4 counts under 30.³⁸ Also pertinent is the proinflammatory role of increased secretion of cytokines such as IL-1, IL-6, and tumor necrosis factor in the irradiated field. Thus, these patients develop the inflammatory response at a lower radiation threshold as soon as the trigger drug responsible for the recall phenomenon is introduced.

The cornerstone of treatment is to withdraw the trigger drug, after which the eruption should improve quickly. Systemic or topical corticosteroids and antihistamines have not been associated with rapid improvement in established symptoms.³⁹ Reexposure to the trigger reproduces the recall phenomenon in about 75% of the cases, although the eruption is usually less intense.³⁹ If the drug is used again, a lower dose can be given or it can be accompanied by oral corticosteroids in an attempt to prevent an inflammatory response.²⁸

Radiotherapy-Associated Eosinophilic, Polymorphous, Pruritic Eruption Syndrome

The term eosinophilic, polymorphous, pruritic eruption associated with radiotherapy (EPPER syndrome) was first used in 1999 by Rueda et al.⁴⁰ in a study of 83 cancer patients, 17% of whom developed an extensive pruritic rash after radiotherapy. Histology of the lesions showed an abundant

eosinophilic inflammatory infiltrate similar to that seen in other eosinophilic skin conditions. This clinical picture typically appears during a radiotherapy cycle or immediately afterwards, although there have been reports of cases in which the rash appeared 9 months later.⁴¹

EPPER syndrome was initially described as a polymorphous condition characterized by erythematous papules and abrasions, although wheals, vesicles, firm blisters, or nodules sometimes also appear (Fig. 3). The eruption extends beyond the irradiated field and has a predilection for the extremities. Mucous membranes or palms and soles remain unaffected. Intense generalized pruritus is typical, and symptoms may last weeks or even months.⁴⁰ Pustular lesions have also been described.⁴²

The majority of patients who develop EPPER syndrome have squamous cell tumors, mainly cervical carcinoma, but this complication has also been described in patients treated for solid tumors.

The pathophysiologic mechanism is poorly understood. It has been suggested that EPPER syndrome may be a type I (immunoglobulin [Ig] E-mediated) hypersensitivity reaction involving the release of several cytokines. A type IV hypersensitivity reaction, related to the clonal expansion of type-2 helper T cells—similar to events in systemic hypereosinophilic syndromes—has also been suggested.

A necessary finding for a pathophysiological diagnosis of EPPER syndrome is the presence of a dense, superficial and deep perivascular inflammatory infiltrate (Fig. 3) with over 10 000 eosinophils/mm³. Intraepidermal vesicles with eosinophils and subepidermal blisters that are histologically indistinguishable from bullous pemphigoid may also be observed although direct immunofluorescence at the dermal-epidermal junction is negative. Necrotic

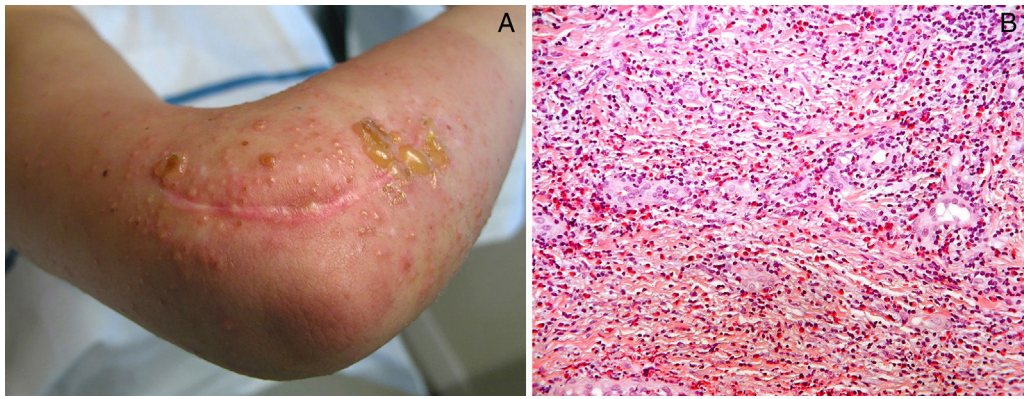


Figure 3 A, Multiple vesicles and blisters in the area irradiated to treat an epithelioid peripheral nerve sheath tumor. B, Dense, highly eosinophilic inflammatory infiltrate (hematoxylin-eosin, original magnification $\times 100$).

keratinocytes or other signs of erythema multiforme are not found. Direct immunofluorescence only shows occasional superficial perivascular IgM and C3 deposits, but this finding is common in many inflammatory skin disorders.

A blood work-up occasionally reveals high levels of circulating eosinophils, but this finding is not characteristic. In fact, high concentrations of eosinophils in association with tumors is a well known observation⁴³ and may be merely a casual finding in the context of EPPER syndrome.

This condition usually resolves spontaneously.

Sclerodermiform-like Panniculitis After Radiation

Another name for sclerodermiform-like panniculitis after radiation is sclerosing postirradiation panniculitis. This uncommon form of panniculitis presents as a progressive induration of subcutaneous tissue confined to the irradiated zone. Associated epidermal effects are not seen. This condition has been described in women with breast cancer treated with radiotherapy.^{44,45} The interval between irradiation and cutaneous sclerosis is usually 4 to 8 months, but cases have been said to develop even 7 years after radiotherapy. However, even though onset may be late, the typical signs of chronic radiodermatitis are not present. Suspicion often initially points to local recurrence of a tumor or subcutaneous metastasis.

Histology shows the characteristic features of a predominantly lobular panniculitis without vasculitis.⁴⁶ Lobules

contain necrotic adipocytes and a dense inflammatory infiltrate of foamy histiocytes (Fig. 4). Lipophagic granulomas in the form of histiocytes surrounding necrotic fat cells may be present. Also found are thickened, sclerotic-appearing septa without an associated inflammatory infiltrate.

No specific treatment is available for this condition, which gradually improves spontaneously.

Skin Conditions Triggered or Exacerbated by Radiotherapy

Isoradiotoxic Response

It has been suggested that various skin conditions that emerge in previously irradiated fields may result from a Koebner phenomenon or a Koebner-like isoradiotoxic response. However, the existence of a variable latency period between radiotherapy and the skin condition along with the absence of a Koebner phenomenon in some of these dermatoses under normal conditions has led some to assert that we are dealing with a distinct entity, namely an isoradiotoxic response.⁴⁷ Such a response would be a phenomenon exclusively linked to the ionizing radiation of radiotherapy, after which diverse, poorly understood mechanisms trigger a variety of dermatoses in the irradiated

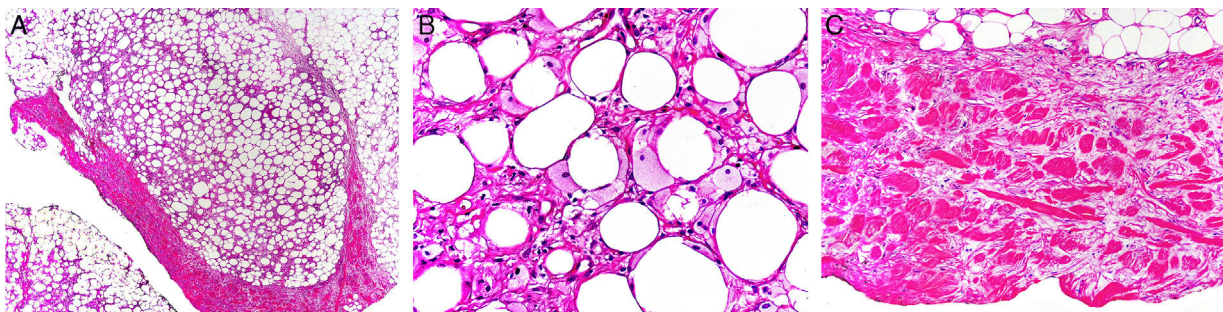


Figure 4 A, Predominantly lobular panniculitis (hematoxylin-eosin, original magnification $\times 100$). B, Foamy histiocytes surrounding fat cells (hematoxylin-eosin, original magnification $\times 400$). C, Sclerosis and thickening of hypodermal septa (hematoxylin-eosin, original magnification $\times 100$).

Images provided by Dr. Luis Requena Caballero.

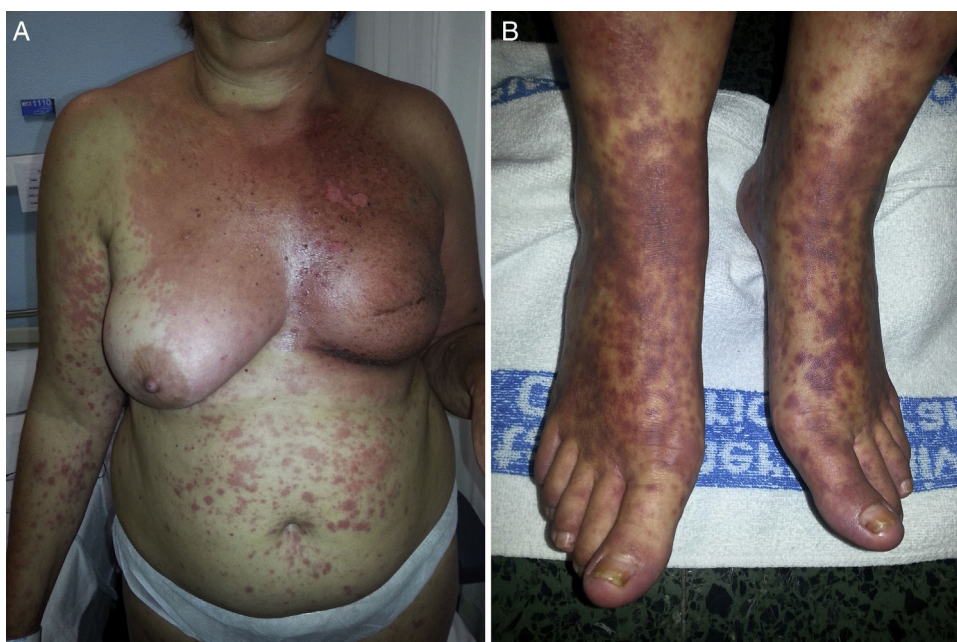

Figure 5 A, Erythema multiforme initially confined mainly to the field irradiated for breast cancer. B, The eruption later spread, forming atypical target lesions.

fields. We will now describe some of these radiation-induced dermatoses.

Erythema multiforme, Stevens–Johnson Syndrome, and Postradiation Toxic Epidermal Necrolysis

Ionizing radiation can induce skin disorders across the spectrum comprised of erythema multiforme, Stevens–Johnson syndrome, and toxic epidermal necrolysis. We summarize a recent review of 165 cases reported up to 2011,⁴⁸ most of which met the criteria for erythema multiforme. A high percentage of the cases in this group were not associated with drugs or other known triggers. However, cases grouped in the Stevens–Johnson syndrome and toxic epidermal necrolysis categories did have clear associations with such triggers.

The culprit medications were most often antiepileptic drugs (mainly phenytoin and phenobarbital). Amifostine was the next most frequently implicated drug.

The first sign is typically a maculopapular rash that is initially confined to the irradiated zone but later spreads beyond it^{48,49} (Table 4, Fig. 5).

Presentations of the Stevens–Johnson or toxic epidermal necrolysis types have occasionally been reported to stay within the irradiated field.⁵⁰

The median time elapsing between radiotherapy and the appearance of the rash is 28 days, but longer intervals have been reported when there is no drug trigger.⁴⁸

A subgroup of patients develop the so-called EMPACT syndrome (referring to erythema multiforme associated with phenytoin and cranial radiation therapy).⁵¹ In these cases, the disease has metastasized to the brain and concomitant treatment with phenytoin and cranial radiotherapy is required. In all described cases the patients developed an erythema multiforme reaction that began in the irradiated cranial zone and later spread to the rest of the body.

Radiotherapy and an antiepileptic drug are cofactors, evidenced by the fact that reintroduction of the drug by itself does not restart the skin reaction.

Pathophysiology has identified a wide-ranging group of drugs metabolized by cytochrome P450 3A that give rise to a series of reactive metabolites that are normally eliminated by enzymes like epoxide hydrolase and glutathione S-transferase. Ionizing radiation possibly causes an enzyme reaction and consequent accumulation of reactive metabolites, which will act as haptens, unleashing a hypersensitivity reaction.⁵² If these syndromes develop, the first step is to identify the most likely culprit drug and start symptomatic treatment or support therapy if required.

Radiation-Induced Autoimmune Blistering Diseases

Over 30 cases of bullous pemphigoid triggered by radiotherapy have been reported.⁵³ Most blistering diseases begin with eruptions in the irradiated field (Fig. 6) and may later spread farther.⁵⁴ This condition has largely been described in women who have been treated for breast cancer⁵⁵; the mean age is 75 years. An interesting fact is that onset is often a year after radiotherapy ended, although some reactions have developed during or immediately after therapy.

The pathophysiologic mechanism remains unclear, although the formation of antibodies, radioinduced changes in vascular permeability, and the use of tamoxifen have been suggested causes.⁵³

Histologic features include the characteristic subepidermal blisters with IgG and C3 deposition and elevated BP180 and BP230 titers on indirect immunofluorescence.

Pemphigus vulgaris is observed somewhat less often than radiation-induced bullous pemphigoid.⁵⁶ In both conditions, flaccid blisters and erosion begin to appear in the irradiated zone and later spread beyond it. The latency period between

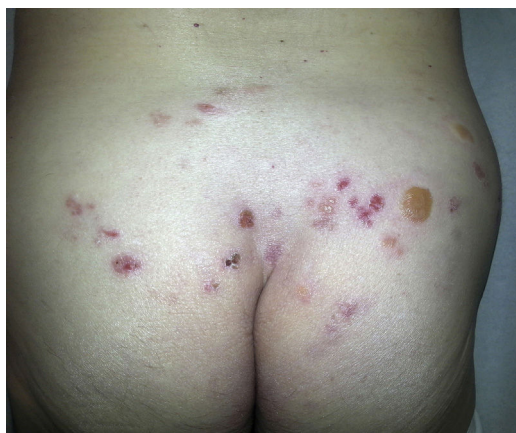

Figure 6 Multiple tense, serous blisters in the irradiated field compatible with radioinduced bullous pemphigoid.

radiotherapy and the cutaneous eruption varies from a week to a year. Histologic and immunopathologic features are the same, although additional findings in pemphigus vulgaris include areas of necrotic keratinocytes (a finding that is more common in paraneoplastic pemphigus) and reactivity to a keratinocytic antigen (110 kDa) demonstrated by Western blot.⁵⁶ Radiation-induced pemphigus vulgaris reactions usually respond well to conventional systemic corticosteroid or other immunosuppressant treatment.

Isolated cases of radiation-induced pemphigus foliaceus⁵⁷ and paraneoplastic pemphigus⁵⁸ have also been described.

Radiation-Induced Lichen Planus

Lichen planus appearing exclusively in a previously irradiated field is rare.⁵⁹

This complication develops within 3 months of the completion of radiotherapy generally in patients without a history of lichen planus.⁶⁰ Polygonal, erythematous-violaceous papules develop in the irradiated field but may also affect other areas.⁶¹ The lesions respond well to high-potency topical corticosteroids.

The role of radiotherapy may involve changes in the cutaneous barrier with the expression of autoantigens and antigenic peptides in keratinocytes, which would be recognized by the CD8 cytotoxic lymphocytes that are fundamental in the pathogenesis of lichen planus. These changes, in addition to the release of numerous cytokines, such as IL-1, IL-6, TNF and TGF- β 1, and the release of extracellular matrix metalloproteinases that damage the basement membrane.⁶¹

Radiation-Induced Morphea

A recent review of the literature, published in 2014, found 66 cases of radiation-induced morphea.⁶² Similarly to sclerodermiform-like panniculitis, this complication of radiotherapy has been reported most often in patients with breast cancer, although it has also been described in the context of other tumors.⁶² The typical presentation is an erythematous patch that gradually hardens (Fig. 7). Although the eruption is usually confined to the irradiated field, unlike

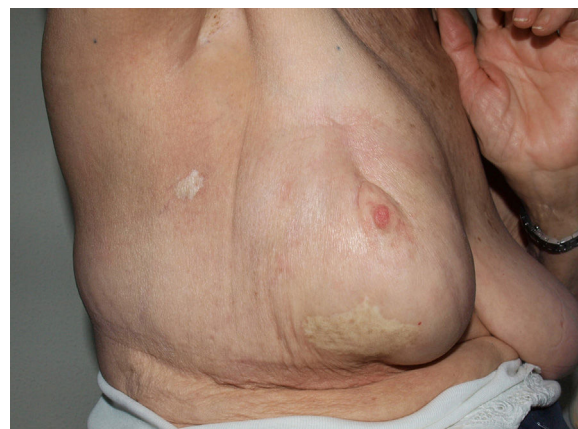

Figure 7 Radiation-induced morphea in a patient with a history of cancer in the right breast. Photograph provided by Dr. José Antonio Avilés Izquierdo.

sclerosing panniculitis it may spread beyond, particularly to the extremities.⁶³ It does not progress to systemic disease, but sclerosis does lead to functional limitations. The interval between irradiation and the cutaneous symptoms ranges from weeks to years, although it most often appears within a year of therapy.⁶²

Present are the typical histologic findings of idiopathic morphea: a lymphohistiocytic dermal infiltrate along with thickening and sclerosis of dermal collagen.

The pathophysiologic mechanism could be damage to fibroblasts and expression of neoantigens initially caused by radiation. These antigens would eventually be recognized by B and T cells, triggering creation of a proinflammatory environment with release of cytokines and activation of fibroblasts along with increased production of collagen.⁶² TGF- β also appears to play an important role.⁶²

The induration may improve spontaneously but, like idiopathic morphea, the radiation-induced form presents therapeutic challenges. When topical tacrolimus does not improve the symptoms, treating physicians have resorted to photodynamic therapy (psoralen-UV-A therapy or UV-B phototherapy with acitretin)⁶⁴ as well as methotrexate and tetracyclines.

Other Radiation-Induced Skin Conditions

The literature includes anecdotal reports of radiation-induced lupus erythematosus,⁶⁵ Sweet syndrome,⁶⁶ milium cysts,⁶⁷ and lichen sclerosus et atrophicus.⁶⁸

Ethical Disclosures

Protection of human and animal subjects. The authors declare that no experiments were performed on humans or animals for this investigation.

Data confidentiality. The authors declare that they followed their hospitals' regulations regarding the publication of patient information and that written informed consent for voluntary participation was obtained for all patients.

Right to privacy and informed consent

The authors have obtained the informed consent of the patients and/or subjects referred to in this article. The signed forms are in the possession of the corresponding author.

Conflicts of Interest

The authors declare that they have no conflicts of interest.

Acknowledgments

We are grateful for the cooperation of the radiation oncology department of Hospital General Universitario Gregorio Marañón and for photographs provided by physicians mentioned in figure captions.

References

- Bolderston A, Lloyd NS, Wong RKS, Holden L, Robb-Blenderman L. Supportive care guidelines group of cancer care ontario program in evidence-based care. The prevention and management of acute skin reactions related to radiation therapy: A systematic review and practice guideline. *Support Care Cancer*. 2006;14:802–17.
- Berrington de Gonzalez A, Curtis RE, Kry SF, Gilbert E, Lamart S, Berg CD, et al. Proportion of second cancers attributable to radiotherapy treatment in adults: A cohort study in the US SEER cancer registries. *Lancet Oncol*. 2011;12:353–60.
- Armengot-Carbó M, Roca-Estellés MJ, Quecedo-Estébanez E, Gimeno-Carpio E. Angiosarcoma of the skin after breast cancer radiotherapy. *Actas Dermosifiliogr*. 2012;103:557–9.
- Brenn T, Fletcher CDM. Radiation-associated cutaneous atypical vascular lesions and angiosarcoma: Clinicopathologic analysis of 42 cases. *Am J Surg Pathol*. 2005;29:983–96.
- Rao AG. Acquired lymphangiectasis following surgery and radiotherapy of breast cancer. *Indian J Dermatol*. 2015;60:106.
- Hymes SR, Strom EA, Fife C. Radiation dermatitis: Clinical presentation, pathophysiology, and treatment. *J Am Acad Dermatol*. 2006;54:28–46.
- CTC v2.0 and common terminology criteria for adverse events v4.0 (CTCAE). [cited 2016 Feb 20]. Available from: https://evs.nci.nih.gov/ftp1/CTCAE/CTCAE_4.03_2010-06-14_QuickReference_5x7.pdf
- Bernier J, Bonner J, Vermorken JB, Bensadoun R-J, Dummer R, Giralt J, et al. Consensus guidelines for the management of radiation dermatitis and coexisting acne-like rash in patients receiving radiotherapy plus EGFR inhibitors for the treatment of squamous cell carcinoma of the head and neck. *Ann Oncol*. 2008;19:142–9.
- Bar-Ad V, Zhang QE, Harari PM, Axelrod R, Rosenthal DI, Trotti A, et al. Correlation between the severity of cetuximab-induced skin rash and clinical outcome for head and neck cancer patients: The RTOG experience. *Int J Radiat Oncol Biol Phys*. 2016;95:1346–54.
- Malkinson FD, Hanson WR. Radiobiology of the skin. In: Goldsmith L, editor. *Physiology, biochemistry and molecular biology of the skin*, Vol II. Oxford (UK): Oxford University Press; 1991. p. 976.
- Janko M, Ontiveros F, Fitzgerald TJ, Deng A, DeCicco M, Rock KL. IL-1 generated subsequent to radiation-induced tissue injury contributes to the pathogenesis of radiodermatitis. *Radiat Res*. 2012;178:166–72.
- Denham JW, Hauer-Jensen M. The radiotherapeutic injury—a complex ‘wound’. *Radiother Oncol*. 2002;63:129–45.
- Hopewell JW. The skin: Its structure and response to ionizing radiation. *Int J Radiat Biol*. 1990;57:751–73.
- Edwards EKJr, Edwards EKJSr. The effect of superficial x-radiation on epidermal Langerhans cells in human skin. *Int J Dermatol*. 1990;29:731–2.
- Archambeau JO, Pezner R, Wasserman T. Pathophysiology of irradiated skin and breast. *Int J Radiat Oncol Biol Phys*. 1995;31:1171–85.
- Wong RKS, Bensadoun R-J, Boers-Doets CB, Bryce J, Chan A, Epstein JB, et al. Clinical practice guidelines for the prevention and treatment of acute and late radiation reactions from the MASCC Skin Toxicity Study Group. *Support Care Cancer*. 2013;21:2933–48.
- Watson LC, Gies D, Thompson E, Thomas B. Randomized control trial: Evaluating aluminum-based antiperspirant use, axilla skin toxicity, and reported quality of life in women receiving external beam radiotherapy for treatment of Stage 0, I, and II breast cancer. *Int J Radiat Oncol Biol Phys*. 2012;83:e29–34.
- Bostrom A, Lindman H, Swartling C, Berne B, Bergh J. Potent corticosteroid cream (mometasone furoate) significantly reduces acute radiation dermatitis: Results from a double-blind, randomized study. *Radiother Oncol*. 2001;59:257–65.
- Dunst J, Semlin S, Pigorsch S, Müller AC, Reese T. Intermittent use of amifostine during postoperative radiochemotherapy and acute toxicity in rectal cancer patients. *Strahlenther Onkol*. 2000;176:416–21.
- Cox JD, Stetz J, Pajak TF. Toxicity criteria of the Radiation Therapy Oncology Group (RTOG) and the European Organization for Research and Treatment of Cancer (EORTC). *Int J Radiat Oncol Biol Phys*. 1995;31:1341–6.
- Turesson I, Nyman J, Holmberg E, Oden A. Prognostic factors for acute and late skin reactions in radiotherapy patients. *Int J Radiat Oncol Biol Phys*. 1996;36:1065–75.
- Schultze-Mosgau S, Wehrhan F, Grabenbauer G, Amann K, Radespiel-Troger M, Neukam FW, et al. Transforming growth factor beta1 and beta2 (TGFbeta2/TGFbeta2) profile changes in previously irradiated free flap beds. *Head Neck*. 2002;24:33–41.
- Harper JL, Franklin LE, Jenrette JM, Aguero EG. Skin toxicity during breast irradiation: Pathophysiology and management. *South Med J*. 2004;97:989–93.
- Lanigan SW, Joannides T. Pulsed dye laser treatment of telangiectasia after radiotherapy for carcinoma of the breast. *Br J Dermatol*. 2003;148:77–9.
- Delanian S, Balla-Mekias S, Lefaix JL. Striking regression of chronic radiotherapy damage in a clinical trial of combined pentoxifylline and tocopherol. *J Clin Oncol*. 1999;17:3283–90.
- Delanian S, Baillet F, Huart J, Lefaix JL, Maulard C, Housset M. Successful treatment of radiation-induced fibrosis using liposomal Cu/Zn superoxide dismutase: Clinical trial. *Radiother Oncol*. 1994;32:12–20.
- Gottlober P, Steinert M, Bahren W, Weber L, Gerngross H, Peter RU. Interferon-gamma in 5 patients with cutaneous radiation syndrome after radiation therapy. *Int J Radiat Oncol Biol Phys*. 2001;50:159–66.
- Burriss HA, Hurtig J. Radiation recall with anticancer agents. *Oncologist*. 2010;15:1227–37.
- Mayer EG, Poulter CA, Aristizabal SA. Complications of irradiation related to apparent drug potentiation by adriamycin. *Int J Radiat Oncol Biol Phys*. 1976;1:1179–88.
- Extermann M, Vogt N, Forni M, Dayer P. Radiation recall in a patient with breast cancer treated for tuberculosis. *Eur J Clin Pharmacol*. 1994;48:77–8.
- Bostrom A, Sjolín-Forsberg G, Wilking N, Bergh J. Radiation recall: Another call with tamoxifen. *Acta Oncol*. 1999;38:955–9.

32. Garza LA, Yoo EK, Junkins-hopkins JM, VanVoorhees AS. Photo recall effect in association with cefazolin. *Cutis*. 2004;73:79–85.
33. Abadir R, Liebmann J. Radiation reaction recall following simvastatin therapy: A new observation. *Clin Oncol*. 1995;7:325–6.
34. Yeo W, Leung SF, Johnson PJ. Radiation-recall dermatitis with docetaxel: Establishment of a requisite radiation threshold. *Eur J Cancer*. 1997;33:698–9.
35. Azria D, Magné N, Zouhair A, Castadot P, Culine S, Ychou M, et al. Radiation recall: A well recognized but neglected phenomenon. *Cancer Treat Rev*. 2005;31:555–70.
36. Smith KJ, Germain M, Skelton H. Histopathologic features seen with radiation recall or enhancement eruptions. *J Cutan Med Surg*. 2002;9:9.
37. Seymour CB, Mothersill C, Alper T. High yields of lethal mutations in somatic mammalian cells that survive ionizing radiation. *Int J Radiat Biol*. 1986;50:167–79.
38. Nemecek PM, Corder MC. Radiation recall associated with vinblastine in a patient treated for Kaposi sarcoma related to acquired immune deficiency syndrome. *Cancer*. 1992;70:1605–6.
39. Camidge R, Price A. Characterizing the phenomenon of radiation recall dermatitis. *Radiother Oncol*. 2001;59:237–45.
40. Rueda RA, Valencia IC, Covelli C, Escobar C, Alzate A, Saldarriaga B, et al. Eosinophilic, polymorphic, and pruritic eruption associated with radiotherapy. *Arch Dermatol*. 1999;135:804–10.
41. Gallego H, Crutchfield CE, Wilke MS, Lewis EJ. Delayed EPPER syndrome. *Arch Dermatol*. 2001;137:821–2.
42. Lee DJ, Kim YC. A pustular form of eosinophilic, polymorphic, and pruritic eruption associated with radiotherapy. *J Am Acad Dermatol*. 2011;65:e51–3.
43. Lowe D, Jorizzo J, Hutt MSR. Tumor-associated eosinophilia: a review. *J Clin Pathol*. 1981;34:1343–8.
44. Requena L, Ferrándiz C. Sclerosing postirradiation panniculitis. *Dermatol Clin*. 2008;26:505–8.
45. Winkelmann RK, Grado GL, Quimby S, Connolly SM. Pseudosclerodermatous panniculitis after irradiation: An unusual complication of megavoltage treatment of breast carcinoma. *Mayo Clin Proc*. 1993;68:122–7.
46. Pielasinski U, Machan S, Camacho D, Juárez A, Cedeño M, Maciá JAR, et al. Postirradiation pseudosclerodermatous panniculitis: Three new cases with additional histopathologic features supporting the radiotherapy etiology. *Am J Dermatopathol*. 2013;35:129–34.
47. Shurman D, Reich HL, James WD. Lichen planus confined to a radiation field: The isoradiotopic response. *J Am Acad Dermatol*. 2004;50:482–3.
48. Vern-Gross TZ, Kowal-Vern A. Erythema multiforme, Stevens Johnson syndrome, and toxic epidermal necrolysis syndrome in patients undergoing radiation therapy: A literature review. *Am J Clin Oncol*. 2014;37:506–13.
49. Yoshitake T, Nakamura K, Shioyama Y, Sasaki T, Ooga S, Abe M, et al. Erythema multiforme and Stevens-Johnson syndrome following radiotherapy. *Radiat Med*. 2007;25:27–30.
50. Hafiji J, Orpin S, Roberts C, Heagerty A, Lewis H. Radiotherapy: A protective role for toxic epidermal necrolysis. *Br J Dermatol*. 2010;162:1139–41.
51. Ahmed I, Reichenberg J, Lucas A, Shehan JM. Erythema multiforme associated with phenytoin and cranial radiation therapy: A report of three patients and review of the literature. *Int J Dermatol*. 2004;43:67–73.
52. Vittorio CC, Muglia JJ. Anticonvulsant hypersensitivity syndrome. *Arch Intern Med*. 1995;155:2285–90.
53. Mul VEM, van Geest AJ, Pijls-Johannesma MCG, Theys J, Verschuere TAM, Jager JJ, et al. Radiation-induced bullous pemphigoid: A systematic review of an unusual radiation side effect. *Radiother Oncol*. 2007;82:5–9.
54. Parikh SK, Ravi A, Kuo DY, Nori D. Bullous pemphigoid masquerading as acute radiation dermatitis: Case report. *Eur J Gynaecol Oncol*. 2001;22:322–4.
55. Isohashi F, Konishi K, Umegaki N, Tanei T, Koizumi M, Yoshioka Y. A case of bullous pemphigoid exacerbated by irradiation after breast conservative radiotherapy. *Jpn J Clin Oncol*. 2011;41:811–3.
56. Badri T, Hammami H, Lachkham A, Benmously-Mlika R, Mokhtar I, Fenniche S. Radiotherapy-induced pemphigus vulgaris with autoantibodies targeting a 110 kDa epidermal antigen. *Int J Dermatol*. 2011;50:1475–9.
57. Cianchini G, Lembo L, Colonna L, Puddu P. Pemphigus foliaceus induced by radiotherapy and responsive to dapsone. *J Dermatol*. 2006;17:244–6.
58. Lee MS, Kossard S, Ho KKL, Barnetson RS, Ravich RB. Paraneoplastic pemphigus triggered by radiotherapy. *Australas J Dermatol*. 1995;36:206–10.
59. Pretel M, España A. Lichen planus induced by radiotherapy. *Clin Exp Dermatol*. 2007;32:582–3.
60. Sajgane AA, Dongre AM. Radiotherapy-induced koebnerization in lichen planus. *Indian J Dermatol Venereol Leprol*. 2012;78:665.
61. Morar N, Francis ND. Generalized lichen planus induced by radiotherapy: Shared molecular mechanisms. *Clin Exp Dermatol*. 2009;34:e434–5.
62. Spalek M, Jonska-Gmyrek J, Gatecki J. Radiation-induced morphea—a literature review. *J Eur Acad Dermatol Venereol*. 2015;29:197–202.
63. Kushi J, Csuka ME. Generalized morphea after breast cancer radiation therapy. *Case Rep Rheumatol*. 2011;2011:951948.
64. Newland K, Marshman G. Successful treatment of post-irradiation morphea with acitretin and narrowband UVB. *Australas J Dermatol*. 2012;53:136–8.
65. Balabanova MB, Botev IN, Michailova JI. Subacute cutaneous lupus erythematosus induced by radiation therapy. *Br J Dermatol*. 1997;137:648–9.
66. Wanat KA, Kovarik CL, Quon H, Miller CJ. Sweet syndrome in a field of radiation therapy. *J Am Acad Dermatol*. 2012;67:e284–6.
67. Pisauri AM, Alvarez-Gracia A, Ferrandiz-Foraster C, Bassas-Vila J. Milia en placa en la cara posterior de ambos pabellones auriculares secundaria a radioterapia. *Actas Dermosifiliogr*. 2016;107:156–8.
68. Vujovic O. Lichen sclerosus in a radiated breast. *CMAJ*. 2010;182:E860.