



ACTAS Derma-Sifiliográficas

Full English text available at
www.actasdermo.org



CASE AND RESEARCH LETTERS

Relapse of morphea during Nivolumab therapy for lung adenocarcinoma



Recaída de morfea durante tratamiento con Nivolumab en adenocarcinoma de pulmón

Dear Editor

Nivolumab is a Programmed Death-1 (PD1) receptor (PD-1) inhibitor, first approved as cancer immune-checkpoint inhibitor therapy for stage IV malignant melanoma, with recent indications in different tumors such as non-small cell lung cancer, prostate cancer, renal-cell cancer or ovarian cancer. A wide variety of skin reactions have been described associated to cancer immunotherapy.¹⁻⁷ We present a case of morphea relapsing during Nivolumab treatment.

A 65 year-old woman came to our clinic referred by the Oncology department of our hospital. She was being followed due to a stage IV lung adenocarcinoma for which she had received different therapies. Just 2 months after initiating treatment with Nivolumab (3 mg/kg every 2 weeks), she developed cutaneous lesions on the trunk. On the physical examination she presented three patches: one on each breast, and one on the left inframammary fold (Fig. 1). These lesions had a shiny white color with a discrete lilaceous ring. To the touch, they presented as clearly atrophic. She reported occasional itching but no other symptoms. The patient had a past medical history of morphea 8 years before (histologically diagnosed), having been treated with topical corticosteroids and oral methotrexate, with remission of the disease for more than 6 years. Postinflammatory hyperpigmentation was not detected.

A skin biopsy of one of the patches was performed. Histological examination demonstrated findings of lichen sclerosus with underlying morphea (Fig. 2). Nivolumab was stopped after 6 months of treatment because of the lack of efficacy in oncological terms. In subsequent visits to our clinics, the patient showed improvement of her cutaneous lesions, without any topical or systemic treatment.

Relapse of morphea has been described in 50% of patients in the first 2 years after diagnosis.⁸ In the presented case, more than 6 years had passed since the last exacerbation of morphea, and this episode of relapsing happened only 2 weeks after initiating Nivolumab. Although natural evolution of the disease may have played a role, we considered Nivolumab as a possible trigger.

Many other medications have been associated with the development of morphea. The formation of autoantibodies and subsequent microvasculature injury has been proposed in the pathogenesis of these cases of drug-induced morphea.⁹

In different clinical trials, anti-PD1 therapies such as Pembrolizumab or Nivolumab showed a relatively safe profile, with a low incidence of major adverse effects (drug-related grade 3 or 4 toxic effects only in 14% of the patients), being those related with pneumonitis the most severe of them.¹⁰ These adverse reactions related with immune-checkpoints inhibitors have been named as immune-related adverse events (irAEs). When focusing on the skin irAEs, non-specific macular papular rash and pruritus have

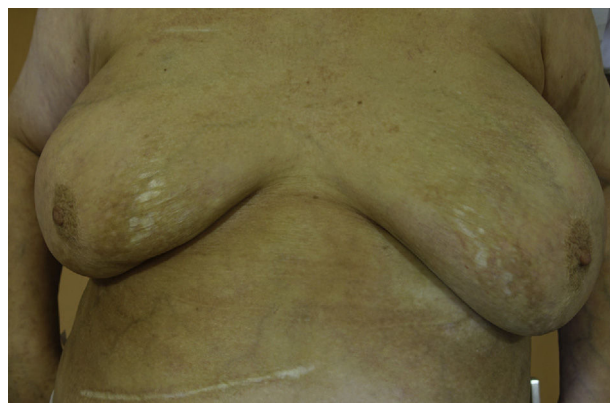

Figure 1 Patches in both breasts and left inframammary fold, showing a shiny white color, lilaceous ring and atrophic surface.

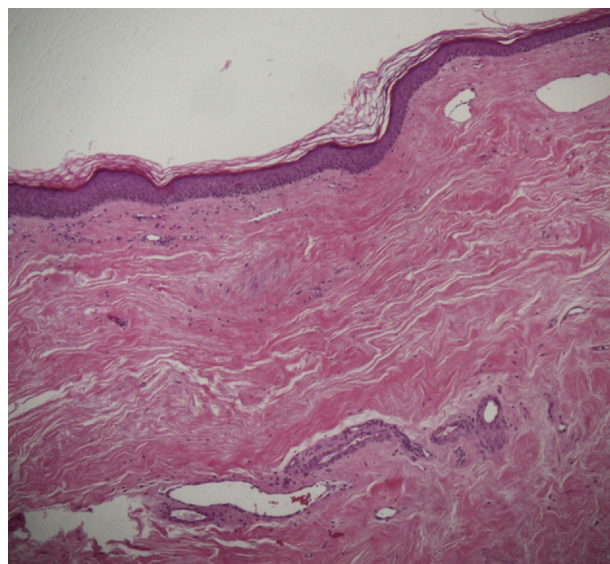


Figure 2 Histopathology (HE ×10): thickened collagen bundles in dermis, closely packed. Epidermal atrophy. Discrete perivascular lymphocytic infiltrate.

been described as the most common ones. Interestingly, vitiligo has also been reported, but only in patients with melanoma. Urticaria, alopecia and mucosal involvement are other frequently described skin irAEs.¹⁻⁴

The exacerbation of preexisting autoimmune disorders related to immunotherapies has also been reported. These disorders include psoriasis, sarcoidosis, bullous pemphigoid and subacute

lupus erythematosus.⁵⁻⁷ To the best of our knowledge, this would be the first case of morphea relapsing due to any cancer immunotherapy treatment.

In conclusion, attending to the nature of this kind of immunotherapies, totally different from traditional chemotherapy, dermatologists should be aware not only of their typical irAEs, but also of the possibility of exacerbation or relapse of previously controlled skin diseases, especially immune-related ones. This will probably represent a new challenge for dermatologists in the future, as these treatments are being used more and more often. More experience is needed in order to conclude the exact relation of cancer immunotherapy and the relapse of these diseases.

Conflict of interests

The authors declare no conflict of interest.

Acknowledgement

A C. M. García del Real for his collaboration.

References

1. Topalian SL, Hodi FS, Brahmer JR, Gettinger SN, Smith DC, McDermott DF, et al. Safety, activity, and immune correlates of anti-PD-1 antibody in cancer. *N Engl J Med*. 2012;366:2443–54.
 2. Macdonald JB, Macdonald B, Golitz LE, LoRusso P, Sekulic A. Cutaneous adverse effects of targeted therapies: Part II: inhibitors of intracellular molecular signaling pathways. *J Am Acad Dermatol*. 2015;72:221–36, quiz 237–8.
 3. Sibaud V, Meyer N, Lamant L, Vigaros E, Mazieres J, Delord JP. Dermatologic complications of anti-PD-1/PD-L1 immune checkpoint antibodies. *Curr Opin Oncol*. 2016;28:254–63.
 4. Belum VR, Benhuri B, Postow MA, Hellmann MD, Lesokhin AM, Segal NH, et al. Characterisation and management of dermatologic adverse events to agents targeting the PD-1 receptor. *Eur J Cancer*. 2016;60:12–25.
 5. Johnson DB, Sullivan RJ, Ott PA, Carlino MS, Khushalani NI, Ye F, et al. Ipilimumab therapy in patients with advanced melanoma and preexisting autoimmune disorders. *JAMA Oncol*. 2016;2:234–40.
 6. Kato Y, Otsuka A, Miyachi Y, Kabashima K. Exacerbation of psoriasis vulgaris during Nivolumab for oral mucosal melanoma. *J Eur Acad Dermatol Venereol*. 2015.
 7. Matsumura N, Ohtsuka M, Kikuchi N, Yamamoto T. Exacerbation of psoriasis during Nivolumab therapy for metastatic melanoma. *Acta Derm Venereol*. 2016;96:259–60.
 8. Fett N, Werth VP. Update on morphea: part I. Epidemiology, clinical presentation, and pathogenesis. *J Am Acad Dermatol*. 2011;64:217–28, quiz 229–30.
 9. Peroni A, Zini A, Braga V, Colato C, Adami S, Girolomoni G. Drug-induced morphea: report of a case induced by balicitib and review of the literature. *J Am Acad Dermatol*. 2008;59:125–9.
 10. Nishino M, Sholl LM, Hodi FS, Hatabu H, Ramaiya NH. Anti-PD-1-related pneumonitis during cancer immunotherapy. *N Engl J Med*. 2015;373:288–90.
- A. Alegre-Sánchez,* P. Fonda-Pascual, D. Saceda-Corralo, E. de las Heras-Alonso
- Dermatology Service, Ramon y Cajal Hospital, Madrid, Spain*
- * Corresponding author.
E-mail address: adrian.alegresanchez@gmail.com (A. Alegre-Sánchez).
- 1578-2190/
© 2016 Elsevier España, S.L.U. and AEDV. All rights reserved.

Sweet's syndrome-like eruption in association with the exacerbation of Behçet's disease after the Great East Japan Earthquake



Erupción tipo síndrome de Sweet asociada al empeoramiento de la enfermedad de Behçet después del Gran terremoto de Japón oriental

Dear Editor:

We herein report a case of Behçet's disease (BD), which was stable until the Great East Japan Earthquake, but deteriorated thereafter and presented with Sweet's syndrome-like facial erythemas, along with exacerbation of other mucocutaneous conditions.

A 36-year-old male visited our hospital, complaining of fever, genital ulcer, folliculitis-like lesions, and erythema nodosum (Fig. 1a), and had been diagnosed previously with incomplete type BD six years ago. He received treatment with minocycline, colchicine, and his symptoms were under control. However, his

symptoms recurred along with a fever of up to 39°C and throat pain following the Great East Japan Earthquake in March 2011 when he was evacuated from home and placed at a shelter. Physical examination revealed multiple oral ulcers, folliculitis on the back, tender subcutaneous erythematous nodules on the knee, and tender infiltrative erythematous plaques with surface scales on the cheek, forehead, and neck (Fig. 1b and c). A biopsy specimen taken from his face showed dense neutrophil infiltration throughout the dermis (Fig. 2). Laboratory examination showed elevated levels of white blood cell counts (12,200/μl with 80% neutrophils), C-reactive protein (11.44 mg/dl), and erythrocyte sedimentation ratio (41 mm/h). Antistreptolysin O (ASO) level was within normal ranges. HLA typing was negative for HLA-B51, but positive for HLA-A2, A24, B54, and B62. He was successfully treated with oral prednisolone (20 mg/day).

The present case developed infiltrative erythemas on the face mimicking Sweet's syndrome, along with other cutaneous symptoms such as folliculitis and erythema nodosum. A biopsy specimen from the face revealed dense neutrophil infiltration throughout the dermis. Patients with BD rarely present with Sweet's syndrome-like infiltrative erythema.¹ On the other hand, several cases have been reported as a co-existence of BD and Sweet's syndrome; symptoms of Sweet's syndrome appear representing a flare or in