

Papular Acantholytic Dyskeratosis of the Vulva in a Woman With Benign Familial Pemphigus[☆]



Disqueratosis acantolítica papular de la vulva en una mujer con pénfigo benigno familiar

To the Editor:

We describe the case of a woman aged 50 years, with a history of systemic hypertension on treatment and benign familial pemphigus (BFP) that had arisen more than 10 years earlier. During those years, she had presented recurrent outbreaks of erosive lesions in the groin, perianal region, and submammary folds (Fig. 1), often with bacterial superinfection. She had received topical therapy with corticosteroids, antibiotics, tacrolimus, and diclofenac, with a partial response. She had also received systemic acitretin at a dose of 25 mg/d on several occasions. During a follow-up visit, perianal lesions suggestive of PBF were observed, and asymptomatic shiny whitish papules measuring 2 to 3 mm in diameter with a cobblestone appearance on both labia majora (Fig. 2). Biopsy of 1 of these vulvar lesions revealed hyperkeratosis with irregular acantholysis and suprabasal acantholysis with dyskeratosis (Fig. 3); direct immunofluorescence was negative.

Papular acantholytic dyskeratosis (PAD) of the vulva, first described in 1984 by Chorzeliski et al.,¹ mainly affects young women, typically on the labia majora, although it has also been described on the penis in men, in the anal canal, and in the inguinal folds.^{2,3} It usually presents as multiple whitish papules that may coalesce to form plaques; solitary papules are rare. Most commonly it is asymptomatic, although intense pruritus can occur. Histopathology reveals acantholysis with varying degrees of dyskeratosis, and direct and indirect immunofluorescence are negative in almost all cases studied.⁴ Though initially considered an independent entity, its relationship with Darier disease (DD) and with BFP has been under discussion due to the histologic similarity between the diseases.⁵ The etiology of PAD is unclear. The majority of cases are sporadic, but there have been reports in recent years of cases of DAP due to mutations in genes *ATP2A2*⁶ and *ATP2C1*,⁷⁻⁹ which are mutations

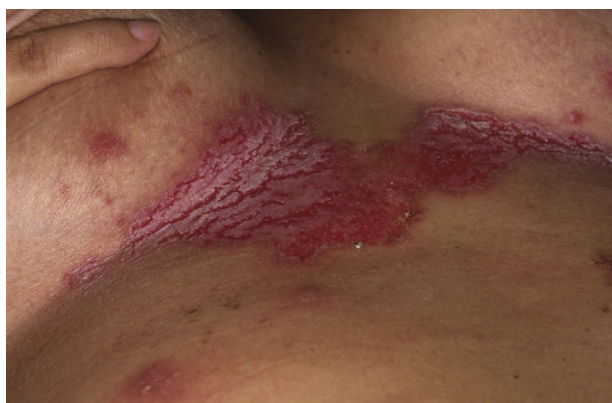

Figure 1 Erosive plaque in the submammary region, compatible with benign familial pemphigus.

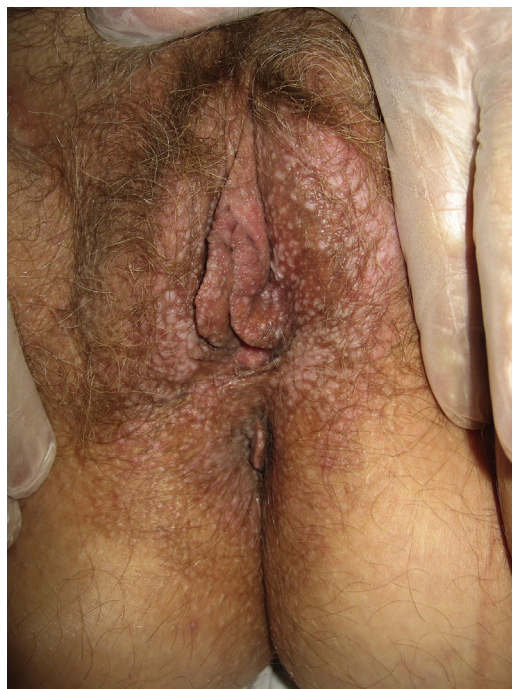

Figure 2 Multiple shiny whitish papules measuring 2 to 3 mm in diameter with a cobblestone appearance on the labia majora.

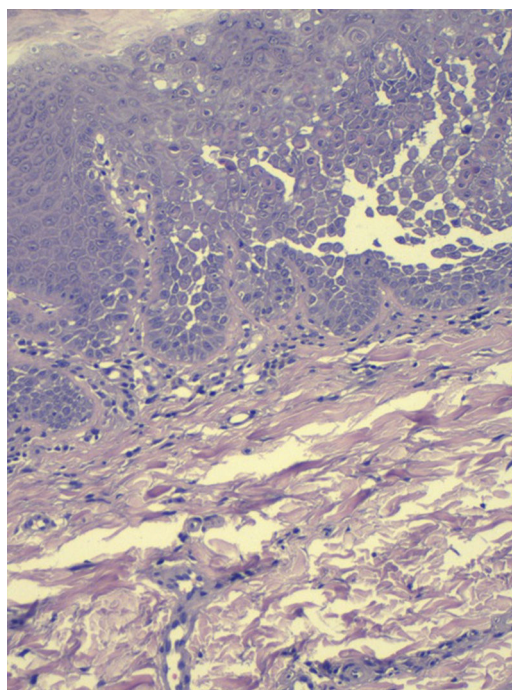


Figure 3 Punch biopsy of a vulvar papule showing an acantholytic intraepidermal papule with dyskeratosis. Hematoxylin and eosin, original magnification $\times 20$.

known in DD and BFP, respectively. Pernet et al.⁸ reported a familial case of PAD in which the same mutation in *ATP2C1* was detected in the mother and daughter, suggesting that PAD is allelic with BFP. Yu et al.⁹ published the case of a woman with PAD and a family history of BFP; those authors suggested the possibility that a patient with PAD may subsequently develop lesions of BFP and that the 2 diseases belonged to a common spectrum of genetically linked acantholytic

[☆] Please cite this article as: Baliu-Piqué C, Iranzo P. Disqueratosis acantolítica papular de la vulva en una mujer con pénfigo benigno familiar. *Actas Dermosifiliogr.* 2017;108:78-79.

dyskeratotic dermatoses. Genetic analysis remains to be performed in our patient, but the coexistence of PAD and BFP in the same patient supports this hypothesis.

We have described a patient with the simultaneous presence of lesions clinically and histologically typical of BFP and PAD; the study of mutations in both lesions remains to be performed. To date, we have found no case reports in the literature describing the coexistence of BFP and PAD in a single patient.

Conflicts of Interest

The authors declare that they have no conflicts of interest.

References

1. Chorzelski TP, Kudejko J, Jablonska S. Papular acantholytic dyskeratosis of the vulva a new entity? *Am J Dermatopathol*. 1984;6:557–60.
2. Van der Putte SCJ, Oey HB. Papular acantholytic dyskeratosis of the penis. *Am J Dermatopathol*. 1986;8:365–6.
3. Wakel RL, Jager RM. Focal acantholytic dyskeratosis of the anal canal. *Am J Dermatopathol*. 1986;4:362–3.
4. Günes AT, Ilknur T, Pabuçcuoğlu U, Lebe B, Altiner DD. Papular acantholytic dyskeratosis of the anogenital area with positive direct immunofluorescence results. *Clin Exp Dermatol*. 2007;32:301–3.
5. Montis-Palos MC, Acebo-Marinñas E, Catón-Santarén B, Soloeta-Arechavala R. Dermatitis acantolítica papular del área genitocrural: ¿forma localizada de Darier o Hailey-Haley? *Actas Dermosifiliogr*. 2013;104:170–2.
6. Knopp EA, Saraceni C, Moss J, McNiff JM, Choate KA. Somatic ATP2A2 mutation in a case of papular acantholytic dyskeratosis: Mosaic Darier disease. *J Cutan Pathol*. 2015;42:853–7.
7. Lipoff JB, Mudgil AV, Young S, Chu P, Cohen SR. Acantholytic dermatosis of the crural folds with ATP2C1 mutation is a possible variant of Hailey-Hailey disease. *J Cutan Med Surg*. 2009;13:151–4.
8. Pernet C, Bessis D, Savignac M, Tron E, Guillot B, Hovnanian A. Genitoperineal papular acantholytic dyskeratosis is allelic to Hailey-Hailey disease. *Br J Dermatol*. 2012;167:210–2.
9. Yu WY, Ng E, Hale C, Hu S, Pomeranz MK. Papular acantholytic dyskeratosis of the vulva associated with familial Hailey-Hailey disease. *Clin Exp Dermatol*. 2016;41:628–31.

C. Baliu-Piqué,* P. Iranzo

Servicio de Dermatología, Hospital Clínic, Universitat de Barcelona, Barcelona, Spain

* Corresponding author.

E-mail address: carola.baliu.pique@gmail.com

(C. Baliu-Piqué).

1578-2190/

© 2016 Elsevier España, S.L.U. and AEDV. All rights reserved.

Bullous Phytophotodermatitis Caused by an Esoteric Remedy[☆]



Fitofotodermatitis ampollosa producida por un remedio esotérico

To the Editor:

The patient was a 33-year-old woman with a past history of hypothyroidism, anorexia nervosa, and anxiety-depression with episodes of self-harm. She was on treatment with levothyroxine, fluoxetine, clonazepam, and clomethiazole, and there had been no recent changes in her medication. She attended the emergency department for a 3-day history of large, painful blisters on the dorsum of both hands and fingers (Fig. 1). The blisters contained a serous fluid and the surrounding skin was erythematous and pruritic. The patient denied having applied any substance to the area or contact with plants, and at that moment she was off work because of her psychiatric illness and dedicated her time to walking and reading outside, even though it was winter. The lesions were reminiscent of large burns and, suspecting that they may have been self-inflicted, it was decided to admit the patient to observe the clinical course. During her admission, she was prescribed topical therapy with fusidic acid and betamethasone, and oral therapy with prednisone and amoxicillin-clavulanic acid, leading to an improvement in the lesions within a few days. On resolution of the acute bullous condition, we observed very clearly defined, diffuse pigmentation of a residual appearance on the skin distal

to the wrists (Fig. 2), but that did not affect the area covered by a ring; this suggested a possible diagnosis of phototoxicity. Additional tests performed, including extensive blood tests with autoimmune studies and 24-hour urinary porphyrin levels, determination of the minimal erythematous dose for UV-A and UV-B, and patch and photopatch testing with the standard series of the Spanish Contact Dermatitis and Skin Allergy Research Group and photoallergens of the Spanish Photobiology Group, were rigorously normal. Histology of the lesions showed a subepidermal blister with epidermal necrosis. Occasional apoptotic keratinocytes were observed in areas adjacent to the blister and a dermal infiltrate of lymphocytes, histiocytes, and eosinophils, with a number of extravasated red blood cells were observed in areas adjacent to the blister; these findings were compatible with a diagnosis of bullous phototoxic dermatitis. On further questioning, the patient finally remembered having applied a product prepared by a faith healer to combat an evil-eye curse 24 to 36 hours prior to onset of the lesions. This remedy consisted of an infusion of a plant called *rue*, which the patient had to apply all over her body except on her head. The site of the lesions coincided with the only area that had not been covered by her winter clothing after applying the substance.

Plants of the genus *Ruta* are small bushes originating from southern Europe that are cultured as ornamental plants in gardens and also for their medicinal properties and as a condiment. Among their many effects (abortifacient, antiparasitic, insect repellent, analgesic, ...), they are widely known for their phototoxic capacity due to the furanocoumarins (5-methoxypsoralen and 8-methoxypsoralen) and alkaloids that they contains.¹ Numerous cases have been published of phytophotodermatitis due to the topical application of distinct species of *Ruta* for various therapeutic uses, such as pediculicide² or analgesic³ lotions, or direct use of the plant as an insect repellent.⁴ In most cases, the clinical diagnosis is simple because of the site of the lesions in

[☆] Please cite this article as: Córdoba S, González M, Martínez-Morán C, Borbujo JM. Fitofotodermatitis ampollosa producida por un remedio esotérico. *Actas Dermosifiliogr*. 2017;108:79–81.