

Management Survey in FY2011 and FY2012. *Fukushima J Med Sci.* 2014;60:57–67.

4. Calikoglu E, Onder M, Cosar B, Candansayar S. Depression, anxiety levels and general psychological profile in Behçet's disease. *Dermatology.* 2001;203:238–40.
5. Kartidag R, Unal S, Evereklioglu C, Sipahi B, Er H, Yologlu S. Stressful life events, anxiety, depression and coping mechanisms in patients with Behçet's disease. *J Eur Acad Dermatol Venereol.* 2003;17:670–5.

T. Miura, M. Ohtsuka, T. Yamamoto*

Department of Dermatology, Fukushima Medical University, Fukushima, Japan

* Corresponding author.

E-mail address: toyamade@fmu.ac.jp (T. Yamamoto).

1578-2190/

© 2016 Published by Elsevier España, S.L.U.

Congenital Plaque-type Glomovenous Malformation: 11 Years of Follow-up and Response to Treatment With the Combined Pulsed-Dye and Neodymium:Yttrium-Aluminum-Garnet Laser[☆]



Malformación glomovenosa congénita en placas: 11 años de seguimiento y respuesta al tratamiento con láser combinado PDL/Nd: YAG

To the Editor:

Glomovenous malformations (GVM), previously known as glomangiomas, show a familial tendency and are characterized histologically by the presence of vascular channels surrounded by a variable number of glomus cells. There is a rare form that presents as plaques. The treatment of these lesions has still not been standardized.

Our patient was a newborn boy from a twin pregnancy, born preterm at 34 weeks, with erythematous plaques present on his back since birth. There was no family history of similar lesions. On physical examination, nonpulsatile, depressed erythematous-violaceous plaques were observed on the boy's back (Fig. 1A). We performed skin biopsy to clarify our differential diagnosis of capillary malformation, multiple myofibromas, or subcutaneous fat necrosis. Histopathology showed an increased number of ectatic vessels in the dermis and was interpreted as a capillary malformation.

At 6 months, the plaques had acquired an annular pattern, with an erythematous halo, depressed blue-violaceous center, ectatic vessels, and flaccid skin (Fig. 1B).

A further biopsy, performed because of the lack of clinical-pathological correlation, revealed a dermis with vascular structures surrounded by several layers of monomorphic round cells with eosinophilic cytoplasm (Fig. 2A). Immunohistochemistry showed the perivascular glomus cells to be positive for vimentin and α -actin and negative for desmin and S100 (Fig. 2B). Based on these findings, we made a diagnosis of congenital plaque-type GVM.

Initially we took a wait-and-see approach. Over the following years, the plaques extended to the adjacent skin and took on a more atrophic appearance, with very dilated vessels. No new lesions appeared.

At 7 years of age, the lesions were still asymptomatic, but their appearance (Fig. 1C) negatively affected the patient's self-esteem, leading us to evaluate the treatment options. The size of the lesions limited a possible surgical intervention. It was decided to start treatment with combined pulsed dye (PDL) (595 nm) and neodymium-doped yttrium aluminium garnet (Nd:YAG) (1064 nm) lasers (Cynergy MultiplexTM, Cynosure, Westford, Massachusetts, United States), with a spot size of 10 mm, a PDL pulse duration of 0.5 ms and fluence of 8.5–9 J/cm², followed by a pulse of Nd:YAG with a duration of 15 ms and fluence of 50 J/cm². A cooling system was used simultaneously to prevent epidermal damage. The sessions were performed under general anesthesia every 2 or 3 months. The post-treatment recommendations included oral analgesia and photoprotection. At the time of writing, the patient has received 10 sessions of laser therapy, with lightening of the color of the lesions and a reduction in lesion volume and in the caliber of the vessels (Fig. 1D). Treatment has been well tolerated and no complications have been detected.

GVMs account for 5% of venous malformations (VM) and are distinct from sporadic VMs and from hereditary mucocutaneous VMs. A familial tendency is detected in 88%, with an autosomal dominant inheritance pattern and incomplete penetrance (90%). Their etiology has been related to mutations in the glomulin gene (*GLMN*).¹ GVMs are usually multiple and tend to appear at an early age. They can present as papular-nodular lesions or as plaques, and may be congenital² or acquired.³

Congenital plaque-type GVMs present clinically as bluish plaques with a cobblestone surface,¹ or as atrophic plaques with telangiectasias,^{2,4–9} as in our patient. A segmental distribution is often observed.⁵

Histology is characterized by a nonencapsulated proliferation of ectatic vascular channels surrounded by 1 or several layers of polygonal glomus cells. Immunohistochemistry is positive for α -smooth muscle actin and vimentin and negative for desmin.^{1–3}

The clinical course of plaque-type GVMs varies. Progressive thickening and darkening of the lesions has been reported, as well as a tendency to spread into adjacent unaffected areas,² as was seen in our patient.

The objectives of treatment of GVMs are to relieve pain and improve function and cosmetic appearance.^{6,7,9} Surgery is an option for small localized lesions. Treatments such as sclerotherapy and ablative therapy have been used in multiple or extensive GVMs, but results have not been consistent.¹⁰ There are also descriptions of cases treated with Nd:YAG laser with good results,⁹ and PDL lasers have been reported to be useful for the more superficial component of the lesions.⁶ The dual laser (PDL/Nd:YAG) allows us to treat different depths of the skin using lower fluences and thus

[☆] Please cite this article as: Vargas-Navia N, Baselga E, Muñoz-Garza FZ, Puig L. Malformación glomovenosa congénita en placas: 11 años de seguimiento y respuesta al tratamiento con láser combinado PDL/Nd: YAG. *Actas Dermosifiliogr.* 2017;108:72–74.

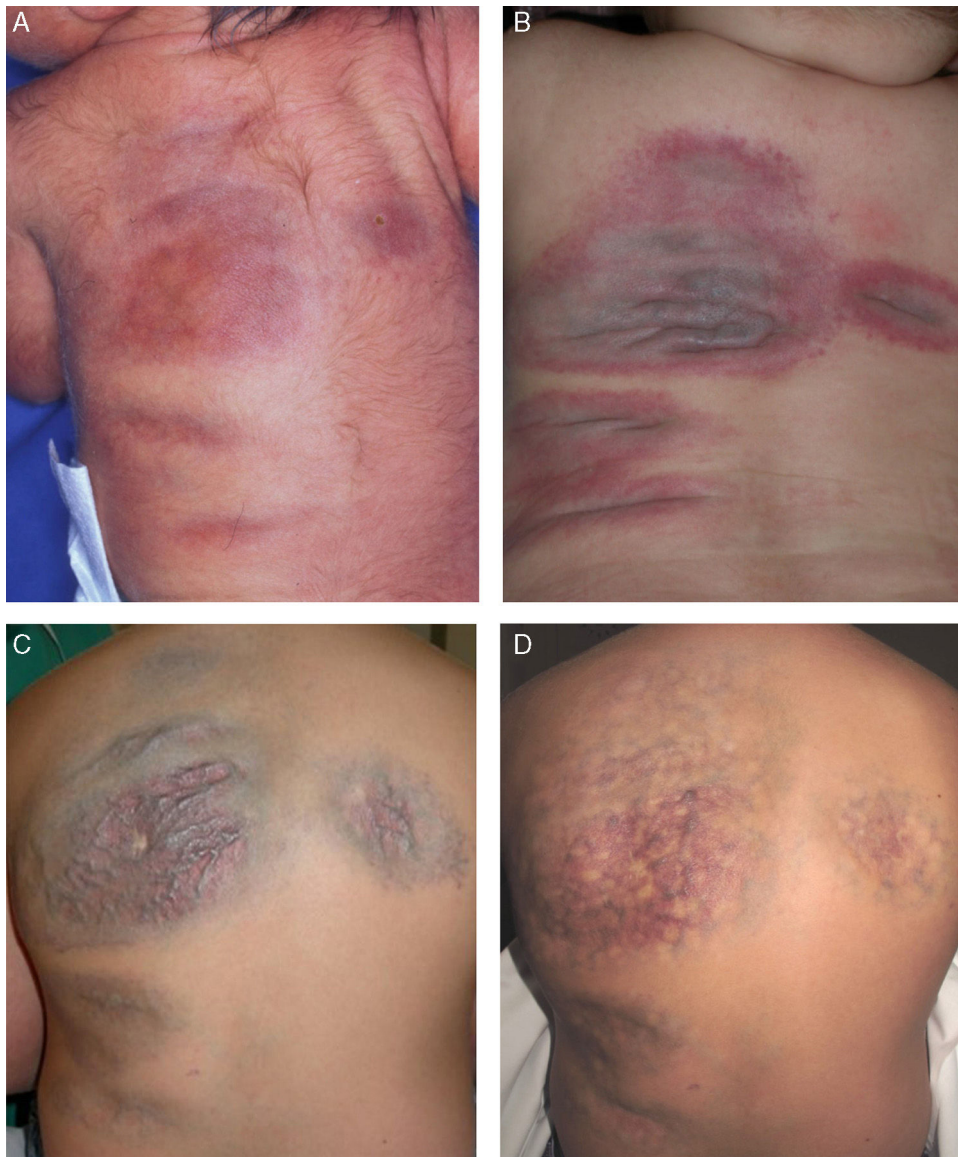

Figure 1 Clinical course of the lesions. A, Newborn: erythematous-violaceous plaques on the back. B, At 6 months of age: plaques with prominent vessels, erythematous borders, and a blue-violaceous center. C, Before laser treatment (7 years of age). D, After 10 sessions of combined pulsed dye and neodymium-doped yttrium aluminium garnet laser treatment (11 years of age).

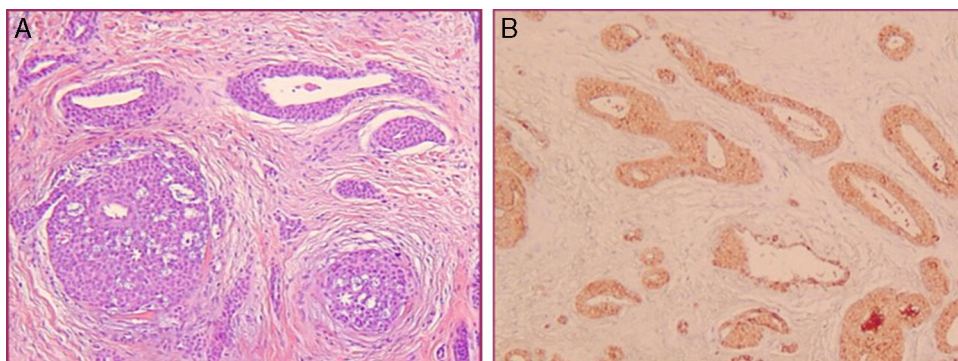


Figure 2 Histopathology. A, Blood vessels of different calibers surrounded by several layers of monomorphic round cells. Hematoxylin and eosin, original magnification $\times 20$. B, Positivity for α -smooth muscle actin. Immunohistochemistry, original magnification $\times 20$.

Table 1 Patients With Congenital Plaque-Type Glomuvenous Malformations Treated With Combined Pulsed Dye and Neodymium-Doped Yttrium Aluminium Garnet Laser.

Reference	Age and Sex	Site Affected	Fluence	Pulse Duration	Spot Size	No. of Sessions	Follow-up Period	Response	Complications
6	34 y Male	Left arm	PDL: 8 J/cm ² Ns:YAG: 70 J/cm ²	PDL: 0.5 ms Ns:YAG: 15 ms	10 mm	4	1 y	Resolution of the pain, lightening of color and volume reduction	None
7	6 mo Female	Scalp, trunk, abdomen, back, right inguinal region and thighs	PDL: 6 J/cm ² Ns:YAG: 110 J/cm ²	PDL: 0.5 ms Ns:YAG: 20 ms	10 mm	6	18 mo	Lightening of color and size reduction	None
Our patient	11 y Male	Back	PDL: 8.5 J/cm ⁹ Ns:YAG: 50 J/cm ⁹	PDL: 0.5 ms Ns:YAG: 15 ms	10 mm	10	11 y	Lightening of color and reduction of volume and of vessel caliber	None

minimize the risk of scars or necrosis. There are 2 previous reports of congenital plaque-type GVM treated successfully with the combined PDL/Nd:YAG laser,¹⁰ using higher Nd:YAG fluences than those employed in our patient, with no complications (Table 1).

In conclusion, we have presented a case of congenital plaque-type GVM that, in its initial phases, was included in the series by Mallory et al.² We draw attention to its uncommon clinical presentation, which was a diagnostic challenge and required histopathological confirmation, the atypical clinical course over 11 years, and the favorable response to combined laser treatment.

Conflicts of Interest

The authors declare that they have no conflicts of interest.

References

- Boon LM, Mulliken JB, Enjolras O, Vikkula M. Glomuvenous malformation (glomangioma) and venous malformation: Distinct clinicopathologic and genetic entities. *Arch Dermatol.* 2004;140:971–6.
- Mallory SB, Enjolras O, Boon LM, Rogers E, Berk DR, Blei F, et al. Congenital plaque-type glomuvenous malformations presenting in childhood. *Arch Dermatol.* 2006;142:892–6.
- Requena L, D Galvan C, Sánchez Yus E, Sanguenza O, Kutzner H, Furio V. Solitary plaque-like telangiectatic glomangioma. *Br J Dermatol.* 1998;139:902–5.
- Yoon TY, Lee HT, Chang SH. Giant congenital multiple patch-like glomus tumors. *J Am Acad Dermatol.* 1999;40:826–8.
- Hazey MA, Van Norman AJ, Powers RL, Armistead DL. Multiple congenital plaque-like glomuvenous malformations with type 2 segmental involvement. *Cutis.* 2009;84:16–8.
- Grillo E, Boixeda P, Paoli J, Vano-Galván S, Carrillo R, Jaén P. Congenital plaque-like glomangioma treated successfully with dual wavelength pulsed-dye and neodymium:yttrium-aluminum-garnet laser. *Photodermatol Photoimmunol Photomed.* 2013;29:212–4.
- Nguyen TV, Becker EM, Miller WA, Browning JC. Plaque-type glomuvenous malformations successfully treated using combined pulsed dye laser and neodymium-doped yttrium aluminum garnet laser. *Dermatol Surg.* 2014;40:89–92.
- Cavalli R, Milani GP, Chelleri C, Donelli S, Fossali EF. Plaque-type glomuvenous malformations in a child. *Lancet.* 2015;386:e61.
- Rivers JK, Rivers CA, Li MK, Martinka M. Laser therapy for an acquired glomuvenous malformation (glomus tumour): A nonsurgical approach. *J Cutan Med Surg.* 2016;20:80–3.
- Hughes R, Lacour JP, Chiaverini C, Rogopoulos A, Passeron T. Nd:YAG laser treatment for multiple cutaneous glomangiomas: Report of 3 cases. *Arch Dermatol.* 2011;147:255–6.

N. Vargas-Navia,* E. Baselga, F.Z. Muñoz-Garza, L. Puig

Servicio de Dermatología, Hospital de la Santa Creu i Sant Pau, Universitat Autònoma de Barcelona, Barcelona, Spain

* Corresponding author.

E-mail address: navana2@hotmail.com (N. Vargas-Navia).

1578-2190/

© 2016 Elsevier España, S.L.U. and AEDV. All rights reserved.