

contemplated when negative results are obtained for the above markers and the other entities in the differential diagnosis have been ruled out, although this tumor typically presents xanthomatous cells with vesicular nuclei and it may express CD10. When Bednar tumor is diagnosed, it is important to remember that these tumors are locally aggressive and invasive and tend to recur locally, but metastasis is rare and delayed. In conclusion, histopathology combined with immunohistochemistry or molecular biology is essential for the correct diagnosis and treatment of Bednar tumor.

Conflicts of Interest

The authors declare that they have no conflicts of interest.

References

1. Dupree WB, Langloss JM, Weiss SW. Pigmented dermatofibrosarcoma protuberans (Bednar tumor): A pathologic, ultrastructural, and immunohistochemical study. *Am J Surg Pathol.* 1985;9:630–9.
2. Yagi Y, Ueda K, Maruyama S, Noborio R. Bednar tumor: A Report of two cases. *J Dermatol.* 2004;31:484–7.
3. Suehara Y, Yazawa Y, Hitachi K. Metastatic Bednar tumor (pigmented dermatofibrosarcoma protuberans) with fibrosarcomatous change: A case report. *J Orthop Sci.* 2004;9:662–5.
4. McAllister J, Recht B, Hoffman T, Uma S. CD34+ pigmented fibrous proliferations: The morphologic overlap between pigmented dermatofibromas and Bednar tumors. *Am J Dermatopathol.* 2008;30:484–7.
5. Llombart B, Sanmartín O, López-Guerrero JA, Monteagudo C, Serra C, Requena C, et al. Dermatofibrosarcoma protuberans: Clinical, pathological, and genetic (COL1A1-PDGFB) study with therapeutic implications. *Histopathology.* 2009;54:860–72.
6. Fu Y, Kang H, Zhao H, Hu J, Zhang H, Li X, et al. Sunitinib for patients with locally advanced or distantly metastatic dermatofibrosarcoma protuberans but resistant to imatinib. *Int J Clin Exp Med.* 2015;8:8288–94.
7. Bednar B. Storiform neurofibromas of the skin, pigmented and nonpigmented. *Cancer.* 1957;10:368–76.
8. Morais P, Schettini A, Chirano C, Nakamura G. Bednar tumor (pigmented dermatofibrosarcoma protuberans): A case report. *An Bras Dermatol.* 2005;80:273–6.

M.J. Añón-Requena,^{a,*} M. Pico-Valimaña,^b
G. Muñoz-Arias^a

^a *Unidad de Gestión Clínica, Intercentros de Anatomía Patológica Bahía de Cádiz, Hospital Universitario Puerto Real, Cádiz, Spain*

^b *Sección de Dermatología, Unidad de Gestión Clínica Bloque Quirúrgico, Hospital Universitario Puerto Real, Cádiz, Spain*

* Corresponding author.

E-mail address: mjareq@gmail.com (M.J. Añón-Requena).

Localized Lipoatrophy in a Boy After an Intramuscular Injection of Penicillin[☆]



Lipoatrofia localizada en un niño tras administración de penicilina intramuscular

To the Editor:

Localized lipoatrophy is characterized by the loss of subcutaneous fat in a particular area of the body. In children, the condition is mainly related to subcutaneous or intramuscular injections of drugs or vaccines. Localized lipoatrophy is usually diagnosed clinically, although histopathologic examination can be necessary in some cases to rule out other causes such as connective tissue diseases and neoplasms.

We present the case of a healthy 8-year-old boy who was referred to our dermatology department for assessment of an asymptomatic lesion on his left thigh that had appeared 4 years earlier. A few weeks before the lesion appeared, the patient was diagnosed with streptococcal pharyngoamygdalitis and received treatment with an intramuscular injection of benzathine penicillin (600 000 IU) on the lateral aspect of the left thigh. The lesion grew in

proportion to the boy as he grew taller and gained weight. The boy had no personal or family history of autoimmune disease or history of trauma at the site of the lesion.

Physical examination revealed a 9 × 7 cm depressed plaque of similar color to the adjacent skin on the anterolateral aspect of the left thigh. The lesion was covered with normal skin (Fig. 1). No similar lesions were detected at other sites. No loss of strength or sensitivity was observed in the lower left limb.

Blood tests were carried out, including complete blood count, kidney and liver function, cholesterol, triglycerides, lipase, complement, rheumatoid factor, antistreptolysin O, and antinuclear antibodies. No significant abnormalities were found. The patient tested negative for *Borrelia burgdorferi*.

Ultrasound examination of the lesion revealed a complete loss of subcutaneous tissue alongside adjacent healthy skin. No muscular abnormalities were observed (Fig. 2). The parents declined to allow a biopsy of the lesion.

Treatment with medium-strength topical corticosteroids and topical calcineurin inhibitors was started. No improvement was seen after 2 months of treatment. The lesion has remained stable for 2 years of follow-up and no similar lesions have appeared at other sites.

Localized lipoatrophy can be classified as primary (or idiopathic) or as secondary to minor repetitive trauma injuries, injections of various drugs (penicillin, amikacin, methotrexate, corticosteroids, insulin)^{1–5} and vaccines,⁶ connective tissue diseases (lupus erythematosus, morphea, dermatomyositis), or malignant neoplasms.

[☆] Please cite this article as: Vázquez-Osorio I, Rodríguez-Vidal A, Rosón E, Alonso-González J, Vázquez-Veiga H. Lipoatrofia localizada en un niño tras administración de penicilina intramuscular. *Actas Dermosifiliogr.* 2016;107:620–622.

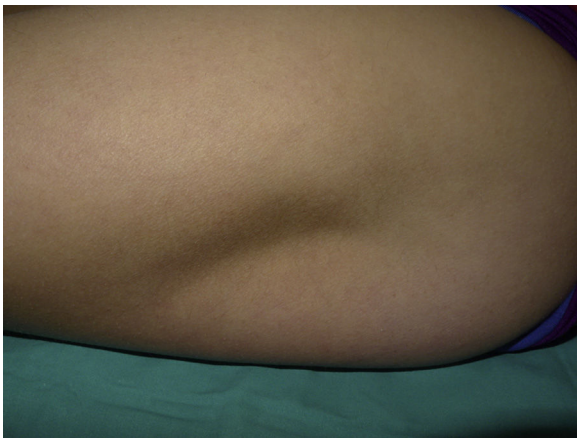

Figure 1 Semicircular depressed plaque measuring 9 × 7 cm, covered with normal skin and located on the anterolateral aspect of the left thigh.

Localized lipoatrophy secondary to drugs is characterized by the presence of depressed, asymptomatic lesions with a color and appearance similar to that of the adjacent skin. The lesions typically appear a few weeks or months after the injection and are usually located on the anterolateral aspect of the thighs, buttocks, or abdominal region.

The lesions tend to regress after a few months or years, although this depends on the drug involved and the degree of lipoatrophy. Lesions secondary to insulin injection tend to resolve spontaneously. Kumar et al.² presented 2 cases of localized lipoatrophy caused by amikacin in which the lesions disappeared spontaneously after 2 and 3 months, respectively. Avilés-Izquierdo et al.⁴ reported a case associated with intramuscular corticosteroid injection in which the lesions regressed after 2 months. In the cases associated with methotrexate and penicillin that have been reported, the progression of the lesions is unknown due to lack of follow-up.^{1,3}

In the case of our patient, the lesion remained stable after 2 years of follow-up. Haas et al.³ associated the persistence of the lesions in their patient with the possible

existence of an underlying autoimmune disease. In the case of our patient, neither the clinical data nor the test results suggested the existence of an underlying autoimmune disease at any time during follow-up.

The etiology and pathogenesis of localized lipoatrophy are not clearly defined. The triggering mechanism is probably different for each drug. Insulin-induced lipoatrophy appears to be associated with local hyperproduction of tumor necrosis factor- α and interleukin-6, which would lead to a dedifferentiation of adipocytes.⁵ The injection itself could also play an important role in the development of lipoatrophy by causing macrophages to release cytokines, which in turn enhance the lipocyte catabolism and inhibit lipogenesis.⁶ In addition, hypoperfusion of the anterolateral aspect of the thigh due to anatomic variants of the lateral circumflex femoral artery would explain the lipoatrophy at that site.³ In the case of our patient, the injection of the drug, the anatomy and vascularization of the anterolateral aspect of the thigh, and the existence of ischemic phenomena caused by arterial trauma could explain the development of lipoatrophy.

The diagnosis of localized lipoatrophy is mainly clinical, although in some cases a skin biopsy can be necessary in order to rule out underlying disease. Histologic examination reveals a reduction in the size of the fat lobules of the hypodermis, with no evidence of fat necrosis, calcification, granulomas, or atypia. Cutaneous ultrasound can also be a useful tool in the diagnosis of patients with clinical suspicion of localized lipoatrophy. With cutaneous ultrasound, it is possible to quickly and safely observe—underneath a normal epidermis and dermis—a marked reduction in the subcutaneous tissue without the involvement of muscular tissue.

Because localized lipoatrophy tends to resolve spontaneously, many cases require no treatment. However, in cases in which the lesions persist, creating a significant cosmetic deficiency, some form of treatment may be indicated. Although no definitive treatment exists, intralesional corticosteroids have been used to treat lesions caused by insulin injections, with favorable results in some cases.^{7,8} This beneficial effect seems to be caused by the immunomodulating properties of the corticosteroids and to their capacity to induce the differentiation of adipocytes. However, because the reported cases are isolated, and because intralesional corticosteroid injections can themselves cause lipoatrophy, this treatment should be indicated with caution.

In corticosteroid-induced localized lipoatrophy, it has been shown that the intralesional administration of saline solution, autologous fat, or poly-L-lactic acid can have beneficial effects and improve the cosmetic appearance of the lesion.^{9,10}

Avoiding injections in the anterolateral aspect of the thighs, rotating injection sites, and changing insulin pen needles are recommendations that can help patients and their family members prevent localized lipoatrophy secondary to drug injection.⁵

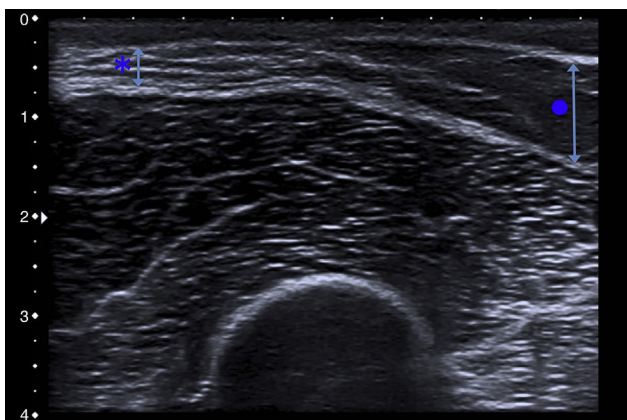


Figure 2 Cutaneous ultrasound revealed a marked loss of subcutaneous tissue (asterisk and short arrow) in comparison to the healthy adjacent subcutaneous tissue (circle and long arrow).

References

1. Kayıcioglu A, Akyürek M, Erk Y. Semicircular lipoatrophy after intragluteal injection of benzathine penicillin. *J Pediatr.* 1996;129:166–7.

2. Kumar V, Kumar M, Grover C. Localized lipoatrophy after intramuscular amikacin. *Indian J Dermatol Venereol Leprol.* 2009;75:552.
 3. Haas N, Henz BM, Bunikowski R, Keitzer R. Semicircular lipoatrophy in a child with systemic lupus erythematosus after subcutaneous injections with methotrexate. *Pediatr Dermatol.* 2002;19:432–5.
 4. Avilés-Izquierdo JA, Longo-Imedio MI, Hernández-Hermosa JM, Lázaro-Ochaita P. Bilateral localized lipoatrophy secondary to a single intramuscular corticosteroid injection. *Dermatol Online J.* 2006;12:17.
 5. Del Olmo MI, Campos V, Abellán P, Merino-Torres JF, Piñón F. A case of lipoatrophy with insulin detemir. *Diabetes Res Clin Pract.* 2008;80:e20–1.
 6. Sardana K, Garg VK, Bhushan P, Relhan V, Sharma S. DPT vaccine-induced lipoatrophy: An observational study. *Int J Dermatol.* 2007;46:1050–4.
 7. Ramos AJ, Farias MA. Human insulin-induced lipoatrophy. A successful treatment with glucocorticoid. *Diabetes Care.* 2006;29:926–7.
 8. Swelheim HT, Westerlaken C, van Pinxteren-Nagler E, Bocca G. Lipoatrophy in a girl with type 1 diabetes: Beneficial effects of treatment with a glucocorticoid added to an insulin analog. *Diabetes Care.* 2012;35:e22.
 9. Shumaker PR, Rao J, Goldman MP. Treatment of local, persistent cutaneous atrophy following corticosteroid injection with normal saline infiltration. *Dermatol Surg.* 2005;31:1340–3.
 10. Brodell DW, Marchese Johnson S. Use of intralesional poly-L-lactic acid in the treatment of corticosteroid-induced lipoatrophy. *Dermatol Surg.* 2014;40:597–9.
- I. Vázquez-Osorio,^{a,*} A. Rodríguez-Vidal,^b E. Rosón,^a
J. Alonso-González,^a H. Vázquez-Veiga^a
- ^a *Departamento de Dermatología, Hospital Clínico Universitario, Santiago de Compostela, A Coruña, Spain*
^b *Departamento de Pediatría, Hospital Clínico Universitario, Santiago de Compostela, A Coruña, Spain*
- * Corresponding author.
E-mail address: rogivaos@gmail.com (I. Vázquez-Osorio).

DermaComp: A Pharmaceutical Compounding iPhone® Application for Dermatologists Designing Personalized Topical Medications[☆]



DermaComp: aplicación para iPhone® para el diseño de medicamentos tópicos individualizados dirigido a dermatólogos

To the Editor:

Smartphone applications (apps) are of particular interest to dermatologists, and some 229 already exist in the categories of general dermatology, self-surveillance/diagnosis, disease guides, patient education, sun protection, calculators, teledermatology, dermoscopy, etc.^{1–3} All of these apps are potentially very useful, although the use that dermatologists and patients make of them has not yet been studied.

The design and preparation of personalized medication solutions or compounds requires training and practice on the part of both the dermatologist and the pharmacist. The dermatologist must specify the quantity and quality of the active ingredients and the most appropriate excipients depending on the characteristics of the patient's skin disease. The pharmacist must prepare the medication using the best available technique.⁴

To aid clinicians in this task, we have developed DermaComp, an iPhone application that helps the dermatologist

to create a customized medication using a quick, easy, and intuitive process that facilitates the design of the formula. DermaComp also does the following: 1) improves the exchange of information between the dermatologist and the compounding pharmacist, including a large amount of information not normally found in traditional compounding prescriptions (such as, for example, patient characteristics, site of application, and vehicle type); 2) achieves better therapeutic results because it adapts the drug to the specific needs of each patient; and 3) displays the most appropriate active ingredients and vehicles for each disease and site, increasing the safety of dosing ranges and optimizing consultation time.⁵

DermaComp was designed to run on devices using the iOS operating system (version 7 or higher) and is optimized for iPhone 4, 5, and 6. The scientific content was created by a dermatologist and a compounding pharmacist, and the app was developed using the Objective-C object-oriented language and Apple Xcode development tools. Management and storage of data is handled with Apple Frameworks and version control with the GIT system. Finally, the app was validated on several Apple devices.⁶

When the dermatologist opens DermaComp, the app displays a list of the 5 skin disorders for which compounded medications are most often used: psoriasis, alopecia, oral and genital mucosal disorders, rosacea, and seborrheic dermatitis (Fig. 1A). Once the appropriate disorder has been selected, the user only has to complete 6 rapid and intuitive steps:

Step 1. Introduce patient characteristics, including age, drug allergies or adverse reactions and, in the case of a woman, pregnancy status. Based on this information, the app will exclude any active ingredients or vehicles unsuitable for the patient and adjust maximum concentration levels, especially in the case of children and pregnant women.

Step 2. Mark the site of the lesion(s) on a graphic representation of a human figure (Fig. 1B).

[☆] Please cite this article as: Abarca Lachén E, Gilaberte Y. DermaComp: aplicación para iPhone® para el diseño de medicamentos tópicos individualizados dirigido a dermatólogos. *Actas Dermosifiliogr.* 2016;107:622–624.