




ACTAS Derma-Sifiliográficas

Full English text available at
www.actasdermo.org



CASE AND RESEARCH LETTERS

Sarcoidosis and Tuberculosis: A Diagnostic Challenge[☆]



Sarcoidosis y tuberculosis: un desafío diagnóstico

To the Editor:

Sarcoidosis is a multiorgan disease of unknown etiology, characterized by the presence of noncaseating granulomas. Factors implicated in its etiology include certain microorganisms, such as *Mycobacterium tuberculosis*, and a genetic predisposition.¹

Our patient was a 31-year-old man from Morocco who had been living in Spain for 11 years. He was seen in dermatology outpatients for evaluation of asymptomatic lesions that had been present on his forehead for 8 months and that he found unsightly. His medical history revealed that he had been on treatment with isoniazid, rifampicin, pyrazinamide, and ethambutol for 2 months for low-grade fever and dyspnea, diagnosed as pulmonary tuberculosis. He brought a discharge report from another hospital in the same Autonomous Community in Spain, with details of following additional tests: x-ray study showing a gangliopulmonary pattern, a positive QuantiFERON-TB test, and sputum culture positive for *M tuberculosis*.

Physical examination revealed an erythematous annular maculopapular rash with central atrophy in the frontal region, in areas in which there were no previous scars (Fig. 1). Histology of a biopsy from 1 of the lesions in the frontal region revealed a granulomatous inflammatory infiltrate formed mainly of a number of Langhans-type giant cells and epithelioid cells (Fig. 2). Given the patient's history of tuberculosis, Ziehl-Neelsen stain and polymerase chain reaction (PCR) for mycobacteria were performed on the skin biopsy sample, with a negative result, compatible with cutaneous sarcoidosis. In view of the dermatologic findings and persistence of the patient's dyspnea, transbronchial biopsy was performed. This showed numerous granulomas with no necrosis, but with fibrosis and a discreet peripheral ring of lymphocytes; Ziehl-Neelsen stain was negative.

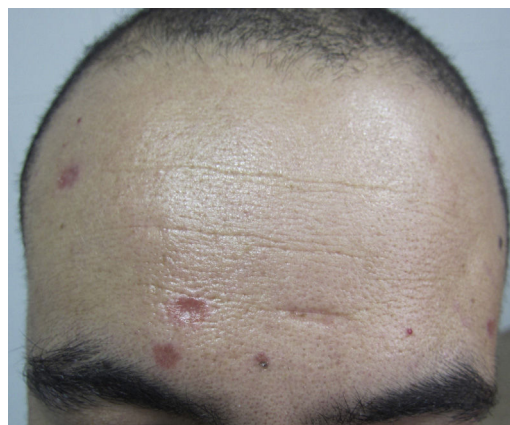

Figure 1 Erythematous papules with an atrophic central zone, situated in the frontal region.

Blood tests revealed an increase in angiotensin-converting enzyme (ACE) levels to 134 U/L (normal range, 8–55 U/L) and elevation of uric acid levels to 9.7 mg/dL (normal range, 3.5–7.0 mg/dL); the other laboratory parameters were normal.

Finally, based on both pathology results, a diagnosis of pulmonary and cutaneous sarcoidosis associated with pulmonary tuberculosis was made. Prednisone, 30 mg, was added to the antituberculous treatment and was subsequently tapered to reach a maintenance dose of 5 mg; there was a good clinical and radiologic response. The skin lesions resolved, leaving residual scars in the areas of previous central atrophy.

Sarcoidosis and tuberculosis are both granulomatous diseases that rarely occur concomitantly. In contrast to tuberculosis, sarcoidosis is noncaseating.

The most commonly affected organ in sarcoidosis is the lung, followed by skin involvement, which occurs in approximately 24% of cases. Many clinical variants have been described, including papular, plaque, psoriasiform, annular, atrophic, and mixed forms. Long-standing sarcoidosis and lupus pernio lesions typically heal leaving a scar.¹ Histologically, the granulomas are formed mainly of epithelioid cells, sometimes with scattered lymphocytes peripherally; Langhans-type multinucleated giant cells may be present; they are more common in longer-standing lesions, though they have also been described in large numbers in early lesions.²

The etiology of sarcoidosis remains unknown, though *M tuberculosis* has been implicated. Using PCR, Li et al.³

[☆] Please cite this article as: de la Fuente-Meira S, Gracia-Cazaña T, Pastushenko I, Ara M. Sarcoidosis y tuberculosis: un desafío diagnóstico. Actas Dermosifiliogr. 2016;107:605–607.

Table 1 Summary of Published Cases of Sarcoidosis Associated With Tuberculosis.

	Age/Sex	Tuberculosis	Sarcoidosis	Diagnosis of Sarcoidosis
Wong et al. ⁵	35 y Female	Pulmonary	Lymphatic and pulmonary	Diagnosis of sarcoidosis 15 months after the diagnosis of tuberculosis
Mise et al. ⁶	43 y Female	Pulmonary	Cutaneous and pulmonary	Concomitant
Gupta et al. ⁷	65 y Female	Renal	Cutaneous	Diagnosis of sarcoidosis 4 years after the diagnosis of tuberculosis
Ahmad et al. ⁸	55 y Female	Pulmonary	Cutaneous	Diagnosis of sarcoidosis 3 years after the diagnosis of tuberculosis
Ganguly et al. ⁹	28 y Male	Pulmonary	Cutaneous	Diagnosis of sarcoidosis 9 months after the diagnosis of tuberculosis
Mandal et al. ¹⁰	38 y Female	Miliary	Pulmonary	Concomitant
Oluboyo et al. ¹¹	NS Male	Pulmonary	Pulmonary	Concomitant
Papaetis et al. ¹²	67 y Female	Pulmonary	Pulmonary	Concomitant diagnosis, although the authors state that undiagnosed sarcoidosis had been present for 8 years
De la Fuente et al.	31 y Male	Pulmonary	Cutaneous and pulmonary	Diagnosis of sarcoidosis 3 months after the diagnosis of tuberculosis

Abbreviation: NS, not specified.

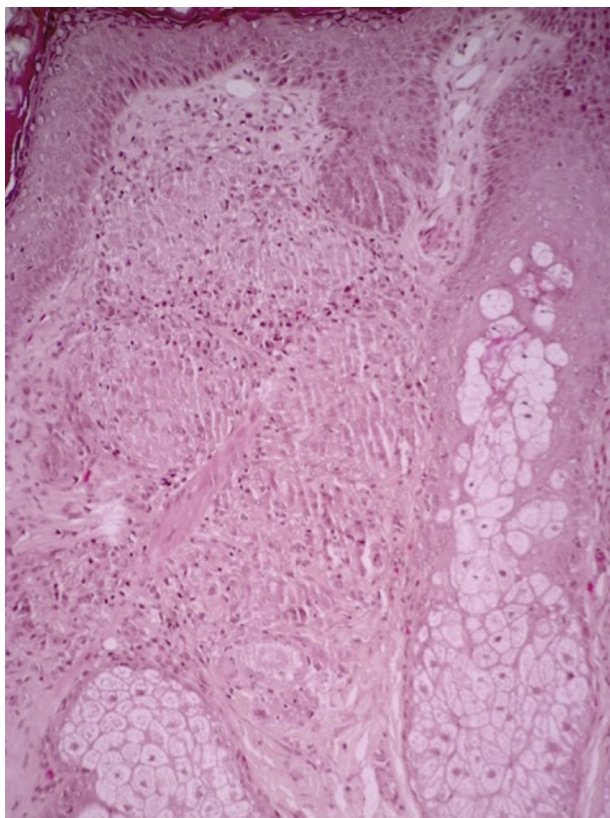


Figure 2 Granulomatous inflammatory infiltrate formed of histiocytes and occasional Langhans-type giant cells. Hematoxylin and eosin, original magnification $\times 10$.

identified DNA from *M tuberculosis* and from *Mycobacterium avium* in up to 50% of lung biopsies from patients diagnosed with sarcoidosis. Another study that looked at the etiology and pathogenesis of sarcoidosis was performed by Ding

et al.⁴ Those authors identified genetic material related to mycobacterial heat shock proteins in 21% of skin biopsies from patients diagnosed with sarcoidosis and concluded that this infection could be a direct etiologic factor.

In clinical practice, there are few reports of patients who have presented the 2 diseases concomitantly or in whom the diagnosis of sarcoidosis was made after that of tuberculosis; these cases are listed in Table 1.⁵⁻¹² In our review, we have excluded patients who were on corticosteroid treatment for sarcoidosis and who subsequently developed tuberculosis, as the most common cause of the infection in such patients is immunosuppression.

In patients in whom we suspect the concomitant presence of the 2 diseases, it is essential to determine whether the lesions corresponds to one or other granulomatous disease, as skin lesions mimicking sarcoidosis have been reported in patients with tuberculosis, such as the case published by Chokoeva et al.,¹³ in which the diagnosis of sarcoid-like lesions was only achieved with the aid of the QuantiFERON-TB test and a positive Ziehl Neelsen stain.

Biomarkers that can differentiate between these 2 diseases have been sought. Serum markers related with sarcoidosis, including soluble interleukin-2 receptor (IL-2R), ACE, and Krebs von den Lungen-6 (KL-6), are not sufficiently sensitive or specific to separate these diagnoses. It has recently been observed that the combination of leptin and intercellular adhesion molecule-1 has a sensitivity of 86.5% and a specificity of 73.1% as a marker of sarcoidosis, and this combination could therefore be employed to differentiate the 2 conditions.¹⁴

In conclusion, the diagnoses of sarcoidosis and tuberculosis are not mutually exclusive. It is likely that tuberculosis has been a triggering agent of sarcoidosis, although further studies will be necessary to determine its etiologic role. Finally, to prevent the complications of sarcoidosis, corticosteroid treatment should not be delayed.

Conflicts of Interest

The authors declare that they have no conflicts of interest.

References

- Fortuño Y, Gallego I, Marcoval J. Sarcoidosis cutánea. *Actas Dermosifiliogr.* 2004;95:137–53.
 - Drummond C, Savdie E, Kossard S. Sarcoidosis with prominent giant cells. *Australas J Dermatol.* 2001;42:290–3.
 - Li N, Bajoghli A, Kubba A, Bhawan J. Identification of mycobacterial DNA in cutaneous lesions of sarcoidosis. *J Cutan Pathol.* 1999;26:271–8.
 - Ding XL, Cai L, Zhang JZ. Detection and identification of mycobacterial gene in skin lesions and lymph nodes in patients with sarcoidosis. *Zhongguo Yi Xue Ke Xue Yuan Xue Bao.* 2009;31:20–3.
 - Wong CF, Yew WW, Wong PC, Lee J. A case of concomitant tuberculosis and sarcoidosis with mycobacterial DNA present in the sarcoid lesion. *Chest.* 1998;114:626–9.
 - Mise K, Goic-Barisic I, Puizina-Ivic N, Barisic I, Tonkic M, Peric I. A rare case of pulmonary tuberculosis with simultaneous pulmonary and skin sarcoidosis: A case report. *Cases J.* 2010;3:24.
 - Gupta LK, Luhadia SK, Khare AK, Garg A, Mittal A, Kuldeep CM. Pulmonary and cutaneous sarcoidosis in a treated case of renal tuberculosis. *Indian J Dermatol Venereol Leprol.* 2012;78:229.
 - Ahmad K, Powell FC. Cutaneous sarcoidal reaction in a patient with pulmonary tuberculosis. *Ir Med J.* 2005;98:182.
 - Ganguly S, Ganguly D. Sarcoidosis following sputum positive pulmonary tuberculosis: A rare entity. *Indian J Dermatol.* 2012;57:76–8.
 - Mandal SK, Ghosh S, Mondal SS, Chatterjee S. Coexistence of pulmonary tuberculosis and sarcoidosis: A diagnostic dilemma. *BMJ Case Rep.* 2014:19.
 - Oluboyo PO, Awotedu AA, Banach L. Concomitant sarcoidosis in a patient with tuberculosis: First report of association in Africa. *Cent Afr J Med.* 2005;51:123–5.
 - Papaetis GS, Pefanis A, Solomon S, Tsangarakis I, Orphanidou D, Achimastos A. Asymptomatic stage I sarcoidosis complicated by pulmonary tuberculosis: A case report. *J Med Case Rep.* 2008;2:226.
 - Chokoeva AA, Tchernev G, Tana C, Ananiev J, Wollina U. Sarcoid-like pattern in a patient with tuberculosis. *J Biol Regul Homeost Agents.* 2014;28:783–8.
 - Du SS, Zhao MM, Zhang Y, Zhang P, Hu Y, Wang LS, et al. Screening for differentially expressed proteins relevant to the differential diagnosis of sarcoidosis and tuberculosis. *PLoS One.* 2015;10:e0132466.
- S. de la Fuente-Meira,^{a,*} T. Gracia-Cazaña,^b
I. Pastushenko,^c M. Ara^d
- ^a *Servicio de Dermatología, Hospital Ernest Lluch, Zaragoza, Spain*
^b *Servicio de Dermatología, Hospital de Barbastro, Huesca, Spain*
^c *Interdisciplinary Research Institute (IRIBHM), Université Libre de Bruxelles (ULB), Bruselas, Bélgica*
^d *Servicio de Dermatología, Hospital Clínico Lozano Blesa, Zaragoza, Spain*
- *Corresponding author.
E-mail address: delafuente.sonia@gmail.com
(S. de la Fuente-Meira).

Benign Cutaneous Plexiform Hybrid Tumor of Perineurioma and Cellular Neurothekeoma[☆]



Tumor benigno cutáneo plexiforme híbrido de perineuroma y neurotecoma celular

Dear Editor:

The benign cutaneous plexiform hybrid tumor of perineurioma and cellular neurothekeoma (BCPHTPCN) is an entity described by Requena et al.¹ in 2013. It typically presents clinically as a small solitary papule in the perioral region, although other authors have described a lesion on the nose² and another on the left ankle.³ Histology reveals mixed pathological features of perineurioma and of cellular neurothekeoma with a plexiform architecture.^{1,3} Immunohistochemistry, when performed, has been positive for S100A6, microphthalmia-associated transcription factor (MITF), lysosomal membrane-associated glycoprotein

3 (NKI/C3), protein gene product 9.5 (PGP9.5), epithelial membrane antigen (EMA), and neuron-specific enolase (NSE). Expression of CD34, claudin-1, and glucose transporter 1 (GLUT1) has been more variable, weaker, and focal. In addition to the 9 patients in the original study, a further 2 cases have been published. We present a new case of this recently identified lesion. The tumor in our case was positive for CD68 and CD163 in a large number of cells situated between the nests of neoplastic cells, a finding that was only described in a few stromal histiocytes in 2 of the cases in the original series.¹

The patient was a man aged 58 years who presented a well-defined, hard, round, elevated lesion that had been growing slowly on his lower lip for 2 years and measured 5 mm in diameter at the time of first consultation. The surface of the lesion was erythematous and shiny. The patient was otherwise asymptomatic. Curettage was performed. Histology showed a circumscribed, nonencapsulated nodule in the superficial dermis (Fig. 1A). The nodule had a plexiform architecture (Fig. 1B) and did not make contact with the epidermis. Some cells had an epithelioid appearance with abundant eosinophilic cytoplasm, blurred cell borders, vesicular nuclei, and inconspicuous nucleoli. Other cells were delicate and spindle-shaped, with hyperchromatic nuclei. No pleomorphism, mitoses, or necrosis were observed. The stroma was myxoid with areas of collagen

[☆] Please cite this article as: Areán C, Córdoba A, Requena L, Álvarez ML. Tumor benigno cutáneo plexiforme híbrido de perineuroma y neurotecoma celular. *Actas Dermosifiliogr.* 2016;107:607–610.