

rate declines with age.<sup>8</sup> Thus, the immunoglobulin G titers generated after 2 doses of vaccine in girls aged 9-14 years are not inferior to those generated after 3 doses in women aged 15-25 years; hence, only 2 doses are usually administered in girls aged less than 14 years.<sup>1</sup> In this sense, a possible effect of sex hormones on the cellular response induced by these vaccines has been suggested, since they affect expression of HPV proteins.<sup>8</sup>

Finally, bringing the vaccination age forward to 9 years would not reduce medium- to long-term efficacy, since the bivalent vaccine has shown seropositivity rates >98% at 8 years after administration of the first dose.<sup>1</sup>

Complete remission of common warts after administration of the recombinant bivalent HPV vaccine had not been previously reported in the literature. Bringing the HPV vaccination age forward could prove to be a very useful option for the management of recalcitrant common warts in prepubertal girls. In the coming years, the incidence of common warts could decrease in women vaccinated against HPV.

## Conflicts of Interest

The authors declare that they have no conflicts of interest.

## References

1. Gardasil®: Summary of Product Characteristics [accessed 19 Sep 2015]. Available at: [http://www.ema.europa.eu/docs/es\\_ES/document\\_library/EPAR\\_-\\_Product\\_Information/human/000721/WC500024632.pdf](http://www.ema.europa.eu/docs/es_ES/document_library/EPAR_-_Product_Information/human/000721/WC500024632.pdf)
2. Venugopal SS, Murrell DF. Recalcitrant cutaneous warts treated with recombinant quadrivalent human papillomavirus vaccine (types 6, 11, 16, and 18) in a developmentally delayed, 31-year-old white man. *Arch Dermatol.* 2010;146:475-7.
3. Ault KA. Human papillomavirus vaccines and the potential for cross-protection between related HPV types. *Gynecol Oncol.* 2007;107 Suppl 1:S31-3.
4. Slupetzky K, Gambhira R, Culp TD, Shafti-Keramat S, Schellenbacher C, Christensen ND, et al. A papillomavirus-like particle (VLP) vaccine displaying HPV16 L2 epitopes induces cross-neutralizing antibodies to HPV11. *Vaccine.* 2007;25:2001-10.
5. Pinto LA, Viscidi R, Harro CD, Kemp JT, García-Piñeres AJ, Trivett M, et al. Cellular immune responses to human papillomavirus (HPV)-16 L1 in healthy volunteers immunized with recombinant HPV-16 L1 virus-like particles. *Virology.* 2006;353:451-62.
6. Moscato GM, di Matteo G, Ciotti M, di Bonito P, Andreoni M, Moschese V. Dual response to human papilloma virus vaccine in an immunodeficiency disorder: resolution of plantar warts and persistence of condylomas. *J Eur Acad Dermatol Venereol.* 2015, <http://dx.doi.org/10.1111/jdv.13133> [Epub ahead of print].
7. Kreuter A, Waterboer T, Wieland U. Regression of cutaneous warts in a patient with WILD syndrome following recombinant quadrivalent human papillomavirus vaccination. *Arch Dermatol.* 2010;146:1196-7.
8. Abeck D, Fölster-Holst R. Quadrivalent human papillomavirus vaccination: A promising treatment for recalcitrant cutaneous warts in children. *Ann Derm Venereol.* 2015;95:1017-9.

J.M. Martín,<sup>a,b,\*</sup> I. Escandell,<sup>a</sup> D. Ayala,<sup>a</sup> E. Jordá<sup>a,b</sup>

<sup>a</sup> *Servicio de Dermatología, Hospital Clínico Universitario, Valencia, Spain*

<sup>b</sup> *Departamento de Medicina, Universidad de Valencia, Valencia, Spain*

\*Corresponding author.

E-mail addresses: [Martin.josemaria@gmail.com](mailto:Martin.josemaria@gmail.com), [jmmart@eresmas.com](mailto:jmmart@eresmas.com) (J.M. Martín).

## Pityriasis Rotunda and Hyperprolactinemia<sup>☆</sup>



### Pitiriasis rotunda e hiperprolactinemia

To the Editor:

Pityriasis rotunda (PR) is a rare acquired disease of keratinization. It presents as well-defined, scaly round plaques that can be hyper- or hypopigmented. PR mainly affects young adults of African descent and shows no gender preference. It has been associated with systemic diseases and malignant tumors, though many cases present no associated disorders.<sup>1</sup> We present a case of intense PR associated with hyperprolactinemia.

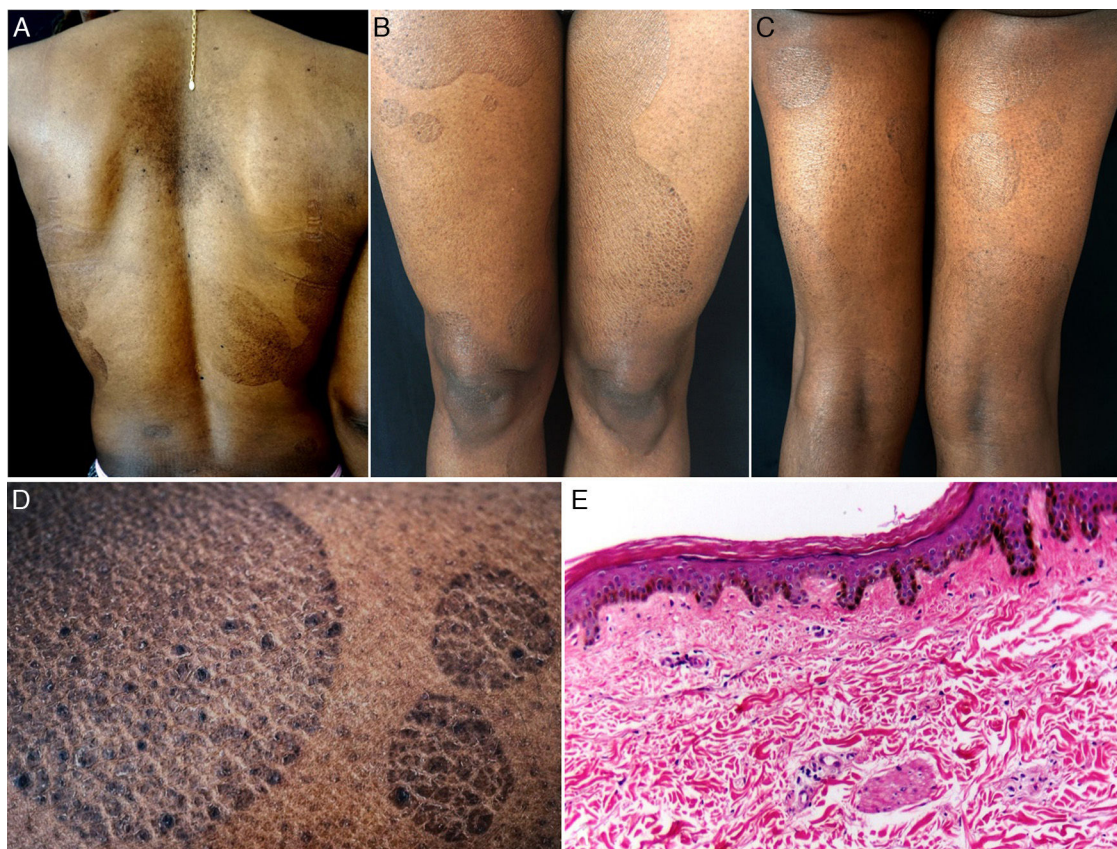
The patient was a 38-year-old African American woman with a history of hyperprolactinemia on treatment with

cabergoline for the previous 7 months. She attended dermatology outpatients for a 9-month history of sharply outlined, circumscribed hyperpigmented plaques of ichthyosiform appearance, measuring 3 to 15 cm in diameter (Fig. 1). The patient stated that the lesions had first appeared on her chest and that they had gradually increased in size and number, spreading to the abdomen, buttocks, and upper and lower limbs. She reported no associated symptoms or previous treatment. Histopathology revealed hyperkeratosis, parakeratosis, a reduction in the granular layer, increased pigmentation of the basal keratinocytes, loss of the crest pattern, and a mild superficial perivascular lymphocytic infiltrate (Fig. 1). The findings were consistent with a diagnosis of PR.

Laboratory tests including complete blood count, biochemistry, urinalysis, Mantoux test, and tumor markers ( $\alpha$ -fetoprotein, Ca 19.9, Ca 125,  $\beta_2$ -microglobulin, and carcinoembryonic antigen) were normal or negative. Computed tomography of the chest, abdomen, and pelvis, upper gastrointestinal endoscopy, and colonoscopy were normal.

After making the diagnosis, treatment was started with 10% salicylic acid cream and a combination of betamethasone plus calcipotriol, which led to a partial response.

<sup>☆</sup> Please cite this article as: Pinos-León V, Núñez M, Salazar M, Solís-Bowen V. Pitiriasis rotunda e hiperprolactinemia. *Actas Dermosifiliogr.* 2016;107:535-537.



**Figure 1** A, Hyperpigmented oval plaques on the back. B and C, Multiple oval lesions on the thighs. D, Close-up image showing ichthyosiform flaking with sharp, well-defined borders. E, Compact hyperkeratosis, thinning of the epidermis, absence of the granular layer, flattening of the epidermal crests, hyperpigmentation of the basal keratinocytes, a mild perivascular infiltrate, and few skin adnexa. Hematoxylin and eosin, original magnification  $\times 10$ .

PR, a rare disorder of keratinization, was described by Toyoma in 1906 as pityriasis circinata.<sup>2</sup> The frequency in the American continent is unknown, but it is considered a common disease in Japan, western India, and South Africa, where the prevalence is of 63 cases per 5800 population. PR affects the men and women equally and is most common between the ages of 20 and 45 years.<sup>3</sup>

The etiology is unknown, though the majority of authors believe PR to be an acquired form of ichthyosis, a late presentation of congenital ichthyosis, or a cutaneous manifestation of systemic diseases such as malnutrition, tuberculosis, cirrhosis, or tumors. It has also been associated with leprosy, lung and liver diseases, multiple myeloma, chronic myeloid leukemia, heart disease, and diabetes.<sup>4,5</sup>

Concerning the pathogenesis of PR, Makino et al.<sup>6</sup> recently described a reduction or absence of expression of filaggrin 2 in the epidermis of PR lesions, similar to the findings in lesions of atopic dermatitis, ichthyosis vulgaris, and psoriasis vulgaris.

Clinically, PR is characterized by the appearance of very well-defined, hyper- or hypopigmented circular plaques of ichthyosiform appearance, with no associated inflammatory signs. Lesions occur on the back, upper and lower limbs, abdomen, and buttocks; their number can vary between 1 and 100,<sup>1</sup> and they can persist for months to years, with exacerbations during the winter.<sup>4</sup>

Various changes can be seen on histopathology, including hyperkeratosis, flattening of the epidermal crests, a reduction or absence of the granular layer, hyperpigmentation of basal layer, mild spongiosis, comedo-like openings, incontinentia pigmenti, and a superficial perivascular infiltrate; the histopathological appearance may even be normal in some cases.<sup>1,4</sup>

Two subtypes have been proposed. Type 1, common in African American and Asian individuals, is characterized by a small number of hyperpigmented lesions in patients with no family history of the disease and it is associated with malignant and systemic diseases. Type 2, which, in contrast, is more common in white patients with a family history of the disease, presents more numerous, hypopigmented plaques and is not associated with malignant diseases.<sup>7</sup> Despite this classification, some reported cases show characteristics of both subtypes.<sup>4</sup>

The clinical differential diagnosis includes tinea versicolor, tinea corporis, nummular eczema, fixed drug reaction, erythrasma, pityriasis rosea, figurate erythema, and leprosy.<sup>1</sup>

Treatment is difficult in most cases. Topical corticosteroids, antifungal agents, salicylic acid, topical and oral retinoids, lactic acid lotions, and tars have been used without success.<sup>1,4</sup> Recently, treatment with vitamin D3 has produced a gradual improvement in the lesions.<sup>6</sup> When an

underlying disease is present, its treatment can lead to improvement or even resolution of the PR lesions.<sup>8</sup>

To our knowledge, this is the first reported case of PR associated with hyperprolactinemia, and we therefore consider its publication important. The finding of this dermatosis should always alert the physician to the possibility of malignancy, systemic diseases, or hormonal disorders.

## Conflicts of Interest

The authors declare that they have no conflicts of interest.

## References

1. Bakry OA, Samaka RM. Photoletter to the editor: Pityriasis rotunda. *J Dermatol Case Rep.* 2012;6:90–2.
2. Friedmann AC, Ameen M, Swale VJ. Familial pityriasis rotunda in black-skinned patients; a first report. *Br J Dermatol.* 2007;156:1365–7.
3. Swift PJ, Saxe N. Pityriasis rotunda in South Africa. A skin disease caused by undernutrition. *Clin Exp Dermatol.* 1985;10:407–12.
4. Batra P, Cheung W, Meehan SA, Pomeranz M. Pityriasis rotunda. *Dermatol Online J.* 2009;15:14.
5. Persechino S, Raffa S, Caperchi C, Visco V, Verga E, Trapolini M, et al. Pityriasis rotunda: Sporadic occurrence in an elderly Caucasian patient with diabetes mellitus. *Eur J Dermatol.* 2009;19:393–4.
6. Makino T, Mizawa M, Seki Y, Hayashi M, Shimizu T. Decreased filaggrin-2 expression in the epidermis in a case of pityriasis rotunda. *Clin Exp Dermatol.* 2015;1–3, <http://dx.doi.org/10.1111/ced.12716> [Epub ahead of print].
7. Grimalt R, Gelmetti C, Brusasco A, Tadini G, Caputo R. Pityriasis rotunda: Report of a familial occurrence and review of the literature. *J Am Acad Dermatol.* 1994;31:866–71.
8. Finch JJ, Olson CL. Hyperpigmented patches on the trunk of a Nigerian woman. Pityriasis rotunda (PR). *Arch Dermatol.* 2008;144:1509–14.

V. Pinos-León,<sup>a,b,\*</sup> M. Núñez,<sup>a,b</sup> M. Salazar,<sup>a,b</sup>  
V. Solís-Bowen<sup>a,b</sup>

<sup>a</sup> *Servicio de Dermatología, Hospital San Francisco de Quito, Instituto Ecuatoriano de Seguridad Social, Quito, Ecuador*

<sup>b</sup> *Universidad Central del Ecuador, Quito, Ecuador*

\* Corresponding author.

*E-mail addresses:* [vh\\_neo@msn.com](mailto:vh_neo@msn.com), [vhpinosmd@gmail.com](mailto:vhpinosmd@gmail.com) (V. Pinos-León).

## Good Response to Doxycycline in Hailey-Hailey Disease<sup>☆</sup>



### Enfermedad de Hailey-Hailey, adecuada respuesta a doxiciclina

*To the Editor:*

Hailey-Hailey disease (HHD) or familial benign chronic pemphigus is a rare skin disorder characterized clinically by vesicles and erosions in the intertriginous areas, mainly the axillae and groin.<sup>1–4</sup> The site of the lesions, the pain, and sometimes their smell have a marked impact on patients' quality of life<sup>5</sup>; this has led to the use of numerous medical and surgical treatments, with variable degrees of success. We present a patient with long-standing, extensive HHD who presented an excellent response to doxycycline.

A 60-year-old man with no past history of interest was referred from another health area for a recurrent dermatosis that had arisen 20 years earlier and affected the skin folds. He presented crusted, exudative, erosive-vesicular lesions in the skin folds, particularly the axillary and inguinal folds (Fig. 1), the cubital fossa, neck, and perineum. The lesions were pruritic and painful and became worse during the summer and with exercise. He had previously been treated with corticosteroids and topical antibiotics with little improvement. The patient reported no family history

of skin disease, though the youngest of his 4 offspring (2 women and 2 men) presented similar but milder lesions on the neck and in the axillae. Biopsy confirmed the diagnosis of HHD (Fig. 2). Direct immunofluorescence was negative. Routine blood tests were normal and antinuclear antibodies and indirect immunofluorescence for anti-intercellular cement substance and antibasement membrane zone antibodies were negative.

Treatment was prescribed with doxycycline at a dose of 100 mg/d. This was very well tolerated and led to a rapid improvement that was maintained throughout the summer months. The dose was then reduced to 50 mg/d. After 16 months of follow-up on the same dose, the patient remained asymptomatic (Fig. 3).

HHD is a rare chronic genodermatosis of autosomal dominant inheritance. It is caused by mutations in the *ATP2C1* gene on chromosome 3q21-24. Mutations of this gene, which codes for the secretory pathway  $\text{Ca}^{++}/\text{Mn}^{++}$ -ATPase (SPCA1) of the Golgi apparatus, cause changes in calcium-dependent intracellular signals, producing a loss of cell adhesion in the epidermis, leading to acantholysis.<sup>1–3</sup> The exact mechanism of the changes remains unclear.<sup>2,3</sup>

HHD has been treated with varying degrees of success using a variety of treatments aimed at mitigating the inflammation or reducing the triggering factors; treatments reported in the literature include topical and systemic corticosteroids, topical antibiotics, oral retinoids, immunosuppressants such as ciclosporin and methotrexate, dapsone, botulinum toxin, oral glycopyrrolate, dermabrasion, various lasers, and photodynamic therapy.<sup>6</sup>

Tetracycline, doxycycline, and minocycline have been used with success in dermatology, exploiting their nonantimicrobial effects as anti-inflammatory agents (inhibition of leucocyte chemotaxis and activation and regulation of

<sup>☆</sup> Please cite this article as: Flores-Terry MÁ, Cortina-de la Calle MP, López-Nieto M, Cruz-Conde de Boom R. Enfermedad de Hailey-Hailey, adecuada respuesta a doxiciclina. *Actas Dermosifiliogr.* 2016;107:537–539.