

5. Lofgren SM, Warshaw EM. Dyshidrosis: Epidemiology, clinical characteristics, and therapy. *Dermatitis*. 2006;17:165–81.
6. Pemira SM, Tolan RW Jr. Mycoplasma pneumoniae infection presenting as bullous papular purpuric gloves and socks syndrome: Novel association and review of the literature. *Clin Pediatr (Phila)*. 2011;50:1140–3.
7. Winer JB. An update in Guillain-Barré syndrome. *Autoimmune Dis*. 2014;2014. ID793024.

A.A. Garrido-Ríos,* C. Martínez-Morán, J. Borbujo

Servicio de Dermatología, Hospital Universitario de Fuenlabrada, Fuenlabrada, Madrid, Spain

*Corresponding author.

E-mail address: natachagarrido@hotmail.com
(A.A. Garrido-Ríos).

Self-healing Collodion Baby: A New Mutation in the *ALOX12B* Gene[☆]



Bebé colodión autorresolutivo: nueva mutación en el gen *ALOX12B*

Dear Editor:

We present the case of a newborn infant born preterm at 36 weeks, with no family history of interest, diagnosed in utero with eclabium and ectropion, with a suspected diagnosis of harlequin fetus. At birth, the infant presented a membrane that covered practically the whole body surface like a suit of armor (Fig. 1A), in addition to ectropion, eclabium, clawed-hand deformity (Fig. 1B), and retraction of the auricles of both ears (Fig. 1C). During the first days after delivery, the membrane fissured and subsequently peeled away in large sheets (Fig. 1D), leaving the underlying skin erythematous and exudative; the membrane had fallen completely by the second week of life. The clinical course was very good over the following months, and at 1 year the skin had a practically normal appearance (Fig. 2A), showing only mild erythema and peeling on both cheeks (Fig. 2B) and minimal hyperkeratosis on the elbows and knees. A diagnosis of self-healing collodion baby (CB) was made. Genetic analysis showed the child to be a homozygous carrier of a mutation in the *ALOX12B* gene that produced loss of an amino acid, glutamine, at position 136 of exon 3; the parents were healthy heterozygous carriers of this mutation. At the time of writing this article, the patient was 2 years of age and had no lesions except those commented above.

CB presents at birth with a tight, shiny, transparent, armor-like membrane that covers the whole body surface and looks like cellophane wrapping.^{1,2} This can give rise to ectropion, eclabium, pseudocontractures, absence of eyebrows, sparse hair, and hypoplasia of the nasal and auricular cartilage.^{1,2} The membrane is inelastic, so the child's breathing and movements after birth provoke fissuring, and it then peels away in large sheets and is completely lost by 2 to 4 weeks of life.³ CB is a rare condition, with an incidence between 1 in 50 000 to 1 in 100 000 births. It is the initial clinical manifestation of a number of genetic diseases, the majority of which belong to the group of autosomal recessive congenital ichthyoses (ARCI).⁴ CB can

develop into very diverse phenotypes, from skin with a normal appearance to intense ichthyosis; the majority of patients are diagnosed with lamellar ichthyosis or congenital ichthyosiform erythroderma.^{1,3} Self-resolving CB is a minor form of ARCI.⁴ Between 10% and 24% of cases of CB are self-resolving; these are cases that show spontaneous resolution of the condition and in adult life present a normal skin or discreet signs of ichthyosis.^{1,5} Regarding the epidemiology of ARCI, Hernández-Martín et al., in Spain, published a study in which the estimated prevalence of ARCI was of approximately 16 cases per million population, with a prevalence of self-resolving CB of 4.2% in the overall ARCI population.⁶

Self-resolving CB has been associated with mutations in genes *TGM1*, *ALOXE3*, and *ALOX12B*.^{1,3–5,7} Our patient was diagnosed as a homozygous carrier of a mutation in gene *ALOX12B* that has not previously been described in the literature. The *ALOX12B* gene was first identified in 2002. It is formed of 15 exons and codes for the epidermal lipoxigenases eLOX-3 and 12R-LOX.⁸ Its predominant expression in the suprabasal layers of the epidermis supports its role in the advanced phases of epidermal differentiation and its participation in processing lamellar bodies. In addition, it acts in the hepxilin pathway and is therefore thought possibly to participate in the formation of the intercellular lipids of the corneal layer or to act in signaling to promote keratinocyte differentiation.⁸

More than 30 mutations of the *ALOX12B* gene have been described since its identification and, together with gene *ALOXE3*, it is considered responsible for 14% to 17% of ARCI and for 72.2% of cases of self-resolving CB.⁸ The specific mechanism that leads to the changes in skin permeability in patients with alterations of gene *ALOX12B*, and the reason for the appearance of lesions in the neonatal period in self-resolving CB, are not fully understood.⁷ It has been postulated that these mutations of *ALOX12B* reduce enzyme activity in utero, but not after birth.⁸ Hydrostatic pressure is high in the uterus, and the chelation of water molecules deforms the mutated enzyme into an inactive conformation. After birth, with a lower hydrostatic pressure, the enzyme returns to its active form and increases its activity to levels sufficient to maintain a normal or minimally altered phenotype.^{8,9}

CB usually causes premature delivery, with increased perinatal morbidity and mortality. Important complications include increased transepidermal water loss (up to 7 times the loss from healthy skin), temperature instability, hypothermia, hypernatremic dehydration, feeding difficulties, hypohidrosis, cutaneous and systemic infections, ectropion, keratitis, and obstruction of the external auditory meatus.^{1,2,5,10} Furthermore, the membrane can

[☆] Please cite this article as: Muruzábal RS, Irurzun AL, Bayona IY, Arroyo MAR. Bebé colodión autorresolutivo: nueva mutación en el gen *ALOX12B*. *Actas Dermosifiliogr*. 2016;107:433–435.

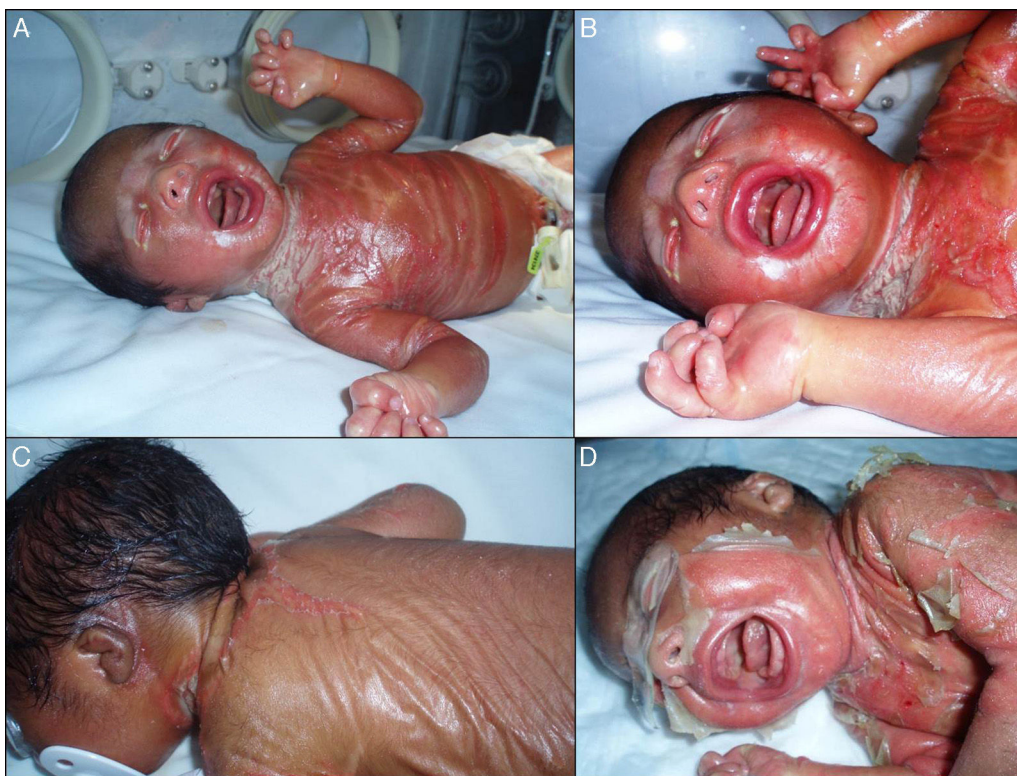

Figure 1 A, Shiny membrane covering practically the whole body surface like a suit of armor. B, Ectropion, eclabium, and clawed-hand deformity. C, Retraction of the auricle of the left ear and view of the membrane over the back with a central fissure in the dorsal region. D, Peeling of the whole membrane in large sheets.

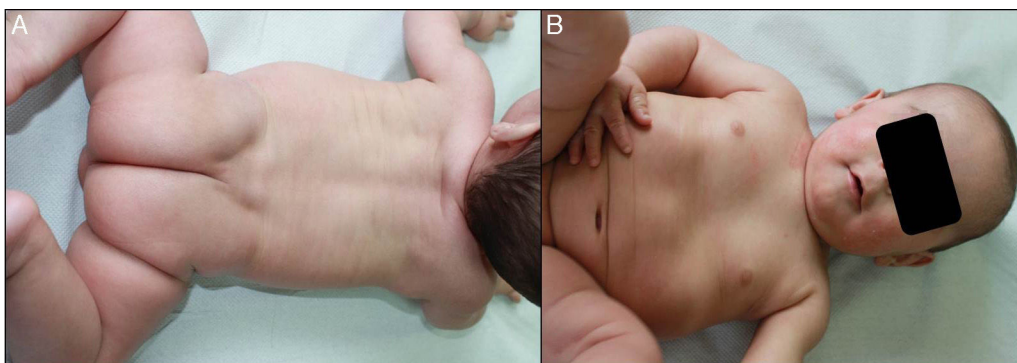


Figure 2 A and B, Normal skin at age 1 year, with only mild erythema and peeling on the cheeks.

produce mechanical compression that may lead to distal limb ischemia.²

The management of CB must be undertaken in a neonatal intensive care unit. Humidity in the incubator should be at least 60%, with temperature control, monitoring of electrolytes, energy supplementation, and insertion of a nasogastric tube if feeding is compromised. Although prophylactic antibiotics are not recommended, very close monitoring must be performed and antibiotic therapy initiated early if signs of infection develop.² The use of emollients reduces transepidermal water loss and its related complications, though health staff must perform adequate hand washing and hygiene prior to applying the agents in order to reduce the risk of infection, as this has been related to the application of emollients in some reports.²

Mortality in CB is currently around 5%; in 1960 it was estimated to be around 50%.^{2,10} It is believed that the marked improvement in prognosis is due to the advances in neonatal care.²

Reporting this new case of CB is important because of its progression to self-resolving CB, a very rare entity. Self-resolving CB is a challenge not because of diagnostic problems, but rather because of the difficulty in establishing a long-term prognosis, as it is impossible to say whether a case will be a true self-resolving CB or whether it will, in contrast, develop into a very severe disease. Furthermore, the genetic analysis performed on our patient detected a mutation in the *ALOX12B* gene that had not previously been described in the literature as a mutation confirmed to cause self-resolving CB.

Conflicts of Interest

The authors declare that they have no conflicts of interest.

References

- Theiler M, Mann C, Weibel L. Self-healing collodion baby. *J Pediatr*. 2010;157:169-169e1.
 - Prado R, Ellis LZ, Gamble R, Funk T, Arbuckle HA, Bruckner AL. Collodion baby: An update with a focus on practical management. *J Am Acad Dermatol*. 2012;67:1362-74.
 - Tanahashi K, Sugiura K, Asagoe K, Aoyama Y, Iwatsuki K, Akiyama M. Novel TGM1 missense mutation p.Arg727Gln in a case of self-healing collodion baby. *Acta Derm Venereol*. 2014;94:589-90.
 - Oji V, Tadini G, Akiyama M, Blanchet Bardon C, Bodemer C, Bourrat E, et al. Revised nomenclature and classification of inherited ichthyoses: Results of the First Ichthyosis Consensus Conference in Sorèze 2009. *J Am Acad Dermatol*. 2010;63:607-41.
 - Vahlquist A, Bygum A, Gånemo A, Virtanen M, Hellström-Pigg M, Strauss G, et al. Genotypic and clinical spectrum of self-improving collodion ichthyosis: ALOX12B, ALOXE3, and TGM1 mutations in Scandinavian patients. *J Invest Dermatol*. 2010;130:438-43.
 - Hernández-Martín A, García-Doval I, Aranegui B, de Unamuno P, Rodríguez-Pazos L, González-Enseñat MA, et al. Prevalence of autosomal recessive congenital ichthyosis: A population-based study using the capture-recapture method in Spain. *J Am Acad Dermatol*. 2012;67:240-4.
 - Harting M, Brunetti-Pierri N, Chan CS, Kirby J, Dishop MK, Richard G, et al. Self-healing collodion membrane and mild nonbullous congenital ichthyosiform erythroderma due to 2 novel mutations in the ALOX12B gene. *Arch Dermatol*. 2008;144:351-6.
 - Rodríguez-Pazos L, Ginarte M, Vega A, Toribio J. Autosomal recessive congenital ichthyosis. *Actas Dermosifiliogr*. 2013;104:270-84.
 - Raghunath M, Hennies HC, Ahvazi B, Vogel M, Reis A, Steinert PM, et al. Self-healing collodion baby: a dynamic phenotype explained by a particular transglutaminase-1 mutation. *J Invest Dermatol*. 2003;120:224-8.
 - Van Gysel D, Lijnen RL, Moekti SS, de Laat PC, Oranje AP. Collodion baby: A follow-up study of 17 cases. *J Eur Acad Dermatol Venereol*. 2002;16:472-5.
- R. Santesteban Muruzábal,^{a,*} A. Larumbe Irurzun,^a
I. Yanguas Bayona,^a M.A. Ramos Arroyo^b
- ^a *Servicio de Dermatología, Complejo Hospitalario de Navarra, Pamplona, Spain*
^b *Servicio de Genética, Complejo Hospitalario de Navarra, Pamplona, Spain*
- * Corresponding author.
E-mail address: raquel.santesteban@hotmail.com
(R. Santesteban Muruzábal).

A Familial Form of Primary Essential Cutis Verticis Gyrata[☆]



Forma familiar de *cutis verticis gyrata* primario esencial

Dear Editor:

Cutis verticis gyrata (CVG) is a rare skin condition characterized by thickening of the scalp, giving rise to convolutions and sulci, with a cerebriform pattern. CVG is classified as primary (essential and nonessential) or secondary.

We present 2 cases of primary essential CVG in a single family. The 2 men (patients 1 and 2) were siblings of 32 and 28 years of age, with no other relevant family history. They presented progressive thickening of the scalp that had started in adolescence. Physical examination revealed anterior-posterior folds on the scalp of both patients (Fig. 1) and mild subungual hyperkeratosis and distal onycholysis of the nail plates of the great toes of both feet.

Detailed dermatologic and systemic medical history and physical examination, including endocrine and neurologic evaluation, detected none of the abnormalities associated with the primary nonessential forms. Scalp biopsy revealed a mild nonspecific superficial periadnexal and perivascular

mononuclear inflammatory infiltrate in both patients. The following studies were performed to exclude causes of secondary CVG: plain x-rays of both hands, cerebral computed tomography (CT), routine blood tests with thyroid function, lipid profile, insulin-like growth factor 1, antinuclear antibodies, and syphilis serology. The cerebral CT of patient 1 showed the skin folds affecting the scalp (Fig. 2). Other studies were normal or negative. Studies of the nail alterations (culture and histopathology) were only positive in patient 2 (growth of *Trichophyton interdigitale*), and treatment was prescribed with oral terbinafine (250 mg/24 h for 3 months). Genetic analysis was not performed in either patient.

Primary essential CVG is most common in postpubertal men.¹ The etiology is unknown, but genetic and endocrine factors are believed to be implicated.² The majority of cases of primary essential CVG are sporadic, although familial forms with autosomal dominant or recessive inheritance with variable expression have been reported.^{3,4} The prevalence data for the general population date from 1964, with an estimated prevalence among men and women of 1 and 0.026 cases per 100 000 population, respectively.⁵

The primary essential form is not associated with other abnormalities, in contrast to the primary nonessential form, which can be associated with mental retardation, cerebral palsy, epilepsy, schizophrenia, deafness, and cranial and ophthalmologic abnormalities.⁶ The secondary forms of CVG can be associated with numerous underlying diseases, such as pachydermoperiostosis, acromegaly, cutis laxa, cylindroma, cerebriform intradermal nevus,

[☆] Please cite this article as: Suh H, Flórez-Menéndez Á, de La Torre-Fraga C. Forma familiar de *cutis verticis gyrata* primario esencial. *Actas Dermosifiliogr*. 2016;107:435-437.