



ACTAS Dermo-Sifiliográficas

Full English text available at
www.actasdermo.org



IMAGES IN DERMATOLOGY

Generalized Keratosis Lichenoides Chronica[☆]



Queratosis liquenoide crónica generalizada

R. Santesteban-Muruzábal,* M. Larrea-García, I. Yanguas-Bayona

Servicio de Dermatología, Complejo Hospitalario de Navarra, Pamplona, Navarra, Spain

In a 38-year-old man, we observe violaceous hyperkeratotic desquamative plaques that coalesce to form a reticular pattern occupying almost the entire body surface area (Fig. 1A and B). The lesions first appeared 5 years earlier. The biopsy shows a patchy lichenoid infiltrate centered around the infundibula (Fig. 1C), vacuolar degeneration at the dermal-epidermal junction, acanthosis, tiered parakeratosis, and necrotic keratinocytes (Fig. 1D). With these observations, it was possible to diagnose generalized keratosis lichenoides chronica (KLC).

KLC is a very uncommon inflammatory disease of unknown pathogenesis that presents as violaceous hyperkeratotic papules and plaques resembling lichen planus. The lesions can follow a linear and/or reticular pattern. It is a symmetrical and bilateral disorder that involves the trunk and limbs and, less frequently, the neck and feet. It may even on occasions become generalized. It usually first presents in young adults, with no predilection for sex or race. Facial lesions similar to seborrheic eczema or perioral dermatitis may also occur, as well as other processes such as palmoplantar keratoderma and nail dystrophy. Treatment is often complicated given the lack of response.

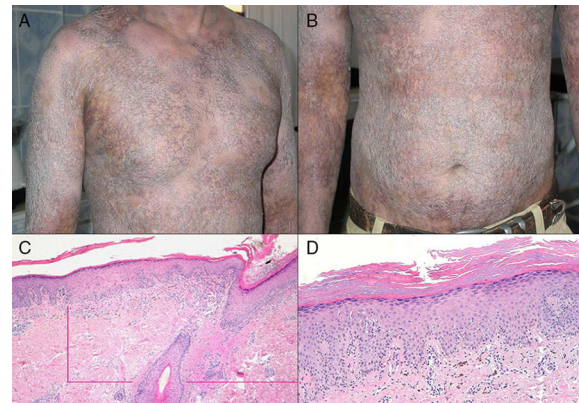


Figure 1

This case is noteworthy given the generalized form the disease. The fact that the condition was allowed to progress so far can be explained by the lack of medical care received as the patient was living in a refugee camp without any access to specialized care.

[☆] Please cite this article as: Santesteban-Muruzábal R, Larrea-García M, Yanguas-Bayona I. Queratosis liquenoide crónica generalizada. Actas Dermosifiliogr. 2016;107:249.

* Corresponding author.

E-mail address: raquel.santesteban@hotmail.com
(R. Santesteban-Muruzábal).