

Primary cutaneous small-to-medium-sized CD4+ T-cell lymphoma with a granulomatous component[☆]



Linfoma cutáneo primario T CD4+ de célula pequeña/mediana, granulomatoso

To the Editor:

We describe a patient with primary cutaneous small-to-medium-sized CD4+ T-cell lymphoma, according to the most recent World Health Organization (WHO) classification of cutaneous lymphomas.¹

This lymphoma, previously known as primary cutaneous small-to-medium-sized pleomorphic CD4+ T-cell lymphoma,¹ has a low incidence and good prognosis. The interest in the case presented in this report derives from a substantial granulomatous component in the

clinical-pathological study and the self-healing nature of the lesion. We discuss the possibility of a relationship between these 2 characteristics.

The patient was a 32-year-old woman with no clinical history of relevance who attended the clinic in December, 2012, due to a cutaneous lesion on the right breast related to an insect bite 3 months earlier. The lesion consisted of an itchy erythematous nodule measuring 2 cm in diameter with a smooth surface (Fig. 1). Biopsy showed a dense and diffuse infiltrate that occupied the entire thickness of the dermis, composed of small and medium sized cells alongside some eosinophils (Fig. 1). Epidermotropism was scarce. Abundant histiocytes and multinucleated giant cells were also observed, forming granulomatous aggregates (Fig. 2), interspersed with lymphoid proliferation. Immunohistochemistry showed CD3+ and CD4+ cells that were however negative for CD8 and CD30 (Fig. 3). Molecular study of the λ chain of the T-cell receptor showed monoclonal rearrangement, and so the patient was diagnosed with primary cutaneous granulomatous small-to-medium sized CD4+ T-cell lymphoma. An

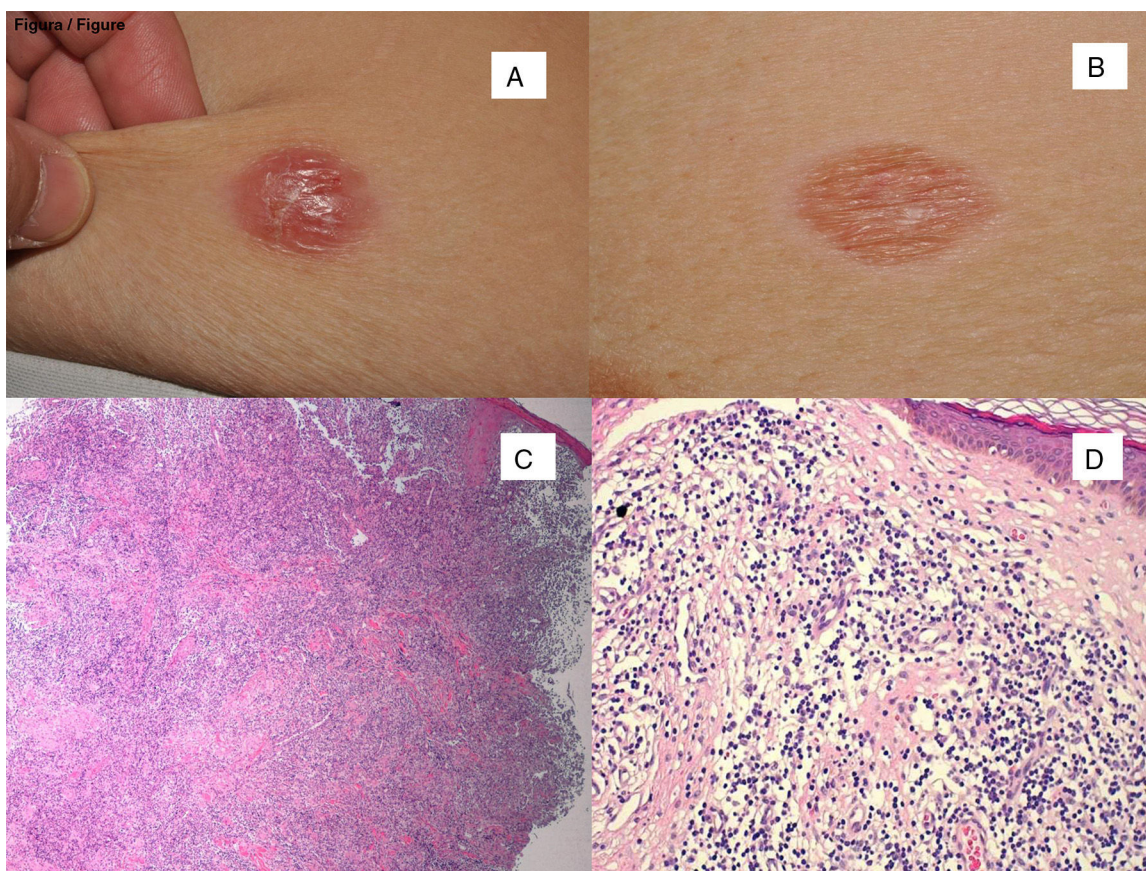


Figure 1 Clinical images of the lesion. A, At the first visit. B, 2 months later, with self-resolution. Histological appearance of the biopsies corresponding to the clinical images immediately above, with partial reduction of the tumor infiltrate in the second of them. C, Hematoxylin-eosin (H-E), x40. D, H-E, x400.

[☆] Please cite this article as: García de la Fuente MR, Vilardell-Villellas F, Martí-Laborda RM, Casanova-Seuma JM. Linfoma cutáneo primario T CD4+ de célula pequeña/mediana, granulomatoso. *Actas Dermosifiliogr.* 2016;107:89–91.

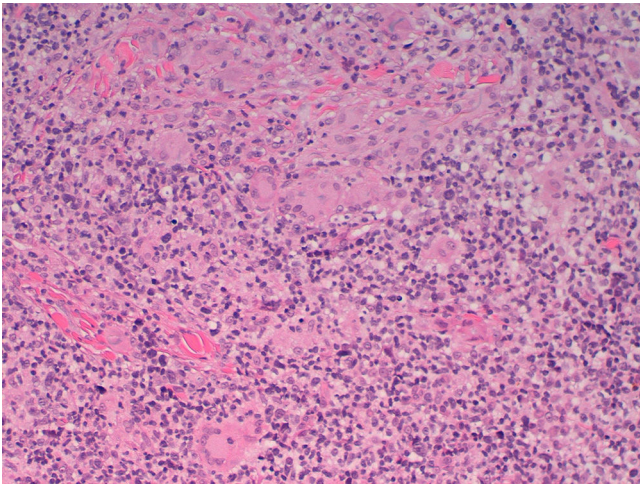


Figure 2 Histological appearance. Of note is the presence of numerous multinucleated giant cells (H-E, x200).

extension study was conducted, including study with lymphoid subpopulations, LDH, β 2-microglobulin, and positron emission tomography-computed tomography, with normal results. Surgical resection was proposed. On the day of surgery, 2 months later, the nodule had disappeared to leave a residual erythematous macule (Fig. 1). Excision biopsy of the lesion showed a considerable reduction in lymphoid infiltrate, but this remained positive for CD20, CD3, and

CD68, with predominance of CD4 over CD8; the infiltrate was negative for CD30. The same monoclonal pattern persisted.

The patient is still in follow-up in our department and is disease free after 2 years.

Primary cutaneous small-to-medium-sized CD4+ T-cell lymphoma is a rare T-cell lymphoid proliferation that usually presents as a single lesion on the head or trunk and whose histology findings coincide with the case described.^{2,3} Prognosis is good, with 5-year survival of 80%, with good response to chemotherapy or surgery. In aggressive cases, with multiple lesions, polychemotherapy such as CHOP is used.

The association of cutaneous lymphoma and granuloma is rare although well known. The presence of lymphoma and granuloma in biopsy can lead to erroneous diagnosis and enable the disease to progress undetected for months.⁴

In the literature review, this phenomenon occurs most frequently in mycosis fungoides and its clinical variant granulomatous slack skin,⁵ but there have also been isolated reports in Sézary syndrome,^{6,7} anaplastic CD30+ lymphoma,⁸ panniculitis-type T lymphoma,⁸ follicle center lymphoma,⁸ and in 4 cases of primary cutaneous small-to-medium-sized CD4+ T-cell lymphoma.⁸ A lymphoma is considered granulomatous when the granulomas occupy at least 25% of the infiltrate.⁹ This finding occurs in 1.8% of all cutaneous lymphomas.

It is not known whether the granuloma occurs as an immune response of the host to tumor cells or is a result of cytokine release, contributing to better prognosis.

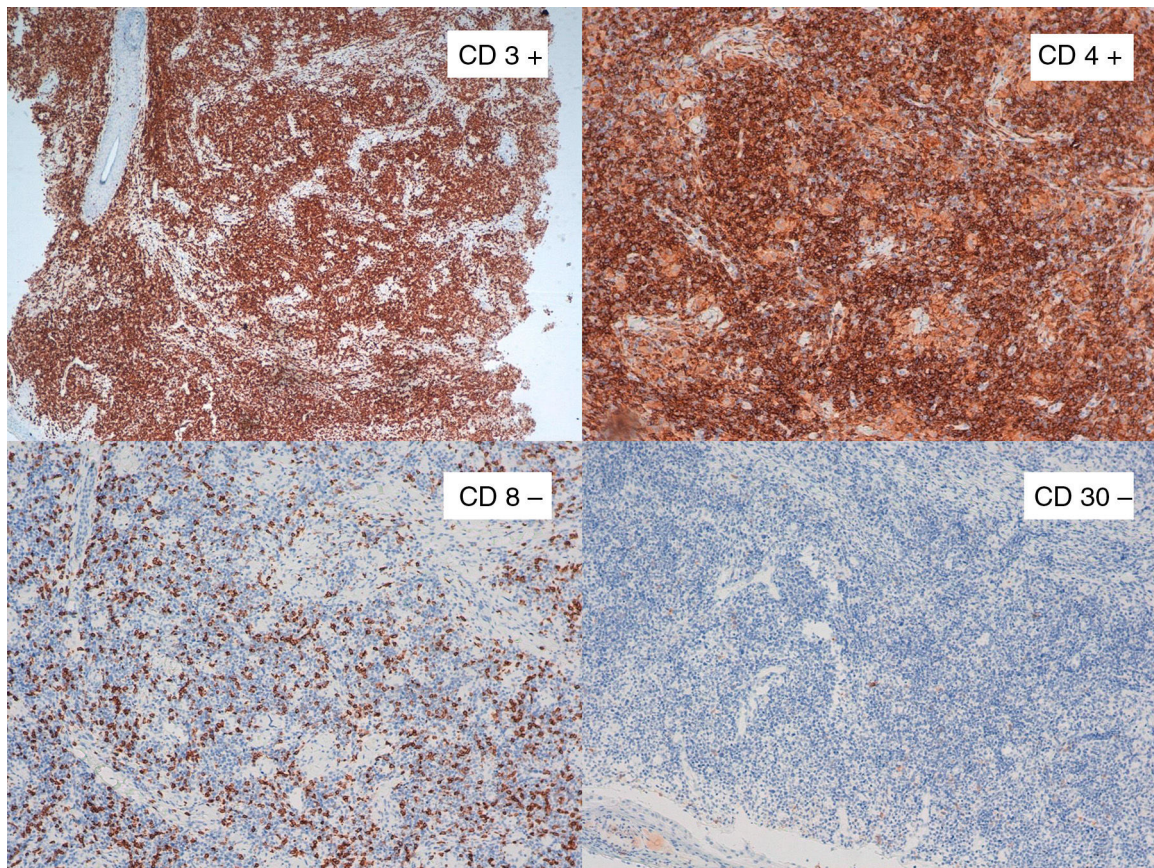


Figure 3 In the immunohistochemical study, of note was positivity for CD3 and CD4 in the upper images and negativity for CD8 and CD30 in the lower ones. The limited staining for CD8 corresponds to accompanying cellularity and not tumoral cellularity.

Beltraminelli et al.² went as far as to suggest that small granulomas could be secondary to destruction of skin appendages.

The extent to which this immune reaction could influence the prognosis of lymphoma has also not been established. Granulomatous cutaneous lymphomas normally have a slowly progressive course, although around 50% develop nodal lymphomas with a fatal outcome.

The incongruence between histological findings (pleomorphism, appendage destruction, T-cell monoclonality) and the favorable clinical outcome with a high percentage of remissions seems paradoxical. Histology and immunohistochemistry are, for the time being, not helpful in this case. The monoclonality found in the infiltrate is suggestive of a malign lymphoproliferative process but this finding is not exclusive as reactive inflammatory processes and other processes of unknown significance can also be monoclonal.² The pattern of PD-1 immunoreactivity, which we could not determine in our case, may have helped in the diagnosis of primary cutaneous small-to-medium-sized CD4+ T-cell lymphoma.¹⁰

Patients with solitary lesions usually have an indolent course. Aggressive treatments should be avoided and these patients should be managed differently to those with multiple cutaneous lesions, in whom prognosis may not be favorable.

In summary, we describe a case of granulomatous primary cutaneous small-to-medium-sized CD4+ T-cell lymphoma with partial self-resolution. The lymphoma has remained in complete remission after surgical excision. Although the presence of granulomas in the histology may hinder diagnosis of the primary tumor,⁹ and enable its progression, in other cases it may be a true host-versus-tumor reaction and favor self-resolution.

References

1. Cerroni L, Wiesner T. Cutaneous lymphomas: From morphology to chip technology. *Actas Dermosifiliogr.* 2009;100 Suppl. 1: 3–17.
2. Beltraminelli H, Leinweber B, Kerl H, Cerroni L. Primary cutaneous CD 4+ small/medium sized pleomorphic T-cell lymphoma: A cutaneous nodular proliferation of pleomorphic T lymphocytes of undetermined significance? A study of 136 cases. *Am J Dermatopathol.* 2009;31:317–22.
3. Messegueur F, Gimeno E, Agusti-Mejias A, San Juan J. Primary cutaneous CD4+ small to medium sized pleomorphic T-cell lymphoma: Report of a case with spontaneous resolution. *Actas Dermosifiliogr.* 2011;102:636–8.
4. Brady B, Kamel D, Kiely J, Hennessy B. Dual diagnosis of sarcoidosis and lymphoma. *Ir J Med Sci.* 2013;182:283–6.
5. Shah A, Safaya A. Granulomatous slack skin disease: A review, in comparison with mycosis fungoides. *J Eur Acad Dermatol Venereol.* 2012;26:1472–8.
6. Dabiri S, Morales A, Ma L, Sundram U, Kim YH, Arber DA, et al. The frequency of dual TCR-PCR clonality in granulomatous disorders. *J Cutan Pathol.* 2011;38:704–9.
7. Carrozza PM, Kempf W, Kazakov DV, Dummer R, Burg G. A case of Sézary's syndrome associated with granulomatous lesions, myelodysplastic syndrome and transformation into CD30-positive large-cell pleomorphic lymphoma. *Br J Dermatol.* 2002;147:582–6.
8. Gallardo F, García-Muret MP, Servitje O, Estrach T, Bielsa I, Salar A, et al. Cutaneous lymphomas showing prominent granulomatous component: Clinico-pathological features in a series of 16 cases. *J Eur Acad Dermatol Venereol.* 2009;23:639–47.
9. Scarabello A, Leinweber B, Ardigó M, Rütten A, Feller AC, Kerl H, et al. Cutaneous lymphomas with prominent granulomatous reaction: A potential pitfall in the histopathologic diagnosis of cutaneous T- and B-cell lymphomas. *Am J Surg Pathol.* 2002;26:1259–68.
10. Cetinözman F, Jansen PM, Willemze R. Expression of programmed death-1 in primary cutaneous CD4-positive small/medium-sized pleomorphic T-cell lymphoma, cutaneous pseudo-T-cell lymphoma, and other types of cutaneous T-cell lymphoma. *Am J Surg Pathol.* 2012;36:109–16.

M.R. García de la Fuente,^{a,*} F. Vilardell-Villellas,^b
R.M. Martí-Laborda,^a J.M. Casanova-Seuma^a

^a Servicio de Dermatología, Hospital Universitario Arnau de Vilanova, Lérida, Spain

^b Servicio de Anatomía Patológica, Hospital Universitario Arnau de Vilanova, Lérida, Spain

* Corresponding author.

E-mail address: mrgarcia_dlf@hotmail.com
(M.R. García de la Fuente).

Intradermal Lipoblastoma-Like Tumor of the Lip in an Adult Woman



Lipoblastoma intradérmico tumor tipo en el labio de una mujer adulta

Dear Editor:

Lipoblastoma is a benign adipocytic tumor consisting of lobulated, immature white fat cells with a prominent capillary pattern and, frequently, a focal myxoid matrix.¹ The tumor can be localized or diffuse, occurs predominantly in infancy and early childhood, and affects patients aged 5 years or younger in 84% of cases.² Nevertheless, rare cases have been

reported in adolescents and adults.^{3,4} Most lipoblastomas are subcutaneous lesions affecting the arms and legs, and they are more common in male patients.²

We report the case of a distinctive mesenchymal neoplasm of the lip showing adipocytic differentiation in an adult woman. We consider that this tumor is akin to infantile lipoblastoma. As far as we are aware, only 1 such lesion has been previously reported.⁵

A 36-year-old woman presented with a history of a small asymptomatic, pigmented, raised nodule on the vermilion border of the lower lip that had been present for about 9 months. The patient had not undergone lip piercing, filler injection for lip augmentation, or any other interventions. Her past medical history was not significant for systemic disease. Physical examination revealed a soft, brown-colored, sessile nodule measuring 0.8 × 0.4 cm on the right half of