

phenazines from a fluorescent *Pseudomonas* strain FPO4 against medically important fungi. *J Mycol Med.* 2014;24:185–92.

7. Kerr JR, Taylor GW, Rutman A, Høiby N, Cole PJ, Wilson R. *Pseudomonas aeruginosa* pyocyanin and 1-hydroxyphenazine inhibit fungal growth. *J Clin Pathol.* 1999;52:385–7.
8. Yang YS, Ahn JJ, Shin MK, Lee MH. *Fusarium solani* onychomycosis of the thumbnail coinfecting with *Pseudomonas aeruginosa*: Report of two cases. *Mycoses.* 2011;54:168–71.
9. Ranjbariyan A, Shams-Ghahfarokhi M, Razzaghi-Abyaneh M. Antifungal activity of a soil isolate of *Pseudomonas chlororaphis* against medically important dermatophytes and identification of a phenazine-like compound as its bioactive metabolite. *J Mycol Med.* 2014;24:e57–64.
10. Selden ST, Flowers F, Vinson RP. Intertrigo Clinical Presentation. Available at: <http://emedicine.medscape.com/article/1087691-workup>.

C. Aspiroz,^a C. Toyas,^b P. Robres,^a Y. Gilaberte^{c,d,*}

^a Servicio de Microbiología, Hospital Royo Villanova, Zaragoza, Spain

^b Servicio de Medicina Interna, Hospital Royo Villanova, Zaragoza, Spain

^c Servicio de Dermatología, Hospital San Jorge, Huesca, Spain

^d Instituto Aragonés de Ciencias de la Salud, Zaragoza, Spain

*Corresponding author.

E-mail addresses: ygilaberte@salud.aragon.es, ygilaberte@gmail.com (Y. Gilaberte).

Acquired Facial Hyperpigmented Macules in Children: 3 New Cases[☆]



Máculas hiperpigmentadas faciales adquiridas en la infancia: 3 nuevos casos

To the Editor:

Acquired hyperpigmented facial macules were recently described in 25 children.¹ This condition is characterized by the appearance of multiple, asymptomatic, hyperpigmented macular lesions on the forehead and in the temporal region with no segmental distribution and without the previous presence of erythema, edema, or desquamation. The mean age at presentation was 6 months (range, 2-24 months). The condition affected children of different races, and there was no history of similar lesions among family members or close contacts. We describe 3 new cases.

Case Descriptions

A 3-year-old girl with no past medical history of interest presented a number of asymptomatic hyperpigmented macules that had arisen spontaneously on the forehead and in the temporal region 4 months earlier (Fig. 1A). The lesions did not present desquamation, Darier sign was negative, and there was no history of inflammation in the affected area. The rest of the physical examination was normal. Her sister aged 2 years, diagnosed with atopic dermatitis, presented macules of similar characteristics in the same areas (Fig. 1B). Onset of the lesions occurred simultaneously in the 2 girls, during the winter months. Likely triggering factors were investigated but no relevant suspicious factors were detected. The other members of the family and closest contacts did not present any lesions. The adhesive tape test revealed no structures suggestive of a superficial mycosis,

but remnants of pink-colored fibrillary structures were found on the surface of the adhesive tape; under polarized light, these fibers appeared synthetic (Fig. 2). At the 12-month follow-up the lesions persisted, but both girls presented a good general state of health, with no symptoms suggestive of systemic alterations.

The third patient was a 1-year-old girl of South American origin. She also presented asymptomatic hyperpigmented macules in the frontotemporal region. The macules had appeared during the first week of life and had remained clinically stable (Fig. 3). Immune studies including antinuclear antibodies and extractable nuclear antigen antibodies were performed on the girl and her mother and were negative.

Skin biopsy was not performed on any of the girls because of their age and the site and benign appearance of the lesions.

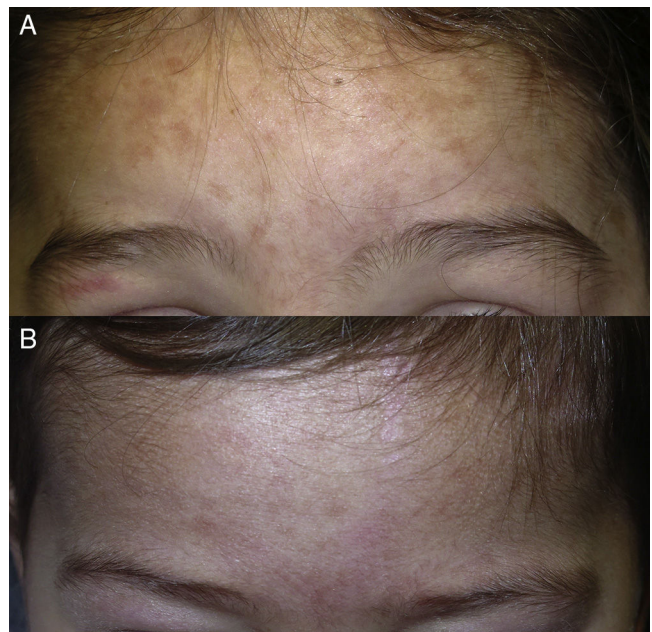


Figure 1 A, Hyperpigmented macules in the frontotemporal region of a 3-year-old white girl. B, The same lesions in her 2-year-old sister.

[☆] Please cite this article as: Giacaman A, Knöpfel N, Campos M, Martín-Santiago A. Máculas hiperpigmentadas faciales adquiridas en la infancia: 3 nuevos casos. *Actas Dermosifiliogr.* 2016;107:83–85.

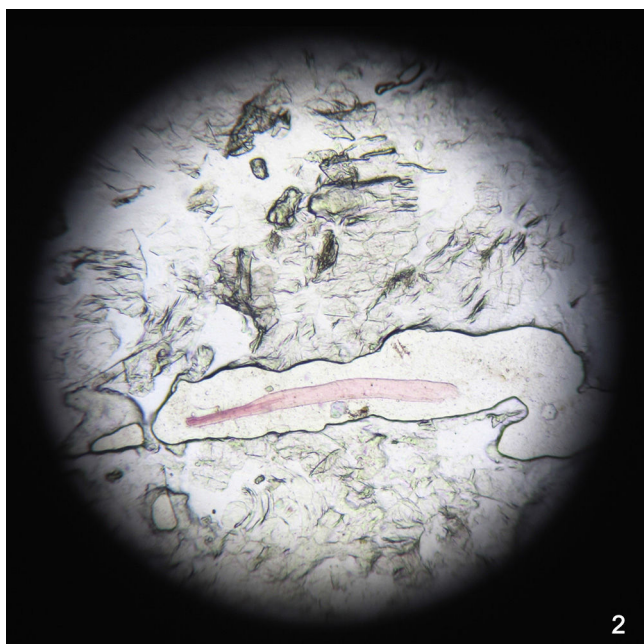


Figure 2 Direct optical microscopy examination of the adhesive tape test, showing pink fibrillary structures (original magnification x40).

Discussion

Hyperpigmented facial macules are a specific disease of unknown etiology and pathogenesis. Histology performed in some of the previously published cases showed postinflammatory changes. However, no trigger has been identified and the lesions cannot be attributed to other known causes of acquired hyperpigmentation in children.

The differential diagnosis to be considered during the initial evaluation of a patient with hyperpigmented macules includes a large group of disorders of very varied etiology, pathogenesis, and prognostic significance (Table 1). Postinflammatory pigmentation is the most common cause of transitory acquired hyperpigmentation in children. Pityriasis versicolor presents as hypo- or hyperpigmented macules with scaly desquamation; in children this disease can have

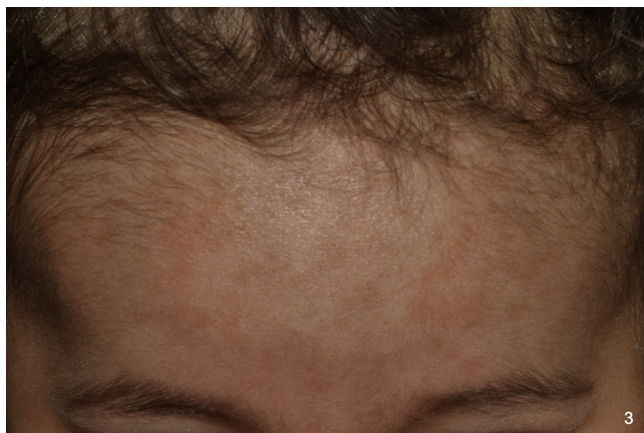

Figure 3 Hyperpigmented macules in the frontotemporal region of a 1-year-old girl of South American origin.

Table 1 Differential Diagnosis of Facial Hyperpigmented Macules in Children.

Condition	Distinctive Diagnostic Features	Facial Predominance
Postinflammatory pigmentation	History of previous lesions in the area	No
Pityriasis versicolor	Direct examination, adhesive tape test	Yes in children
Benign cephalic histiocytosis	Histology: Cells: CD68+, s100-, and CD1a-	Yes
Urticaria pigmentosa	Positive Darier sign	No
Pigmented purpuric dermatosis	Cayenne pepper spots	No
Transient neonatal pustular melanosis	Age at onset	No
RASopathies	Cardiac abnormalities, facial traits	No
Erythema dyschromicum perstans	Macules with a grayish color	No
Idiopathic eruptive macular pigmentation	Macules with a grayish color	No
Pigmented contact dermatitis	Patch testing	Yes

a predominantly facial distribution.² Direct observation of the fungus on microscopy confirms the diagnosis. Benign cephalic histiocytosis presents in infants as macules and papules that histologically show an infiltrate of histiocytes in the papillary dermis.³ The brownish lesions of urticaria pigmentosa typically present a positive Darier sign. The pigmented purpuric dermatoses are uncommon in children.⁴ Transient neonatal pustular melanosis, typical of black individuals, is characterized by transitory sterile pustules that rupture easily, even in utero, leaving hyperpigmented macules that disappear over the course of a few months. The so-called RASopathies (neurofibromatosis and Legius, Noonan, LEOPARD, cardiofaciocutaneous, and Costello syndromes) are a group of syndromes that share a mutation of the RAS/MAPK pathway and have some common cutaneous manifestations, such as pigmented lesions, and a frequent association with mental retardation, heart disorders, facial dysmorphism, and predisposition to develop cancer.⁵ Erythema dyschromicum perstans and idiopathic eruptive macular pigmentation, which some authors consider to be the same disease, are rare in children.⁶ Pigmented contact dermatitis, which presents as hyperpigmented macules with no previous eczematous phase, occurs mainly in dark skin phototypes, and a relationship with the use of dyes, cosmetics, fragrances, optical whiteners, and metals has been reported.⁷ Small children often have colognes applied to their hair, adults kiss them, leaving traces of lipstick on the forehead, or small adherent fibers from clothing can be left on their forehead on dressing or undressing, as was demonstrated in 2 of our patients. The young age of these patients makes it difficult to perform patch testing.

In conclusion, we have described 3 new cases of the condition recently described by Hernández-Martín et al.; 2 of the cases were in sisters, rekindling the doubt over a possible common trigger or genetic predisposition.

References

- Hernandez-Martin A, Gilliam AE, Baselga E, Vicente A, Lam J, Gonzalez-Ensenat M, et al. Hyperpigmented macules on the face of young children: A series of 25 cases. *J Am Acad Dermatol*. 2014;70:288–90.
- Jena DK, Sengupta S, Dwari BC, Ram MK. Pityriasis versicolor in the pediatric age group. *Indian J Dermatol Venereol Leprol*. 2005;71:259–61.
- Azulay-Abulafia L, Benez MD, Abreu Cde S, Miranda CV, Alves Mde F. Case for diagnosis. Benign cephalic histiocytosis. *An Bras Dermatol*. 2011;86:1222–5.
- Sardana K, Sarkar R, Sehgal VN. Pigmented purpuric dermatoses: An overview. *Int J Dermatol*. 2004;43:482–8.
- Hernandez-Martin A, Torrelo A. Rasopathies: Developmental disorders that predispose to cancer and skin manifestations. *Actas Dermosifiliogr*. 2011;102:402–16.
- Torrelo A, Zaballos P, Colmenero I, Mediero IG, de Prada I, Zambrano A. Erythema dyschromicum perstans in children: A report of 14 cases. *J Eur Acad Dermatol Venereol*. 2005;19:422–6.
- Bonamonte D, Foti C, Vestita M, Angelini G. Noneczematous contact dermatitis. *ISRN Allergy*. 2013;15:361746.

A. Giacaman,^{a,*} N. Knöpfel,^a M. Campos,^b
A. Martín-Santiago^a

^a *Servicio de Dermatología, Hospital Universitario Son Espases, Palma de Mallorca, Spain*

^b *Hospital General Universitario Gregorio Marañón, Madrid, Spain*

* Corresponding author.

E-mail address: anizagiacaman@gmail.com (A. Giacaman).

Cutaneous metastases on the head and neck from a papillary thyroid carcinoma, follicular variant[☆]



Metástasis cutáneas craneocervicales de un carcinoma papilar de tiroides variedad folicular

To the Editor:

Skin metastases in thyroid cancer are rare, and when they do occur most are associated with follicular carcinoma. They tend to appear in well-vascularized regions such as the scalp, and without predilection for sex.

A 58-year-old woman with no history of interest presented with a follicular variant of stage IV papillary thyroid carcinoma, with extrathyroidal pulmonary and bone involvement. After total thyroidectomy, she received 4 doses of radioactive iodine and hormonal suppression with levothyroxine. Despite treatment every 6 months with I¹³¹, response was limited and metastatic uptake persisted.

The patient underwent close clinical and imaging follow-up. Two years after surgery, a cervical mass was detected and this was attributed to relapse of papillary thyroid carcinoma. It was decided to excise the lesion and subsequently treat with I¹³¹. The patient remained stable, but after 7 months, constitutional symptoms occurred, along with dyspnea and pain in the right side as a result of the presence of multiple bilateral pulmonary nodular metastases, as well as a mediastinal conglomerate lymph nodal mass in both pulmonary hila (Fig. 1a). The physical examination revealed

indurated nodular lesions that were mildly itchy with a vascular appearance on the scalp in the frontal region and close to the thyroidectomy scar (Fig. 1b-d). They had appeared 6 months earlier and showed thick vessels with a mottled appearance on dermoscopic examination (Fig. 1c), giving rise to suspicion of metastatic lesions. Biopsy of one of the elements of the scalp revealed a well-delimited intradermal neoplasm, made up of epithelial nodules surrounded by bands of fibrotic tissue and tumoral invasion of superficial skin lymph nodes (Fig. 2a). Neoplastic cells that formed follicular structures had a polygonal form with a clear cytoplasm and pleomorphic nuclei, some of which had a ground-glass appearance (Fig. 2b).

Immunohistochemical study was positive for TTF-1 (thyroid transcription factor 1) (Fig. 2c) and galectin-3 (Fig. 2d) but negative for thyroglobulin (Tg).

With these findings, cutaneous metastasis of follicular variant of papillary thyroid carcinoma was diagnosed.

The patient received another dose of radioactive iodine, but some months later neurologic symptoms occurred due to bilateral supratentorial and infratentorial brain metastases and osteolytic images were observed in the cranial vault. Given this disease progression, sorafenib was administered in combination with zoledronic acid in the compassionate use setting, but the patient finally died 6 months later.

Cutaneous metastases of thyroid carcinomas are rare (occurring in less than 1% of primary thyroid carcinomas). When they do occur, they present as slow-growing erythematous lesions, purpuric plaques, or soft and mildly itchy erythematous nodules, which may become ulcerated. In 70% of the cases, these lesions are found on the scalp and the rest of the face or neck, due to the extensive vascularization of the dermis at these sites.¹⁻³ The condition affects men and women equally and is most frequently associated with follicular thyroid carcinoma (42%) even though papillary carcinoma is the most frequent primary carcinoma (50%-89%).⁴ Metastases may present as the first manifestation of an occult papillary carcinoma (worse prognosis)

[☆] Please cite this article as: Márquez García A, Ferrándiz Pulido L, Ríos-Martín JJ, Camacho Martínez FM. Metástasis cutáneas craneocervicales de un carcinoma papilar de tiroides variedad folicular. *Actas Dermosifiliogr*. 2016;107:86–88.