

in a patient with mixed connective tissue disease: An unusual complication. *Lupus*. 2010;19:1005–6.

12. Falchi L, Capello D, Palumbo B, Rauco A, Emili R, Cianciulli M, et al. A case of nodular sclerosis Hodgkin's lymphoma repeatedly relapsing in the context of composite plasma cell-hyaline vascular Castleman's disease: Successful response to rituximab and radiotherapy. *Eur J Haematol*. 2007;79:455–61.
13. Straub RH, Besedovsky HO. Integrated evolutionary immunological neuroendocrine framework for the pathogenesis of chronic disabling inflammatory F diseases. *FASEB J*. 2003;17:2176–83.

T. Gracia-Cazaña,<sup>a,\*</sup> C. Delgado-Beltrán,<sup>b</sup>  
M.A. Concellón,<sup>c</sup> M.A. Fuertes<sup>d</sup>

<sup>a</sup> Servicio de Dermatología, Hospital de Barbastro, Huesca, Spain

<sup>b</sup> Servicio de Reumatología, Hospital Clínico Lozano Blesa, Zaragoza, Spain

<sup>c</sup> Servicio de Dermatología, Hospital Clínico Lozano Blesa, Zaragoza, Spain

<sup>d</sup> Servicio de Hematología, Hospital Clínico Lozano Blesa, Zaragoza, Spain

\* Corresponding author.

E-mail address: [tamara.gracia@hotmail.com](mailto:tamara.gracia@hotmail.com)  
(T. Gracia-Cazaña).

## Are We Examining Our Patients Properly and Can We Do a Better Job?<sup>☆</sup>



### ¿Exploramos correctamente a los pacientes? ¿Qué nos está pasando?

To the editor:

Melanoma remains a prominent health concern. It is one of the most frequent tumors in young adults.<sup>1</sup> The incidence and associated mortality has increased in recent decades.<sup>2–4</sup>

Although metastatic melanoma can only be cured on limited occasions, new immunotherapy treatments<sup>5–7</sup> (for example, high-dose IL-2, ipilimumab [anti-cytotoxic T-lymphocyte antigen 4], pembrolizumab, and nivolumab [anti-programmed cell death 1], etc.) and combination treatments for specific mutations<sup>8,9</sup> (BRAF, mitogen-activated protein kinase [MEK], and c-KIT inhibitors) have increased survival for patients with stage III and IV disease. At times, melanoma is diagnosed in an advanced phase and a primary tumor is not detected despite exhaustive study. Metastatic melanoma from an unknown primary tumor is defined as the histologically confirmed presence of melanoma in a lymph node, organ, or other tissue without history or evidence of a primary skin, mucosal, or ocular lesion. These metastatic lesions are estimated to comprise 3.2% of all melanomas and they seem to have a better prognosis than those metastatic lesions of known origin.<sup>10</sup>

We present the cases of 2 patients seen initially in tertiary hospitals with metastatic melanoma of unknown origin who sought a second opinion in our hospital.

### Case Histories

A 67-year-old man was seen in his local hospital with swollen lymph nodes in his left groin. After histologic and immunohistochemical study of one of the swollen lymph nodes, metastatic melanoma of unknown origin was diagnosed. The

patient was assessed by an oncologist and a dermatologist, who were unable to locate the primary melanoma. Given that immunotherapy treatment was contraindicated and the BRAF mutation was absent, he received 3 chemotherapy sessions for several months. We are awaiting a reduction in the inguinal mass before palliative lymphadenectomy.

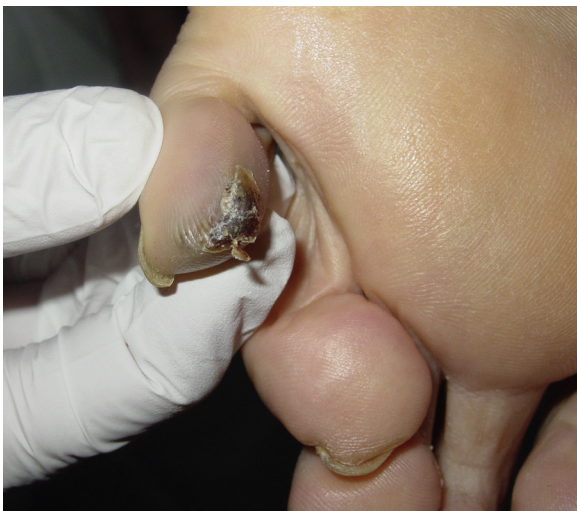By coincidence, in the same week, we assessed the second patient. He was 45 years old, and had a large and rapidly growing tumor in the left laterocervical region that prompted him to attend his reference hospital. Histologic and immunohistochemical study of the mass pointed to diagnosis of metastatic melanoma. The lesion was positive for the BRAF mutation. In the study of extension by computed tomography-positron emission tomography, lymph node metastases were also found at other sites. After multidisciplinary assessment by an oncologist, a dermatologist, an ear-nose-throat specialist, and an ophthalmologist, he was diagnosed with metastatic melanoma of unknown origin and prescribed treatment with a BRAF inhibitor (vemurafenib) and a MEK inhibitor (trametinib).

After taking the medical history and the physical examination of the patients, the primary tumor was located in both patients: the first patient had a dark, keratotic pigmented lesion measuring 1.5 × 1 cm, with the Hutchinson sign, on the ball of the left big toe (Fig. 1). The second patient had a hyperpigmented lesion measuring 2 × 1.5 cm in diameter in the left parietal region, with a characteristic atypical dermoscopic pattern (Fig. 2). In both cases, the lesion was evident and was located on a region of the skin that should be examined given the site of the lymph node metastasis. Certain care in the examination was, however, required because the lesion was located on an area of the scalp covered by hair in one case and in the acral most part of the body in the other.

We present 2 cases that may well reflect other avoidable situations in dermatology departments in our hospitals. Although this may appear a diagnostic omission and would have no bearing on the follow-up and therapeutic approach, prognosis does vary according to whether the primary tumor is known or unknown.<sup>10</sup>

A detailed medical history and careful physical examination are the basis for diagnosis. A study in the United States concluded that the percentage of dermatologists who perform a complete examination of patients with risk factors for melanoma does not exceed 50%.<sup>11</sup> Other studies

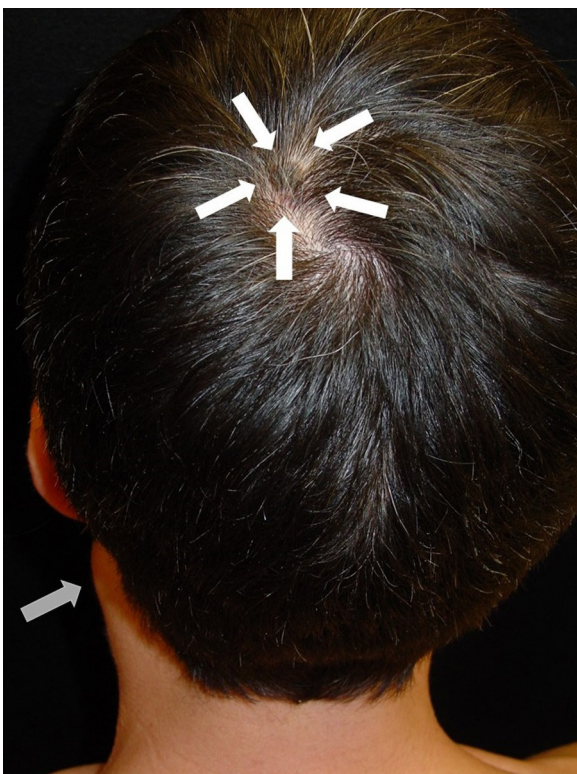
<sup>☆</sup> Please cite this article as: Ivars M, Redondo P. ¿Exploramos correctamente a los pacientes? ¿Qué nos está pasando?. *Actas Dermosifiliogr*. 2015;106:846–848.



**Figure 1** Image of the primary tumor in the patient with lymph node metastases in the left groin. A dark, kerotic pigmented lesion measuring  $1.5 \times 1$  cm can be seen, with the Hutchinson sign, on the ball of the left little toe.

highlight how a complete body examination can assist in early diagnosis of a high percentage of melanomas in patients who attend the clinic for another reason.<sup>12-18</sup>

In view of the above, the physical examination of the patient in a melanoma unit should be protocolized and



**Figure 2** Lymph node metastases in the left laterocervical region (gray arrow) and primary tumor (hyperpigmented lesion measuring  $2 \times 1.5$  cm in diameter with a characteristic atypical dermoscopic pattern) in the left parietal region (white arrows).

meticulous. First, the patient should be examined completely naked, with appropriate light sources, if possible with natural light. The whole body surface should be examined, without omitting the acral areas and those not readily accessible for some patients (retroauricular area, interdigital area, and soles of the feet, etc.). The mucosae (oral, genital, conjunctival, etc.) and appendages (nails and areas with hair follicles) should also be examined. When the patient has been diagnosed with metastatic melanoma of unknown primary tumor, an exhaustive examination of the area of skin drained by the affected lymph node should be undertaken.

## References

1. Jemal A, Murray T, Ward E, Samuels A, Tiwari RC, Ghafoor A, et al. Cancer statistics, 2005. *Ca Cancer J Clin.* 2005;55: 10-30.
2. Lens MB, Dawes M. Global perspectives of contemporary epidemiological trends of cutaneous malignant melanoma. *Br J Dermatol.* 2004;150:179-85.
3. Garbe C, Leiter U. Melanoma epidemiology and trends. *Clin Dermatol.* 2009;27:3-9.
4. Leiter U, Garbe C. Epidemiology of melanoma and non-melanoma skin cancer—the role of sunlight. *Adv Exp Med Biol.* 2008;624:89-103.
5. Atkins MB, Kunkel L, Sznol M, Rosenberg SA. High-dose recombinant interleukin-2 therapy in patients with metastatic melanoma: long-term survival update. *Cancer J Sci Am.* 2000;6 Suppl 1:S11-4.
6. Joseph RW, Eckel-Passow JE, Sharma R, Liu P, Parker A, Jakob J, et al. Characterizing the clinical benefit of ipilimumab in patients who progressed on high-dose IL-2. *J Immunother.* 2012;35:711-5.
7. Robert C, Long GV, Brady B, Dutriaux C, Maio M, Mortier L, et al. Nivolumab in previously untreated melanoma without BRAF mutation. *N Engl J Med.* 2015;372:320-30.
8. McArthur GA, Chapman PB, Robert C, Larkin J, Haanen JB, Dummer R, et al. Safety and efficacy of vemurafenib in BRAF(V600E) and BRAF (V600K) mutation-positive melanoma (BRIM-3): Extended follow-up of a phase 3, randomised, open-label study. *Lancet Oncol.* 2014;15:323-32.
9. Flaherty KT, Robert C, Hersey P, Nathan P, Garbe C, Milhem M, et al., METRIC Study Group. Improved survival with MEK inhibition in BRAF-mutated melanoma. *N Engl J Med.* 2012;367:107-14.
10. Bae JM, Choi YY, Kim DS, Lee JH, Jang HS, Kim H, et al. Metastatic melanomas of unknown primary show better prognosis than those of known primary: A systematic review and meta-analysis of observational studies. *J Am Acad Dermatol.* 2015;72:59-70.
11. Federman DG, Kravetz JD, Kirsner RS. Skin cancer screening by dermatologists: Prevalence and barriers. *J Am Acad Dermatol.* 2002;46:710-4.
12. Kantor J, Kantor DE. Routine dermatologist-performed full-body skin examination and early melanoma detection. *Arch Dermatol.* 2009;145:873-6.
13. Schwartz JL, Wang TS, Hamilton TA, Lowe L, Sondak VK, Johnson TM. Thin primary cutaneous melanomas: Associated detection patterns, lesion characteristics, and patient characteristics. *Cancer.* 2002;95:1562-8.
14. Brady MS, Oliveria SA, Christos PJ, Berwik M, Coit DG, Katz J, et al. Patterns of detection in patients with cutaneous melanoma. *Cancer.* 2000;89:342-7.

15. Epstein DS, Lange JR, Gruber SB, Mofid M, Koch SE. Is physician detection associated with thinner melanomas? *JAMA*. 1999;281:640–3.
16. McPherson M, Elwood M, English DR, Baade PD, Youl PH, Aitken JF. Presentation and detection of invasive melanoma in a high-risk population. *J Am Acad Dermatol*. 2006;54:783–92.
17. Carli P, de Giorgi V, Palli D, Maurichi A, Mulas P, Orlandi C, et al. Self-detected cutaneous melanomas in Italian patients. *Clin Exp Dermatol*. 2004;29:593–6.
18. Aldridge RB, Naysmith L, Ooi ET, Murray CS, Rees JL. The importance of a full clinical examination: assessment of index lesions

referred to a skin cancer clinic without a total body skin examination would miss one in three melanomas. *Acta Derm Venereol*. 2013;93:689–92.

M. Ivars,\* P. Redondo

*Departamento de Dermatología, Clínica Universidad de Navarra, Pamplona, Spain*

\* Corresponding author.

*E-mail addresses:* [mivars@unav.es](mailto:mivars@unav.es), [martaivars@gmail.com](mailto:martaivars@gmail.com) (M. Ivars).

## Transitory Rectangular Alopecia After Endovascular Embolization: A Case Report and Description of the Histopathology Findings<sup>☆</sup>



### Alopecia rectangular transitoria tras embolización endovascular: presentación de un caso y descripción de los hallazgos histopatológicos

*To the Editor:*

Endovascular embolization is the first-line treatment for intracranial aneurysms and vascular malformations. The possibility of inducing transitory secondary alopecia with this technique is well known by interventional neuroradiologists, but has received little attention in dermatology publications and even less in the dermatopathology literature, in which there are still no published descriptions of the histopathologic findings characteristic of this condition.

We report a new case of transitory rectangular alopecia after endovascular embolization and provide the first description of its histopathologic characteristics. The patient was a 32-year-old woman who underwent endovascular embolization to treat an intracranial arteriovenous malformation (Fig. 1). She consulted for hair loss of rapid onset in the left parieto-occipital region 1 month after the procedure. On physical examination, a well-defined rectangular plaque of alopecia with a strongly positive hair pull test was present in the left parieto-occipital region (Fig. 2). On trichoscopy, dystrophic hair shafts were observed in the follicular orifices, with no exclamation mark hairs. A skin biopsy taken from the plaque of alopecia revealed a high percentage of follicles in catagen, with no signs of damage to the follicular epithelium or radiodermatitis. The hair follicles appeared retracted, with an undulating, corrugated outer root sheath and with the presence of apoptotic cells (Fig. 3). In addition, the typical fibrous stela of follicles in catagen extended beneath the follicular bulb. It was

decided to take a wait-and-see approach, without performing treatment. The plaque of alopecia showed a spontaneous and progressive improvement, with complete repopulation within 2 months.

Alopecia after radiotherapy to the head and neck is extensively documented in the literature; however, few reports have been published on alopecia after diagnostic and therapeutic endovascular procedures and the condition is probably underdiagnosed. Fluoroscopy, a technique that uses the fluorescent properties of x-rays to obtain images in real time, is an important aid when performing endovascular embolization as it allows us to take video images of, for example, the movement of fluids. Taking images over a long interval can give rise to radiation-induced adverse effects, as patients receive high doses of radiation to a single area. Transitory rectangular alopecia after endovascular embolization is considered to be a specific form of acute radiodermatitis caused by the marked sensitivity to radiation of scalp hair follicles in anagen.<sup>1</sup> The follicular cycle is interrupted abruptly by an acute lesion of mitotically active cells in the follicular matrix. This produces a premature and synchronic entry of all follicles into catagen phase, and the hair shafts are eliminated from affected follicles. However, the follicular cycle reinitiates when the harmful stimulus ceases, hence the complete repopulation of these lesions within 2 to 4 months after the procedure.<sup>1</sup>

The typical clinical presentation of transitory rectangular alopecia after endovascular embolization is as a plaque of alopecia of artifactual morphology that appears a few weeks after the intervention, in the area of scalp that received the highest dose of radiation. Onset depends mainly on total fluoroscopy time (more than 100 minutes) and on the total dose received (definitive cicatricial alopecia will occur at doses over 7 Gy and transitory alopecia at doses between 3 and 5 Gy).<sup>2</sup> However, when calculating the total radiation dose used in the intervention, it is important also to take into account prior diagnostic procedures that the patient has undergone, such as angiography, as the effects of these techniques on the hair follicles are cumulative.<sup>2,3</sup> In addition, certain biological factors such as age, hair density, hormone status, and some genetic factors, can also influence the onset of this type of alopecia, although the underlying mechanisms are still poorly understood.<sup>4</sup>

It is important to differentiate transitory rectangular alopecia after endovascular embolization from postoperative alopecia and alopecia areata,<sup>4</sup> as these are also nonscarring alopecias that are of rapid onset and present

<sup>☆</sup> Please cite this article as: Bernárdez C, Alcaraz I, Molina-Ruiz AM, Requena L. Transitory Rectangular Alopecia After Endovascular Embolization: A Case Report and Description of the Histopathology Findings. *Actas Dermosifilogr*. 2015;106:848–850.