

In conclusion, BSI is a rare genodermatosis belonging to the group of ARCI. It has a series of clinical and diagnostic peculiarities that we should be aware of. Although the diagnosis is usually clinical, confirmation can only be made by genetic analysis of the *TGM-1* gene. This is the only gene implicated in this condition, but its mutations are also the most prevalent in other forms of ARCI, and many of the mutations are common to the different forms; thus, individuals with the same genetic load can develop different phenotypes, and these can even be dynamic, with changes occurring during life. All these features are important with respect to the prognosis in our patients and to correct genetic counselling.

Acknowledgments

We would like to offer our particular thanks to Dr. Rogelio González Sarmiento, of the Molecular Medicine Unit of Universidad de Salamanca, for performing the genetic analysis.

References

- Oji V, Tadini G, Akiyama M, Blanchet-Bardon CB, Bodemer C, Bourrat E, et al. Revised nomenclature and classification of inherited ichthyoses: Results of the First Ichthyosis Consensus Conference in Sorèze 2009. *J Am Acad Dermatol*. 2010;63:607–41.
 - Rodríguez-Pazos L, Ginarte M, Vega A, Toribio J. Ictiosis congénitas autosómicas recesivas. *Actas Dermosifiliogr*. 2013;104:270–84.
 - Hernández-Martín A, García-Doval I, Aranegui B, de Unamuno P, Rodríguez-Pazos L, González-Enseñat MA, et al. Prevalence of autosomal recessive congenital ichthyosis: A population-based study using the capture-recapture method in Spain. *J Am Acad Dermatol*. 2012;67:240–4.
 - Jacyk WK. Bathing-suit ichthyosis. A peculiar phenotype of lamellar ichthyosis in South African blacks. *Eur J Dermatol*. 2005;15:433–6.
 - Bourra E, Blanchet-Bardon C, Derbois C, Cure S, Fischer J. Specific TGM1 mutation profiles in bathing suit and self-improving collodion ichthyoses: Phenotypic and genotypic data from 9 patients with dynamic phenotypes of autosomal recessive congenital ichthyosis. *Arch Dermatol*. 2012;148:1191–5.
 - Hackett BC, Fitzgerald D, Watson RM, Hol FA. Irvine genotype-phenotype correlations with TGM1: Clustering of mutations in the bathing suit ichthyosis and self-healing collodion baby variants of lamellar ichthyosis. *Br J Dermatol*. 2010;162:448–51.
 - Aufvenne K, Oji V, Walker T, Becker-Pauly C, Hennies HC, Stöcker W, et al. Transglutaminase-1 and bathing suit ichthyosis: Molecular analysis of gene/environment interactions. *J Invest Dermatol*. 2009;129:2068–71.
 - Oji V, Mazereeuw Hautier J, Ahvazi B, Hausser I, Aufvenne K, Walker T, et al. Bathing suit ichthyosis is caused by transglutaminase-1 deficiency: Evidence for a temperature-sensitive phenotype. *Hum Mol Genet*. 2006;15:3083–97.
 - Huber M, Rettler I, Bernasconi K, Frenk E, Lavrijsen SP, Ponc M, et al. Mutations of keratinocyte transglutaminase in lamellar ichthyosis. *Science*. 1995;267:525–8.
 - Redondo P, Bauzá A. Topical N-acetylcysteine for lamellar ichthyosis. *Lancet*. 1999;354:1880.
- J.F. Mir-Bonafé,* E. Baselga-Torres, E. Roé-Crespo, L. Puig-Sanz
- Servicio de Dermatología, Hospital de la Sant Creu i Sant Pau, Barcelona, España*
- *Corresponding author.
E-mail address: jmirb@santpau.cat (J.F. Mir-Bonafé).

Histologic diagnosis of ossifying fibromyxoid tumor: 2 cases in the past 20 Years[☆]



Diagnóstico histológico del tumor fibromixóide osificante: 2 casos en los últimos 20 años

To the Editor:

The ossifying fibromyxoid tumor (OFMT) was originally described as a small benign tumor of the subcutaneous tissue. It is formed of small cells arranged in cords and nests in a fibromyxoid stroma, covered by a bony capsule.¹ However, recent publications have reported histologic findings of malignancy associated with metastatic disease.² There is controversy regarding the histologic origin of the tumor. Despite initially being considered to be distinct from schwannian or cartilaginous tumors,¹ based on

ultrastructural and immunohistochemical characteristics (positivity for protein S-100), more recent proteomic and genetic analyses support a neuronal or myoepithelial origin.^{3,4} In the last decade, the idea that malignant OFMTs do not exist has been proposed, as they do not satisfy the traditional histological description, and could correspond to other malignant soft tissue tumors.⁵

In the last 20 years, 2 cases of OFMT have been identified in our hospital, one on the scalp of a 55-year-old man the other on the hand of a 46-year-old man (Fig. 1). The tumors were painless. Histology of the excisional biopsies were consistent with the classic description of OFMT: well-defined capsule; areas of fibrosis formed of laminae of uniform, ovoid cells with round nuclei in a hyaline stroma; other areas of myxoid appearance with lower cellularity; and moderate diffuse positivity for protein S-100 (Fig. 2). The surgical margins were not extended in either case. No signs of local recurrence or metastases have been detected after follow-up of 18 years and 21 months, respectively.

This tumor typically affects men, and the mean age at presentation is 50 years. It usually arises in the proximal regions of the limbs, most commonly the lower limbs.^{1,3-6}

Immunohistochemistry closely reflects the controversy regarding the histogenesis of the tumor. The origins that have been postulated with greatest emphasis are Schwann

[☆] Please cite this article as: Hernández-Godoy J, Casado-Sánchez C, Landín L, Rosell AA. Diagnóstico histológico del tumor fibromixóide osificante: 2 casos en los últimos 20 años. *Actas Dermosifiliogr*. 2015;106:772–774.

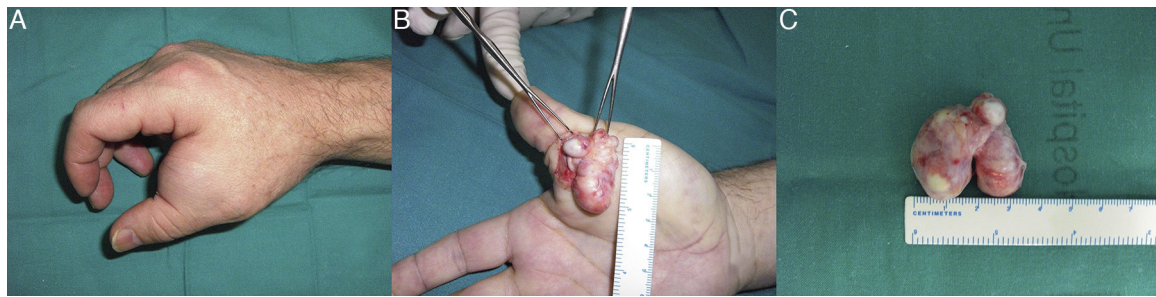


Figure 1 A, Preoperative Image of the tumor in the first commissure. B, Intraoperative view of the resection. C, The excised ossifying fibromyxoid tumor.

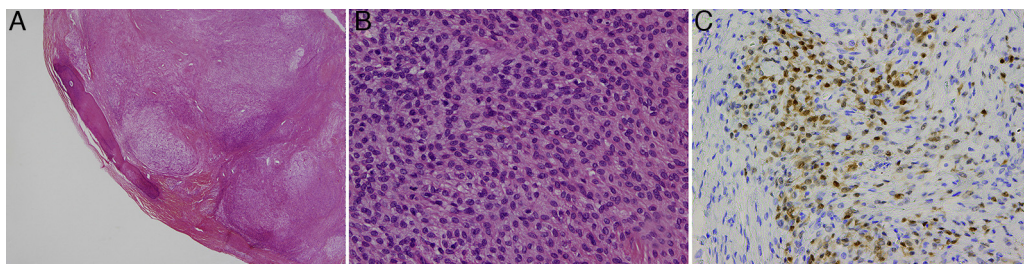


Figure 2 Histology images. A, The ossifying fibromyxoid tumor with its characteristic, incomplete capsule of lamellar bone; hematoxylin and eosin (H&E), original magnification $\times 2$. B, Monomorphic epithelioid cells with small nucleoli and clearly distinct borders; H&E, original magnification $\times 40$. C, Immunohistochemistry showing diffuse positivity for protein S-100; original magnification $\times 20$.

cells (because of the existence of well-developed, duplicated basal lamina and positivity for protein S-100⁷) and cartilage (due to the presence of irregular cell borders with small projections and intracellular microfillaments with positivity for S-100¹). Other authors have suggested a myoepithelial lineage based on ultrastructural findings,⁴ or neuronal lineage due to positivity for CD56, a neural adhesion molecule, and for EAAT4, a neuronal glutamic acid transporter.³

Cytogenetic analysis of this type of tumor focuses attention on 2 genes, *INI-1*,³ a tumor suppressor gene, and *PHF1*,⁸ which codes for a protein that, among other functions, regulates the activity of the polycomb-repressive complex 2, which silences genes responsible for development. Dysregulation of this complex, secondary to changes in these or other adjacent genes, has been suggested as a mechanism of development of OFMTs.

In 1995, Kilpatrick⁹ was the first to describe the existence of OFMTs with a malignant behavior, associated with atypical morphological findings. Folpe and Weiss⁶ identified criteria predictive of an aggressive or malignant behavior. Subsequently, Miettinen⁵ rejected the existence of malignant OFMTs, stating that the majority of those tumors did not satisfy the classic description of OFMTs and could be better classified as other types of sarcoma. Graham,³ continuing the work initiated by Folpe, validated their classification on finding that the malignant subtype was associated with a more aggressive behavior during follow-up.

A biologically aggressive behavior was also investigated in the largest series of OFMTs. Folpe⁶ detected local recurrence in 18% and metastases in 16%. Miettinen,⁵ including

only typical OFMTs, reported local recurrence in 22% and no cases of metastasis. Finally, Graham³ reported local recurrence rates of 4.3% and metastasis in 6.5%, considering only malignant OFMTs. Grouping the data from those series, the metastatic risk of the typical variant is less than 5%; this indicates that, even if benign histological characteristics are observed, OFMT can give rise to metastases.

The scarcity of OFMTs recruited in the past 20 years in our hospital, given that the catchment population is close to 1 million, would appear to be related to a diagnostic vision closer to that of Miettinen than to Folpe and Graham. Thus, tumors that do not fit the typical description of OFMTs, and that showed characteristics of malignancy, were classified as low-grade sarcomas rather than as malignant OFMTs. This could explain the absence of recurrence in either of our 2 patients, despite having performed excisions with narrow margins.

In conclusion, OFMT is a rare disease, whose epidemiology may be biased by the diagnostic considerations of each pathology department regarding atypical and malignant variants. Despite showing benign characteristics, these tumors can present aggressive behavior, and they should not therefore be classified as benign, but rather considered as tumors of intermediate malignancy.

Acknowledgments

We would like to thank Drs. José Juan Pozo-Kreilinger, Adrien Yvon, and Estefania Alonso-Rodríguez for their close collaboration, which made this study possible.

References

1. Enzinger FM, Weiss SW, Liang CY. Ossifying fibromyxoid tumor of soft parts. A clinicopathological analysis of 59 cases. *Am J Surg Pathol.* 1989;13:817–27.
2. Nishio J, Iwasaki H, Ohjimi Y, Ishiguro M, Isayama T, Naito M, et al. Ossifying fibromyxoid tumor of soft parts. Cytogenetic findings. *Cancer Genet Cytogenet.* 2002;133:124–8.
3. Graham RPD, Dry S, Li X, Binder S, Bahrami A, Raimondi SC, et al. Ossifying fibromyxoid tumor of soft parts: A clinicopathologic, proteomic, and genomic study. *Am J Surg Pathol.* 2011;35:1615–25.
4. Min K-W, Seo IS, Pitha J. Ossifying fibromyxoid tumor: Modified myoepithelial cell tumor. Report of three cases with immunohistochemical and electron microscopic studies. *Ultrastruct Pathol.* 2005;29:535–48.
5. Miettinen M, Finnell V, Fetsch JF. Ossifying fibromyxoid tumor of soft parts—a clinicopathologic and immunohistochemical study of 104 cases with long-term follow-up and a critical review of the literature. *Am J Surg Pathol.* 2008;32:996–1005.
6. Folpe AL, Weiss SW. Ossifying fibromyxoid tumor of soft parts: A clinicopathologic study of 70 cases with emphasis on atypical and malignant variants. *Am J Surg Pathol.* 2003;27:421–31.
7. Hirose T, Shimada S, Tani T, Hasegawa T. Ossifying fibromyxoid tumor: Invariable ultrastructural features and diverse immunophenotypic expression. *Ultrastruct Pathol.* 2007;31:233–9.
8. Gebre-Medhin S, Nord KH, Möller E, Mandahl N, Magnusson L, Nilsson J, et al. Recurrent rearrangement of the PHF1 gene in ossifying fibromyxoid tumors. *Am J Pathol.* 2012;181:1069–77.
9. Kilpatrick SE, Ward WG, Mozes M, Miettinen M, Fukunaga M, Fletcher CD. Atypical and malignant variants of ossifying fibromyxoid tumor. Clinicopathologic analysis of six cases. *Am J Surg Pathol.* 1995;19:1039–46.

J. Hernández-Godoy,* C. Casado-Sánchez,
L. Landín, A.A. Rosell

Servicio de Cirugía Plástica, Hospital Universitario La Paz, Madrid, Spain

* Corresponding author.

E-mail address: jhdezgodoy@gmail.com

(J. Hernández-Godoy).

Cutaneous Ulcer at the Site of Radiation-Induced Dermatitis Caused by Infection With *Vibrio alginolyticus*[☆]



Úlcera cutánea sobre radiodermatitis crónica por *Vibrio alginolyticus*

To the Editor:

We report the case of a 66-year-old man with a painful ulcer that he first noticed on the sole of his left foot 2 months previously. The lesion appeared during the month of August on atrophic and scarred skin that was compatible with chronic radiation-induced dermatitis over an area where 15 years earlier he had received radiation therapy for a skin lesion of unknown origin (no medical or histological data were available). The patient lived on the island of Mallorca and habitually walked along the seashore. He reported no history of diabetes, hypertension, smoking, or other systemic symptoms or conditions of interest.

Examination of the skin revealed an ulcer with yellowish exudate, indurated margins, and atrophic skin in the adjacent areas. A blood workup revealed no leukocytosis or increased C-reactive protein levels. A substantial amount of tissue was taken from the margin and base of the ulcer for biopsy. Histopathology revealed collagenic fibrosis in the dermis and signs of vascular disease but no cellular atypia. These findings were compatible with radiation-induced dermatitis. Neoplastic processes were ruled out. Culture of the exudate revealed *Vibrio alginolyticus* (Fig. 1). Based on the

results of the antibiogram, treatment was started with oral ciprofloxacin. However, the course was indolent, with the formation of a skin abscess (Fig. 1B) and development of osteomyelitis (Fig. 2) requiring admission to hospital. The lesion was debrided, even though no microorganisms grew in the culture. Antibiotic therapy was started with doxycycline and ceftriaxone for 10 days. Progress was good, and the ulcer resolved after 3 months.

V. alginolyticus is a Gram-negative rod belonging to the genus *Vibrio*. It is the most halophilic of the *Vibrio* species, since it can grow in salt concentrations as high as 10%.¹ *V. alginolyticus* is pathogenic for humans, although its virulence is low, and it is acquired after exposure to seawater or marine animals. *V. alginolyticus* was the only microorganism isolated in the present case. However, it is often found in association with other *Vibrio* species such as *Vibrio parahaemolyticus* or *Vibrio vulnificus*.² *V. alginolyticus* forms part of the habitual marine flora in temperate and tropical coastal waters. The incidence of infection by this microorganism in humans increases significantly during summer owing to the increase in the temperature of seawater.³ Similarly, the climate change observed in recent years leads us to believe that the density of this bacteria has been increasing both in tropical waters and in the colder waters of northern Europe.⁴

The microorganism is mainly associated with conjunctivitis, otitis, gastroenteritis, and superinfection of wounds that come into contact with contaminated seawater.^{5–7} Although its course is usually benign and it responds well to oral antibiotic therapy, cases of bacteremia and necrotizing fasciitis have also been reported.⁸ Patients usually present some degree of immunosuppression (eg, advanced age, diabetes mellitus, liver disease, or immunosuppressive therapy) that predisposes them to infection.⁸

Our literature search yielded only 1 other case of osteomyelitis caused by *V. alginolyticus*. The patient had chronic hepatitis C and a surgical wound that became super-

[☆] Please cite this article as: Escudero MM, del Pozo LJ, Jubert E, Riera M. Úlcera cutánea sobre radiodermatitis crónica por *Vibrio alginolyticus*. *Actas Dermosifiliogr.* 2015;106:774–775.