



# ACTAS Dermo-Sifiliográficas

Full English text available at  
www.actasdermo.org



## VIDEOS OF SURGICAL PROCEDURES IN DERMATOLOGY

### Parascapular Perforating Flap to Treat Severe Axillary Hidradenitis Suppurativa<sup>☆</sup>



### Colgajo paraescapular perforante para tratamiento de la hidradenitis axilar grave

J. Tercedor-Sánchez,<sup>a,\*</sup> J.M. Ródenas-López,<sup>b</sup> P. Ramón-Faba,<sup>c</sup> F. Muñoz-Romero<sup>c</sup>

<sup>a</sup> UGC Dermatología Médico-Quirúrgica y Venereología, Hospital Universitario Virgen de las Nieves, Granada, Spain

<sup>b</sup> UGC Dermatología Médico-Quirúrgica y Venereología, Hospital General Universitario Morales Meseguer, Murcia, Spain

<sup>c</sup> UGC Cirugía Plástica y Reparadora, Hospital Virgen de la Arreixaca, Murcia, Spain

#### KEYWORDS

Hidradenitis suppurativa;  
Surgical flap;  
Perforator flap

#### PALABRAS CLAVE

Hidradenitis suppurativa;  
Colgajo quirúrgico;  
Colgajo perforante

#### Introduction

Hidradenitis suppurativa (HS) is a chronic inflammatory disease that arises in hair follicles in areas with a predominance of apocrine glands. It can cause major physical

and psychosocial sequelae and its treatment is a significant challenge.<sup>1</sup> Surgical elimination of the affected tissues is considered to be the treatment of choice.<sup>2</sup> Severe axillary HS requires wide excision of the affected area, but reconstruction is complex and is associated with a high risk of postoperative complications. We used a pedicled parascapular flap in a patient with Hurley stage III HS.

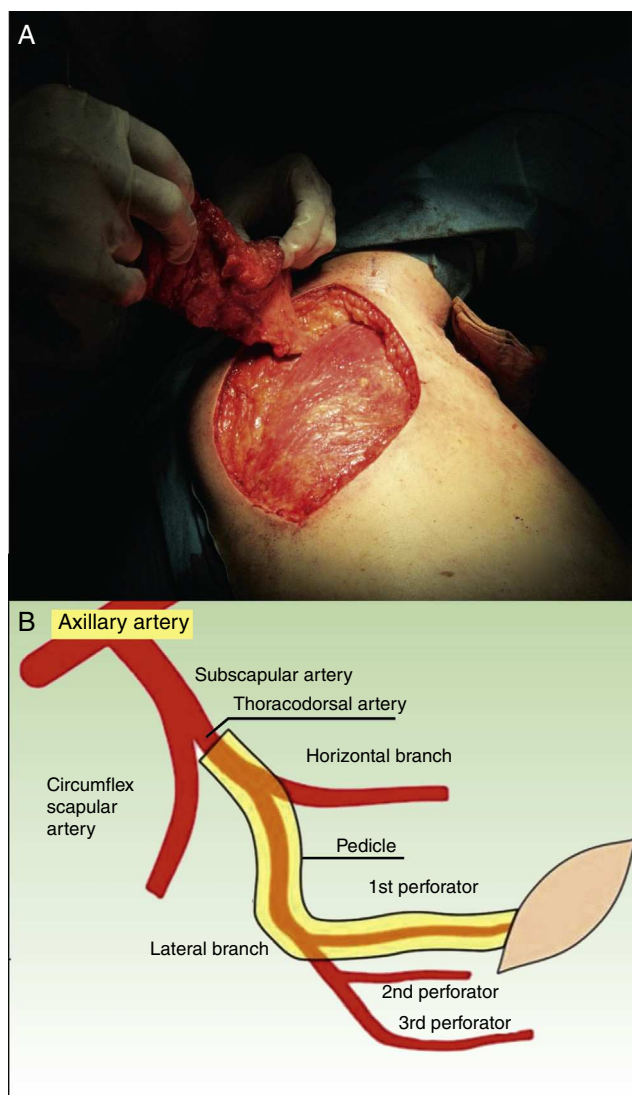
#### Description of the Technique

The thoracodorsal artery provides the main blood supply to latissimus dorsi. After giving off the branch to the serratus muscle, the artery bifurcates into a medial and a lateral branch. After an intramuscular path of 2 cm, the lateral branch divides into 2 or 3 perforating arteries, the most proximal of which reaches the subcutaneous tissue 2 to 3 cm posterior to the lateral margin of the latissimus dorsi muscle and 8 cm inferior to the posterior axillary fold (Fig. 1B). The patient is placed in the lateral decubitus position with the arm abducted at 90° over the head. Ultrasound is used to locate and mark the thoracodorsal perforating artery in the superolateral region of the scapula, and the distance to the center of the homolateral axilla is measured; this will define the size of the flap. The flap is drawn and is carefully dissected until a pedicle is fashioned that includes the artery and permits sufficient mobility for the flap to be tunneled towards the axilla (Fig. 1A). All the affected area of the axilla is excised (Fig. 2A) and the tunnel to the scapular

<sup>☆</sup> Please cite this article as: Tercedor-Sánchez J, Ródenas-López JM, Ramón-Faba P, Muñoz-Romero F. Colgajo paraescapular perforante para tratamiento de la hidradenitis axilar grave. Actas Dermosifiliogr. 2015;106:669–671.

\* Corresponding author.

E-mail addresses: [tercedordermatologia@gmail.com](mailto:tercedordermatologia@gmail.com), [jesus.tercedor.sspa@juntadeandalucia.es](mailto:jesus.tercedor.sspa@juntadeandalucia.es) (J. Tercedor-Sánchez).

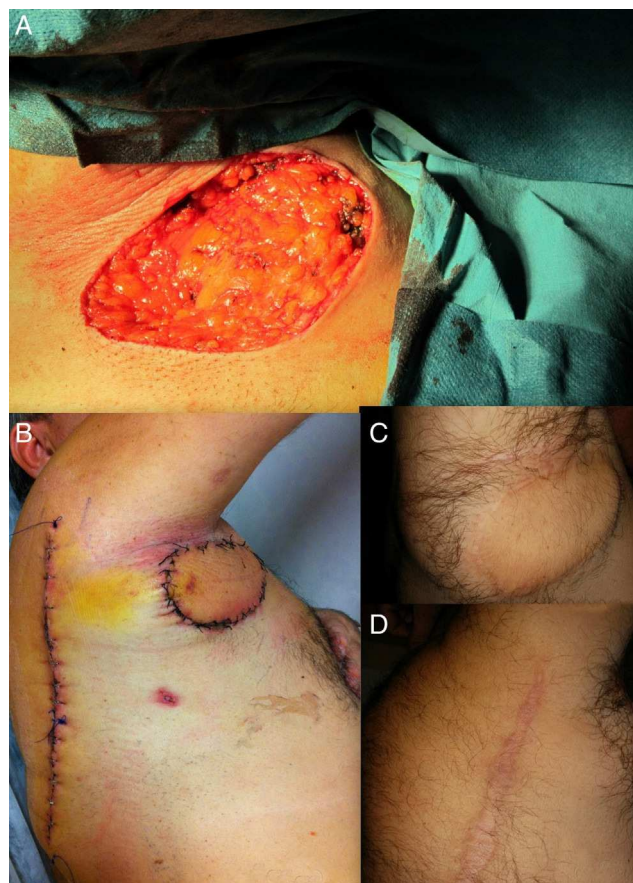


**Figure 1** A, Parascapular flap after dissection, attached only by its vascular pedicle. B, Diagram of the blood supply to the area.

area is created. The flap is passed through the tunnel and is sutured by tissue planes. The defect left by the flap is also sutured by tissue planes (Fig. 2B). The immediate postoperative period is relatively short compared with a graft, and the patient can lead a normal life after the drain has been removed at 4 days. Two years after the operation in our patient there has been no recurrence, which he considers more than satisfactory (Fig. 2C and D). Furthermore, abduction has been fully preserved, as has also been reported by other authors.<sup>3</sup>

### Indications

The pedicled parascapular flap has advantages over the use of grafts as recovery is much faster and the complication rate is much lower.<sup>2</sup> However, operating time is longer (4 hours) than for a graft (between 50 and 120 minutes). Other surgical options to treat axillary hidradenitis include healing by second intention, which has the disadvantage of



**Figure 2** A, Appearance immediately after the en bloc excision of the affected axillary skin, with a surgical margin. B, Surgical wound after removal of the drain 4 days after the operation. C, Healthy axilla 2 years after the operation. D, Partial view of the donor site 2 years after the operation.

a long healing period and the tendency to provoke retractile scars in the area. Direct closure creates tension, which can lead to the progressive appearance of a dehiscence scar. Finally, a rotation flap from the adjacent skin can be a safe alternative, with a minimal risk of necrosis and little postoperative discomfort.

### Complications

Flap necrosis is very unlikely if mobilization is performed carefully, with adequate dissection to avoid tension at the donor site where the artery arises. Torsion and compression of the flap pedicle must be avoided. If the artery is sectioned during the operation, the flap can be used as a graft.

### Conclusions

We have presented a method to treat severe axillary HS. Recovery is rapid and the cosmetic and functional results are magnificent, with a marked improvement in quality of life.

## Conflicts of Interest

The authors declare that they have no conflicts of interest.

## Acknowledgments

We would like to thank Dr. Eliseo Martínez García for the drawing in [Figure 1B](#).

## Appendix A. Supplementary data

Supplementary data associated with this article can be found, in the online version, at [doi:10.1016/j.adengl.2015.07.017](https://doi.org/10.1016/j.adengl.2015.07.017).

## References

1. Carrascosa JM, Bassas J, Puig L. Hidradenitis suppurativa: nuevas oportunidades para una enfermedad dermatológica huérfana. *Actas Dermosifiliogr*. 2015. pii: S0001-7310(15)00070-8. doi: 10.1016/j.ad.2015.01.008. [in press].
2. Wormald JC, Balzano A, Clibbon JJ, Figus A. Surgical treatment of severe hidradenitis suppurativa of the axilla: Thoracodorsal artery perforator (TDAP) flap versus split skin graft. *J Plast Reconstr Aesthet Surg*. 2014;67:1118–24.
3. Busnardo FF, Coltro PS, Olivan MV, Busnardo AP, Ferreira MC. The thoracodorsal artery perforator flap in the treatment of axillary hidradenitis suppurativa: Effect on preservation of arm abduction. *Plast Reconstr Surg*. 2011;128:949–53.