

with topical tacrolimus 0.1% in combination with salicylic acid, indicating their possible therapeutic role in this troublesome localization. We suggest that psoriasis should be considered in cases of refractory long-standing eczema-like cheilitis, even in the absence of a positive family or personal history of psoriasis.

References

1. Sklavounou A, Laskaris G. Oral psoriasis: report of a case and review of the literature. *Dermatologica*. 1990;180:157-9.
2. Tosti A, Misciali C, Cameli N, Vincenzi C. Guess what! Psoriasis of the lips. *Eur J Dermatol*. 2001;11:589-90.
3. Rahman MA, Fikree M. Perioral psoriasis. *J Eur Acad Dermatol Venereol*. 2000;14:521-2.
4. Sehgal VN, Sehgal S, Verma P, Singh N, Rasool F. Exclusive plaque psoriasis of the lips: efficacy of combination therapy of topical tacrolimus, calcipotriol, and betamethasone dipropionate. *J Skin Med*. 2012;10:183.
5. Ersoy-Evans S, Nuralina L, Erkin G, Ozkaya O. Psoriasis of the lips: a rare entity. *J Eur Acad Dermatol Venereol*. 2007;21:142-3.
6. Baz K, Yazici AC, Usta A, Ikizoglu G, Apa DD. Isolated lip involvement in psoriasis. *Clin Exp Dermatol*. 2007;32:578-9.
7. Brenner S, Lipitz R, Llie B, Krakowski A. Psoriasis of the lips: the unusual Köbner phenomenon caused by protruding upper teeth. *Dermatologica*. 1982;164:413-6.
8. Marti N, Pinazo I, Revert A, Jordá E. Psoriasis of the lips. *J Dermatol Case Rep*. 2009;3:50-2.
9. Yamamoto T, Nishioka K. Successful treatment with topical tacrolimus for oral psoriasis. *J Eur Acad Dermatol Venereol*. 2006;20:1137-8.
10. Freeman AK, Linowski GJ, Brady C, Lind L, Vanveldhuisen P, Singer G, et al. Tacrolimus ointment for the treatment of psoriasis on the face and intertriginous areas. *J Am Acad Dermatol*. 2003;48:564-8.

Z. Apalla,^b E. Sotiriou,^{b,*} A. Trigoni,^a D. Ioannides^b

^a State Clinic, Hospital of Skin and Venereal Diseases, Thessaloniki, Greece

^b First Dermatology Department, Aristotle University of Thessaloniki, Greece

*Corresponding author.

E-mail address: elenasotiriou@yahoo.gr (E. Sotiriou).

Use of the Burow Triangle or Wedge-shaped Resection During the Repair of Infraorbital Defects[☆]



Uso del triángulo de Burow o escisión en «V» para la reparación de defectos infraorbitarios

Facial reconstruction surgery requires detailed knowledge of anatomic and functional structures such as the nose, eyelids, and lips, because of the importance of preserving their function, shape, and cosmetic appearance.

Various surgical techniques are available to repair defects; the quickest and simplest reconstruction is by direct closure. First, an ellipse must be created; this involves lengthening the surgical incision to eliminate the excess skin at each end of the incision. One technique used to remove excess skin is the Burow triangle or wedge-shaped resection.¹

The lower eyelid is formed by the orbicularis muscle covered by thin and lax skin. The infraorbital region is the area immediately inferior and medial to the lower eyelid, and the malar region is inferior and lateral to this eyelid; lower down these 2 regions give rise to the cheek. These facial cosmetic areas have different textures, colors, and densities, from a fine skin with minimal subcutaneous cellular tissue in the eyelid to the thicker skin of the cheek, strongly adherent to the subcutaneous cellular tissue.²

In the repair of defects that affect the infraorbital or malar regions, the skin of the cheek is united with the skin of the eyelid, despite these marked differences, and there is the associated risk of provoking eversion of the palpebral margin, separating it from the surface of the eye and producing ectropion.³

We present a simple option for closure that minimizes this possibility.

Surgical Technique

First Step: Design

The elliptical excision must be marked before performing anesthesia because the anesthetic injection will distort the anatomy. A Burow triangle is then designed at the medial end (Fig. 1A).

Second Step: Incision and Dissection of the Skin

It is important to dissect the tissues in the direction of the cheek to achieve better displacement. Do not dissect towards the eyelid because of the fragility of the skin in that area.

Third Step: Anchorage

The first stitch must be placed at the point of greatest tension, which is between points a and a' shown in figure 1 B, C, and D. This is performed with a nonabsorbable intradermal suture.

[☆] Please cite this article as: Molinari LM, Ferrario D, Galimberti GN. Use of the Burow Triangle or Wedge-shaped Resection During the Repair of Infraorbital Defects. *Actas Dermosifiliogr*. 2015;106:689-691.

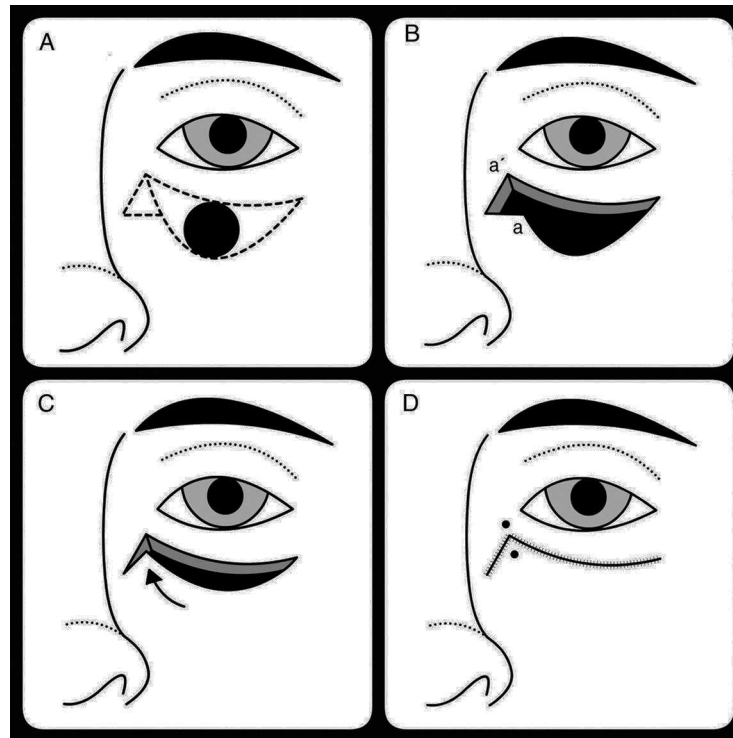


Figure 1 A, Design of the closure; the Burow triangle is designed at the medial end of the incision. B, Anchorage of the ellipse; a to a' orientation of the first stitch. C, Diagonal movement of the skin. D, Final closure. The points indicate the area of greatest tension when the borders are united.

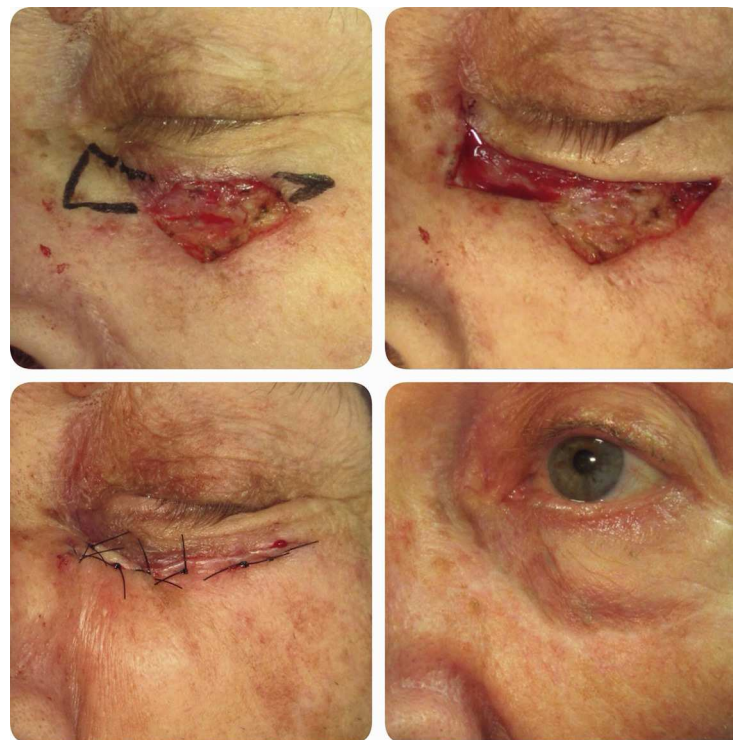

Figure 2 Case 1. Surgical resection of a malignant tumor leaving a defect in the infraorbital region. Closure using a Burow triangle or wedge-shaped resection.

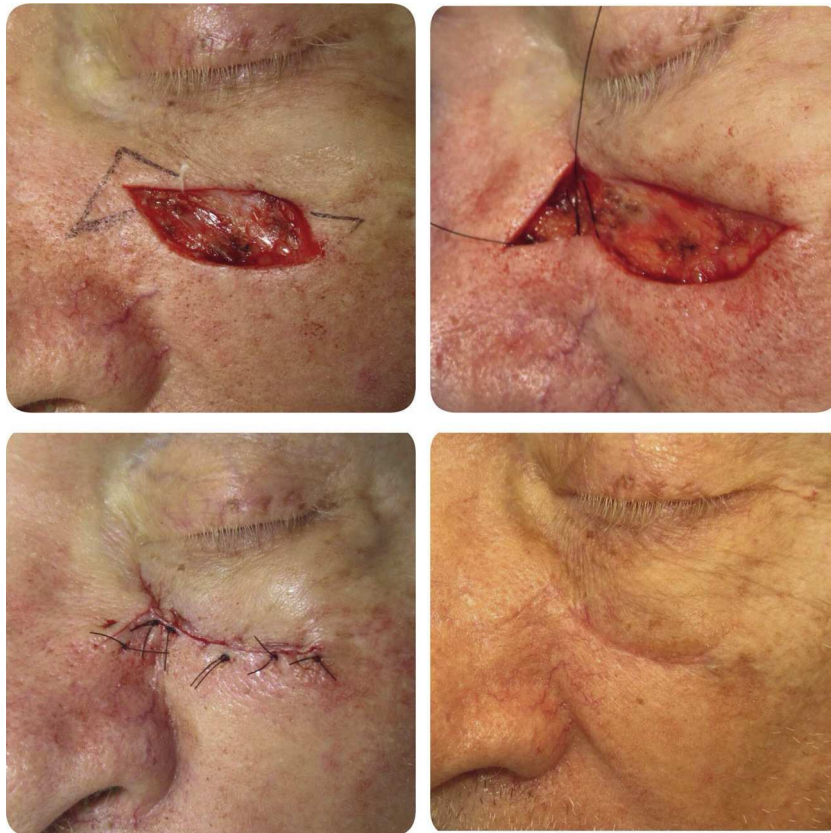

Figure 3 Case 2. Surgical resection of a malignant tumor leaving a defect in the infraorbital region. Closure using a Burow triangle or wedge-shaped resection.

Fourth Step: External Sutures

We prefer to use horizontal U stitches buried in the lower eyelid.

Figures 2 and 3 show patients in whom malignant tumors were excised. Closure of the defect was performed using the technique described.

Important Points

1. It is essential to make the first stitch a to a' in a diagonal orientation (Fig. 1B) to prevent tension perpendicular to free border of the eyelid, which would provoke ectropion.
2. Protect the skin of the lower eyelid, as it is thin and delicate.
3. The intradermal suture can cause ectropion if fibers of the orbicularis muscle are included in the suture.³

Conclusion

We have proposed this technique for infraorbital defects of up to 1 cm diameter. In a previous article we described a rotation-advancement flap for larger defects.⁴

The use of the Burow triangle in the ellipse is not only to remove excess skin, but also to move the point of greatest

tension, transferring it to the medial sector of the eyelid, which will minimize the risk of ectropion (Fig. 1, C and D).

References

1. Pérez Santos S, Marengo Otero R, González-Beato Merino MJ, García Morrás P, Bueno Marco C, Lázaro Ochaíta P. Colgajos de avance con triángulo de Burow en la cara. *Actas Dermosifiliogr.* 2002;93:602–6.
2. Samaniego E, Prada C, Rodríguez-Prieto MA. Planos quirúrgicos en cabeza y cuello. *Actas Dermosifiliogr.* 2011;102:167–74.
3. Robinson JK. The eye and eyelid. In: Roenigk RK, Ratz JL, Roenigk HH, editors. *Roenigk's dermatologic surgery.* 3rd ed New York: Informa Healthcare; 2007. p. 210–5.
4. Galimberti G, Ferrario D, Riveiro Casabona G, Molinari LM. Utilidade do retalho de avanço e rotação para fechamento de defeitos cutâneos na região malar. *Surg Cosmet Dermatol.* 2013;5:76–9.

L.M. Molinari,* D. Ferrario, G.N. Galimberti

Centro de Cáncer de piel y Cirugía Micrográfica de Mohs, Servicio de Dermatología, Hospital Italiano de Buenos Aires, Buenos Aires, Argentina

*Corresponding author.

E-mail address: leisa.molinari@hospitalitaliano.org.ar (L.M. Molinari).