

A. Lobato-Berezo,^{a,*} M.T. Estellés-Pals,^b
M.Á. Gallego-Valdés,^a R. Torres-Perea^c

^a *Departamento de Dermatología, Hospital Universitario Severo Ochoa, Leganés, Madrid, Spain*

^b *Departamento de Neurología, Hospital Universitario Severo Ochoa, Leganés, Madrid, Spain*

^c *Departamento de Medicina Interna, Hospital Universitario Severo Ochoa, Leganés, Madrid, Spain*

*Corresponding author.

E-mail address: allobe@hotmail.es (A. Lobato-Berezo).

Acute Disseminated Paracoccidioidomycosis with Molluscoid Lesions in a Young Woman[☆]



Paracoccidioidomycosis aguda diseminada moluscoide en mujer joven

To the Editor:

Paracoccidioidomycosis (PCM) is a systemic mycosis caused by a dimorphic fungus.

The fungus *Paracoccidioides brasiliensis* lives in the ground and on plants in tropical and subtropical regions. It is endemic to South America and is the most common of the deep mycoses in Paraguay.

Infection occurs by the inhalation of spores during the first decades of life; these spores reach the lungs and can spread to other parts of the body via the blood or lymphatics. The fungus can affect the skin, mucosae, adrenal glands, and other organs.¹⁻⁴

The 2 main clinical presentations of PCM are the chronic form and the acute/subacute form. The chronic form, which accounts for up to 90% of cases, typically affects male farmers between 30 and 60 years of age. The higher frequency in men is due to the presence of 17- β -estradiol receptors in the cytoplasm of *P. brasiliensis*. The interaction between the receptors and the female hormone inhibits transformation of the fungus from the mycelial form to the yeast form; this transformation is essential for infection to develop.³⁻⁷

The acute/subacute form (juvenile type) accounts for less than 10% of cases and is mainly observed in young individuals with a depression of cell-mediated immunity. This form has a rapid clinical course (4 to 12 weeks), with alterations of the monocyte-macrophage system and polymorphous skin lesions (nodular, furunculoid, verrucous, ulcer-granulomatous, molluscoid).^{5,7-9}

The gold standard for diagnosis is culture, which must be performed under strict biosafety measures. The fungus grows as mycelia at room temperature and as the yeast in vitro and in tissues at 37°C.¹⁻⁵ Other diagnostic methods include serology (immunodiffusion), and molecular studies such as polymerase chain reaction.^{1,2,10} Histopathology reveals fungal structures, with well or poorly organized granulomas, depending on the immune response.^{1,7}

Commonly associated infectious diseases include tuberculosis (5%-10%), intestinal parasitoses, Chagas disease, syphilis, other superficial and deep mycoses, and AIDS. Important noninfectious diseases that may be associated with PCM are non-Hodgkin lymphoma and some carcinomas.

An association with smoking has been reported in a high percentage of patients.^{1,5,8}

Patients with severe forms of PCM, with weight loss of over 10%, respiratory difficulty, and neurological symptoms, must be hospitalized.

The treatment of choice is itraconazole, 200-400 mg/d, by mouth for 6 to 12 months; this regimen achieves cure in 88% to 100% of cases, though there is a recurrence rate of 3%. In severe forms, amphotericin B, 0.8-1 mg/kg/d, is administered by intravenous infusion until an improvement is achieved in the clinical manifestations, after which the patient can be changed to oral treatment.^{1-3,7} Other alternatives include trimethoprim-sulfamethoxazole, voriconazole, and fluconazole. Periodic follow-up of clinical, mycologic, radiologic, and immunologic criteria must be performed to determine whether a favorable response to treatment is being achieved. Delays in the initiation of treatment can elevate mortality to up to 30%, and increase the risk of potentially disabling sequelae, such as pulmonary fibrosis.^{1-3,5,7}

We present the case of a 21-year-old housewife, an indigenous woman from a humid and wooded rural region of Paraguay. She had a 2-month history of skin lesions on her back, face, neck, abdomen, and limbs. The patient described a feeling of fever, mainly in the evening, jaundice, dyspnea, asthenia, anorexia, and unquantified weight loss. She denied any underlying diseases, smoking, alcohol consumption, or use of recreational drugs.

Physical examination revealed erythematous-violaceous papules and plaques, some with a central depression and bloodstained scab, mainly on the face (Fig. 1). In addition, jaundice, ascites, and submandibular and cervical lymph nodes of 1.5 to 3 cm diameter were detected. Breath sounds were absent in both lung bases. The patient presented fever of 38.5°C, but her vital signs were stable.

Blood test results were as follows: hemoglobin, 7.4 g/dL; hematocrit, 21%; white cell count, 11 800/ μ L (neutrophils, 82%; lymphocytes, 10%; monocytes, 6%; and eosinophils, 2%); platelets, 124 $\times 10^3$ / μ L; aspartate aminotransferase, 127 U/L (normal value, 32 U/L); alanine aminotransferase 75 U/L (normal value, 33 U/L); alkaline phosphatase, 4694 IU/L (normal value, 300 IU/L); total bilirubin, 10.1 mg/dL; direct bilirubin, 4.8 mg/dL; indirect bilirubin, 6.1 mg/dL; albumin, 1.3 g/dL (normal value, > 3.5 g/dL); prothrombin index, 50%; activated partial thromboplastin time, 45 seconds. Serology for human immunodeficiency virus, syphilis, hepatitis C virus, hepatitis B surface antigen,

[☆] Please cite this article as: Di Martino Ortiz B, Moreno T, Galeano G, Rodríguez M. Paracoccidioidomycosis aguda diseminada moluscoide en mujer joven. *Actas Dermosifiliogr.* 2015;106:597-599.

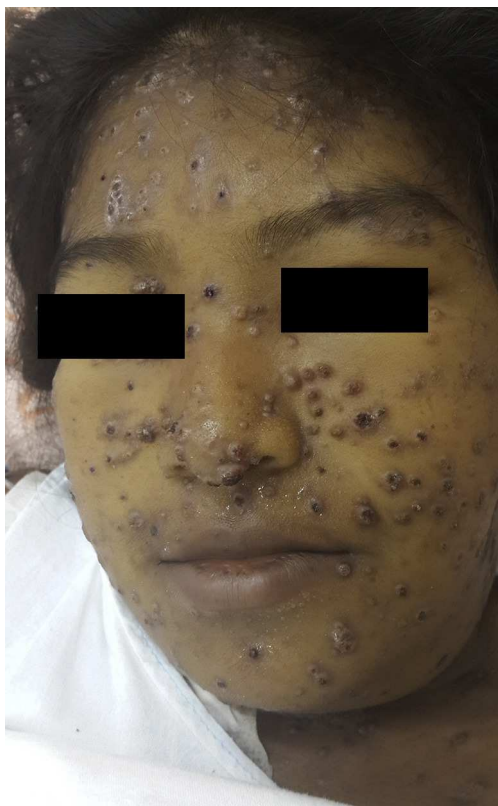

Figure 1 Clinical photograph showing round erythematous-violaceous papules and plaques, some with a central depression and bloodstained scab, on the patient's face. There was also facial edema and jaundice.

and hepatitis A virus was negative. Cultures of sputum and gastric fluid were negative for acid- and alkali-fast bacilli and for fungi.

Abdominal ultrasound revealed hepatomegaly and a large volume of free fluid in the abdominal cavity; there was a bilateral pleural effusion. Abdominal computed tomography showed no involvement of the adrenal glands.

Histopathology confirmed the presence of pseudoepitheliomatous hyperplasia and pandermal suppurative granulomatosis, with multinucleated giant cells and mycotic spores with birefringent cell walls and exosporulation (Fig. 2).

A smear from a lymph node revealed multinucleated giant cells with mycotic spores compatible with *P. brasiliensis*. Based on this information, we made a final diagnosis of acute disseminated PCM.

Treatment was prescribed with 3 g of amphotericin B at a dose of 50 mg/d (although administration had to be interrupted for several days due to transitory alterations of kidney function), leading to an improvement in the skin lesions (Fig. 3), liver function (alkaline phosphatase, 1256 IU/L after 1 month of treatment), and in the patient's general state. Treatment was completed with itraconazole, 200 mg/d, for 6 months after discharge. At the time of writing, the patient has been on treatment for 2 months, with a cumulative dose of amphotericin of 2.5 g. There has been no recurrence.

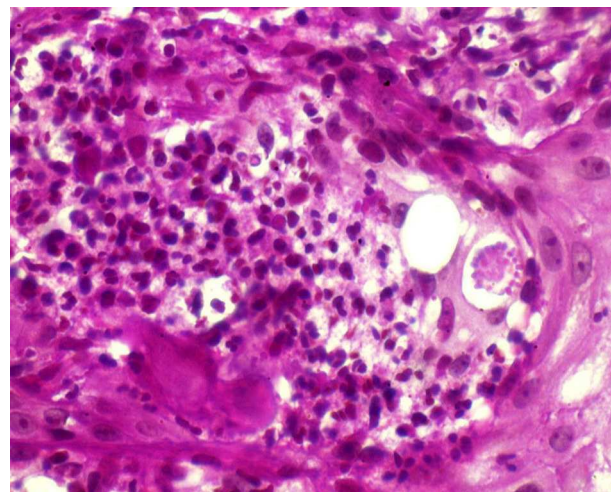


Figure 2 Histopathology revealed mycotic spores with birefringent walls and exosporulation, giving the appearance of boat rudder. Periodic acid Schiff, original magnification $\times 40$.

PCM is characterized by marked polymorphism of the skin lesions, which present as papules, nodules, desquamating erythematous verrucous plaques, and ulcers with a granulomatous base and petechiae; the molluscoid lesions seen in our patient, mainly affecting the face in the area of the nose and mouth, are very rare.¹

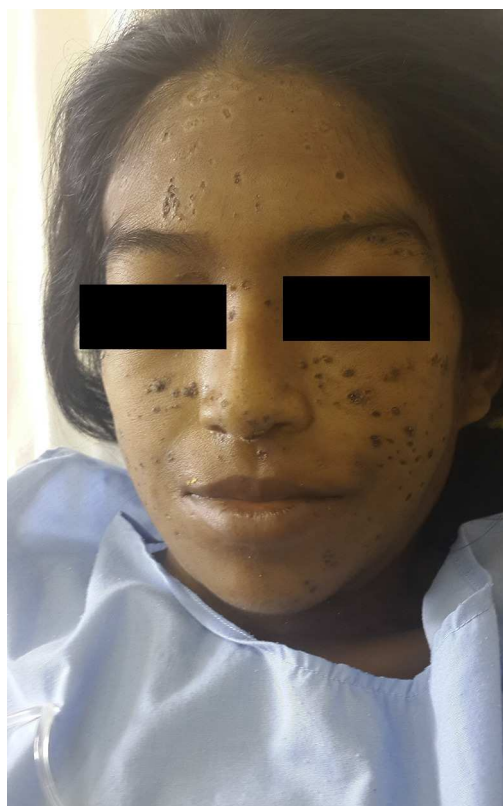

Figure 3 A marked improvement in the lesions was observed at follow-up after 1 month of treatment, with a cumulative dose of 2.5 g of amphotericin B.

This type of molluscoid lesion obliges us to rule out cryptococcosis, histoplasmosis, atypical mycobacteria, molluscum contagiosum, disseminated leishmaniasis, and leprosy.^{1,2,5,7}

We draw attention to the fact that the patient was a young woman of childbearing age who came from an endemic area with favorable environmental conditions for the fungus. She did not present immunosuppression except for malnutrition. Molluscoid lesions were visible mainly on the face, requiring us to rule out a long list of other diagnoses and comorbid conditions. Migratory phenomena make it necessary for dermatologists to be aware of infectious diseases that can arise in other continents.¹⁰

References

1. Marques SA. Paracoccidioidomycosis. *Clin Dermatol.* 2012;30:610–5.
2. Ramos C, Alca E, Melgarejo C, Álvarez P, Puell L, Salomón M, et al. Paracoccidioidomycosis diseminada juvenil. *Folia dermatol Peru.* 2007;18:140–6.
3. Marques SA. Paracoccidioidomycosis: Epidemiological, clinical, diagnostic and treatment up-dating. *An Bras Dermatol.* 2013;88:700–11.
4. Di Martino B, Rodríguez M, Knopfelmacher O. Lesión infiltrada en el labio superior. *Actas Dermosifiliogr.* 2008;99:413–4.
5. Di Martino B, Rodríguez-Oviedo ML, Rodríguez-Masi M. Paracoccidioidomycosis crónica multifocal de tipo adulto en paciente inmunocompetente. *Actas Dermosifiliogr.* 2012;103:645–6.
6. Shankar J, Restrepo A, Clemons K, Stevens DA. Hormones and the resistance of women to paracoccidioidomycosis. *Clin Microbiol Rev.* 2011;24:296–313.
7. Morón Guglielmino C, Ivanov ML, Vereá MA, Pecotche D. Paracoccidioidomycosis. Presentación de la casuística de 10 años y revisión de la literatura. *Arch Arg Dermatol.* 2012;62:92–7.
8. Ballesteros A, Beltrán S, Patiño J, Bernal C, Orduz R. Disseminated juvenile paracoccidioidomycosis diagnosed in a girl in an urban area [Article in Spanish]. *Biomedica.* 2014;34:21–8.
9. Grossklau DdeA, Tadano T, Breder SA, Hahn RC. Acute disseminated paracoccidioidomycosis in a 3 year-old child. *Braz J Infect Dis.* 2009;13:242–4.
10. Buitrago MJ, Cuenca-Estrella M. Epidemiología actual y diagnóstico de laboratorio de las micosis endémicas en España. *Enferm Infecc Microbiol Clin.* 2012;30:407–13.

B. Di Martino Ortiz,* T. Moreno, G. Galeano, M. Rodríguez

Cátedra de Dermatología, Hospital de Clínicas, Facultad de Ciencias Médicas, Universidad Nacional de Asunción, Asunción, Paraguay

*Corresponding author.

E-mail address: beatrizdimartino@gmail.com

(B. Di Martino Ortiz).

Generalized Hypertrichosis Due to Topical Minoxidil[☆]



Hipertrichosis generalizada secundaria a minoxidil tópico

Topical minoxidil solution (TMS) has been used since 1986 to treat androgenetic alopecia.¹ Frequent side effects include local intolerance and itching.² Hypertrichosis has also been observed close to the areas where the solution is applied, mainly the face and especially the temple and the preauricular region.^{2–4} In contrast, generalized or distant hypertrichosis is an uncommon side effect of TMS, and its etiology and pathogenesis remain unknown.

We report the case of a 42-year-old woman diagnosed with androgenetic alopecia who visited our clinic with generalized new hair growth after using 5% TMS for 2 weeks. The patient had been treated with a compounded formulation (5% minoxidil propylene glycol, 0.5% progesterone, and 0.05% clobetasol), which she had been applying twice daily. She remembered having used a random amount and carefully avoiding contact between the product and regions outside the scalp.

The patient reported having a certain amount of vellus facial hair before starting treatment. However, after

2 weeks of treatment, she noticed new growth of body hair, which became darker and thicker. The main regions affected were the forehead, cheeks, beard area, chest, lower back, arms, and legs (Figures 1 and 2). Hormonal tests (follicle-stimulating hormone, prolactin, testosterone, dehydroepiandrosterone sulfate, and δ -4-androstenedione) revealed no abnormalities.

Six months after stopping TMS, the patient's condition began to improve, with persistence of hair on the beard area and trunk. Ten months after stopping treatment, the improvement has persisted, although her condition has not returned to normal.

Between 0% and 5% of patients who receive TMS are affected by hypertrichosis—mainly on the face—caused by local transfer of the product.^{2,3}

Dawber and Rundegren³ studied facial hair growth and hypertrichosis (defined as new hair growth on parts of the body other than the face) as separate entities in women using 5% and 2% TMS compared with placebo. They observed more cases of hypertrichosis in the group treated with 5% TMS (up to 2% of cases after use). They also observed that the adverse effect was more common in women than in men and that within this group, the effect was more common in women aged >50 years and women with facial hair before starting treatment. The facial hair was often vellus hair. Of note, there is a clear association between androgenetic alopecia and hyperandrogenism, which leads to the onset of symptoms such as hirsutism,^{3,5} one of the main risk factors for development of hypertrichosis after treatment with TMS. Furthermore, individuals of Mediterranean, Hispanic, and Middle Eastern ethnicity more often have facial hair.

[☆] Please cite this article as: Gargallo V, Gutierrez C, Vanaclocha F, Guerra-Tapia A. Hipertrichosis generalizada secundaria a minoxidil tópico. *Actas Dermosifiliogr.* 2015;106:599–600.