

hydroxide administration followed by surgical excision. *J Korean Med Sci.* 1999;14:589–92.

4. Reiter N, El-Shabrawi L, Leinweber B, Berghold A, Aberer E. Calcinosi cutis: Part I. Diagnostic pathway. *J Am Acad Dermatol.* 2011;65:1–12.
5. Lekich C, Parsi K. Heterotopic ossification of small saphenous vein and panniculitis ossificans of chronic venous insufficiency presenting with livedo racemosa. *Phlebology.* 2013;29:401–6.
6. Popken F, König DP, Tantow M, Rütt J, Kausch T, Peters KM. Possibility of sonographic early diagnosis of heterotopic ossification after total hip-replacement. *Unfallchirurg.* 2003;106:28–31.
7. Reiter N, El-Shabrawi L, Leinweber B, Berghold A, Aberer E. Calcinosi cutis: Part II. Treatment options. *J Am Acad Dermatol.* 2011;65:15–22.

M. Lorente-Luna,<sup>a,\*</sup> F. Alfageme Roldán,<sup>b</sup>  
C. González Lois<sup>c</sup>

<sup>a</sup> Servicio de Dermatología, Hospital Central de la Defensa Gómez-Ulla, Madrid, Spain

<sup>b</sup> Servicio de Dermatología, Hospital Universitario Puerta de Hierro Majadahonda, Madrid, Spain

<sup>c</sup> Servicio de Anatomía Patológica, Hospital Universitario Puerta de Hierro Majadahonda, Madrid, Spain

\* Corresponding author.

E-mail address: m.lorente.luna@gmail.com  
(M. Lorente-Luna).

## Granulomatous Reactions to Red Tattoo Pigments: A Description of 5 Cases<sup>☆</sup>



### Reacciones granulomatosas a los tatuajes rojos: presentación de 5 lesiones

Tattooing has been practiced for more than 8000 years. During the last 30 years, the practice has spread widely in developed countries.<sup>1</sup>

Complications of tattooing include transmission of infectious diseases (mainly mycobacterial diseases, which are often associated with the color gray, through use of non-sterile water as a diluent), underlying skin diseases resulting from an isomorphic process, and even tumors at the site of the tattoo. Furthermore, injecting a foreign substance into the skin can induce a toxic or immune response.<sup>2</sup>

Table 1 presents the characteristics of the study patients. The first case involved a woman who experienced intense itching and raised red areas after receiving a multicolored tattoo (Fig. 1). The following patient, who had granuloma annulare as a child, experienced itching in the red areas of a multicolored tattoo (Fig. 2A), in which some parts were raised and others eroded, with production of material

(Fig. 2B). Brownish maculopapular lesions appeared 1 month later, taking on an irregular circinate pattern on the dorsum of the foot and distal end of the lower left leg (Fig. 2C). Histopathology of the lesions revealed granuloma annulare. The third patient had received a green and red tattoo, which progressed with subcutaneous nodules that became ulcerated on the red areas (Fig. 2B). The fourth patient complained of itching and inflammation on the red areas of a tattoo placed on her right wrist 15 days earlier. The inflammation progressed to form a large ulcer (Fig. 1C). Five months after the onset of symptoms on the wrist, the patient also complained of inflammation and discomfort on a tattoo that had been placed 5 years previously (Fig. 1D).

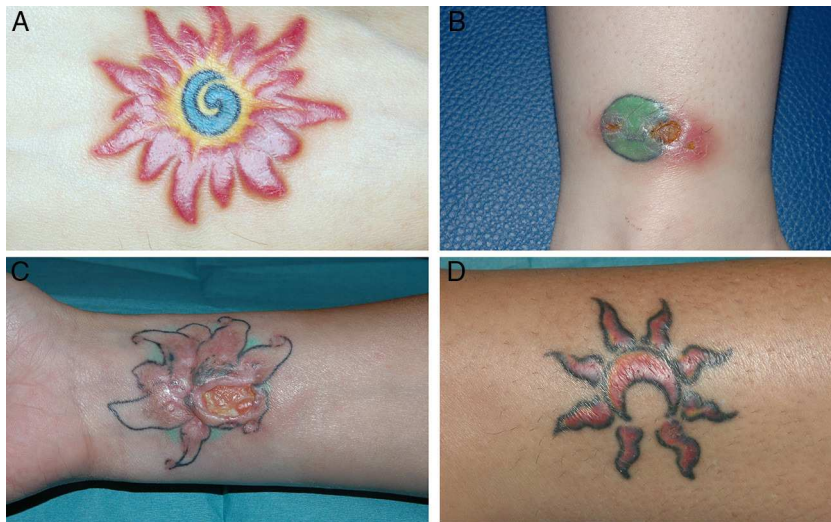Histopathology of the 5 lesions revealed an inflammatory reaction with multiple multinucleated giant cells and pigment compatible with foreign body granuloma (Fig. 3). The results of microbiology studies based on staining and culture (including mycobacteria) were negative for all 5 lesions. In the second case, systemic sarcoidosis was ruled out by chest x-ray and determination of angiotensin-converting enzyme in blood.

Adverse cutaneous hypersensitivity reactions to tattoos are not uncommon and are attributed to the materials injected. Red is the color most commonly associated with

Table 1 Characteristics of 5 Lesions in 4 Patients.

Lesion	Age y	Sex	Time Between Tattoo and Onset of Symptoms	Site	Clinical Appearance	Treatment
1	28	Female	2 y	Right forearm	Erythema/Inflammation	Topical corticosteroids
2	24	Female	4 mo	Dorsum of right foot	Erosion	Intralesional corticosteroid
3	23	Female	1 mo	Right ankle	Ulcer	Topical antibiotic
4	38	Female	15 d	Right wrist	Ulcer	Topical, oral, and intralesional corticosteroids. Excision
5			> 5 y	Left ankle	Erythema/Inflammation	

<sup>☆</sup> Please cite this article as: Martín-Callizo C, Marcoval J, Penín RM. Reacciones granulomatosas a los tatuajes rojos: presentación de 5 lesiones. *Actas Dermosifiliogr.* 2015;106:588–590.



**Figure 1** A, Lesion No. 1: The image shows inflammation of the red areas in a multicolored tattoo. B, Lesion No. 3: The image shows ulceration and inflammation on the red area of a red and green tattoo. C, Lesion No. 4: The image shows a large ulcer in the red areas of a green, red, and black tattoo. D, Lesion No. 5: The image shows inflammation of the red area of a tattoo that first appeared 5 months after the appearance of lesion No. 4 in the same patient.

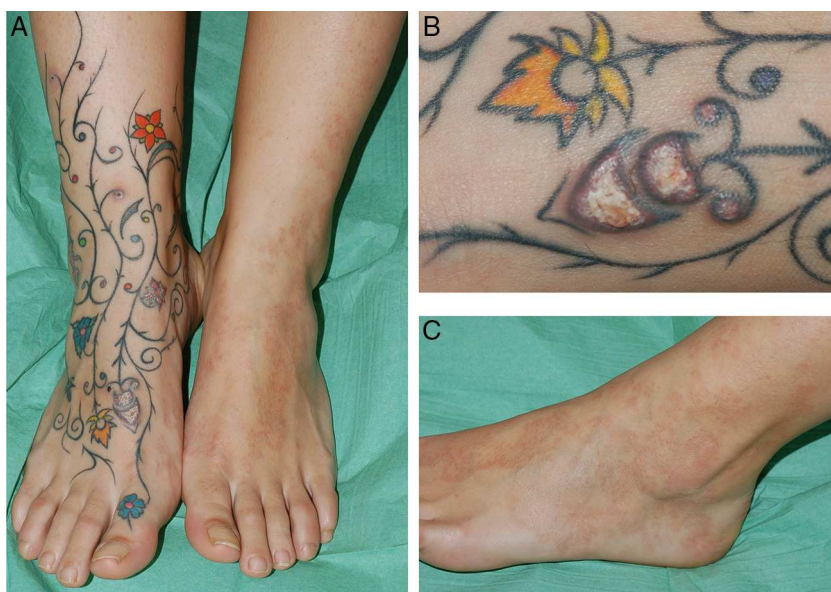adverse reactions. Red tattoo pigments were traditionally made from mercury derivatives, then from cadmium derivatives, which are currently prohibited because of toxicity.<sup>3,4</sup> Today, tattoos contain synthetic organic pigments, which carry a lower risk of adverse reactions. The problem is that there are no strict regulations on pigment content, and most professional tattoo artists do not know the composition of the pigments they use.<sup>1</sup> People receiving a tattoo are for the most part unaware of the substances being injected and of their possible adverse effects. In 2008, the Spanish Agency for Medications and Medical Devices drafted a list of authorized registered products that should not exceed the maximum limits for harmful substances, such as mercury,

lead, and arsenic.<sup>5</sup> In any case, the exact composition of each of the products used is unknown.

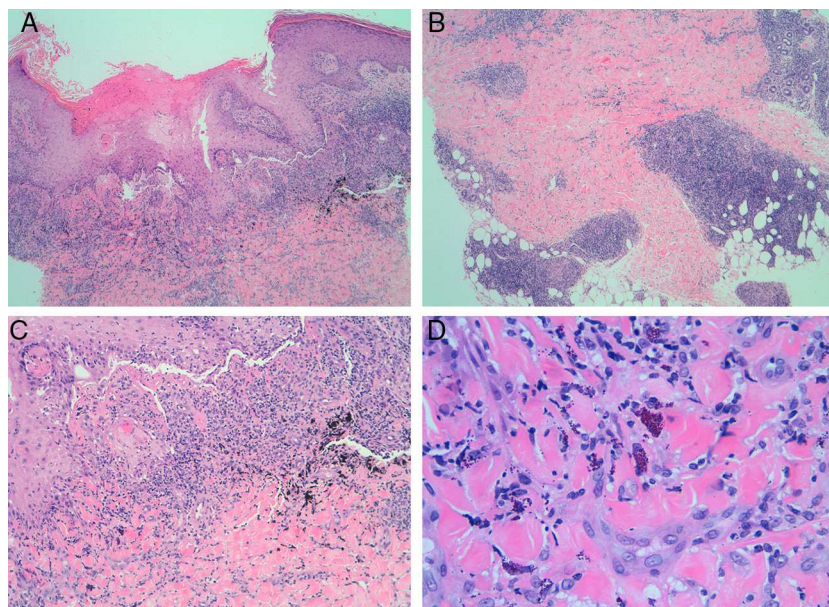
The histopathologic patterns produced by adverse reaction to a tattoo are diverse, the most frequent being a lichenoid pattern. Other types of reactions to tattoos include eczematous, pseudolymphomatous, and scleroderma-like reactions, as well as perforating collagenosis, and, as in the cases we report, granulomatous reactions.<sup>6</sup>

Although very rare, sarcoid granulomas can be found within a tattoo. This finding can be the only clinical manifestation of systemic sarcoidosis.<sup>7</sup>

We observed 1 case of granuloma annulare that occurred simultaneously with and at a distance from a granuloma-



**Figure 2** A, Lesion No. 2: The image shows erosions and release of material to the red areas of a multicolored tattoo on the dorsum of the right foot (B). C, Granuloma annulare lesions can be observed on the dorsum of the left foot.



**Figure 3** Histopathology study of lesions resulting from a granulomatous reaction to a tattoo. Granulomas can be observed in the superficial dermis (A, hematoxylin-eosin [H-E]  $\times 4$ ) and deep dermis (B, H-E  $\times 4$ ). Greater magnification reveals foreign body granulomas around the pigment (C, H-E  $\times 10$ ) and phagocytic cells filled with red pigment (D, H-E  $\times 40$ ).

tous reaction to red tattoo pigment. The literature contains several cases of granuloma annulare limited to the red areas of the tattoo,<sup>8</sup> but not distant lesions. The etiologic and pathogenic mechanisms of granuloma annulare remain unknown, although it is postulated that altered collagen and elastic fibers could trigger the immune response.<sup>9</sup>

Cutaneous reactions to tattoo pigment are treated mainly with topical corticosteroids. Reactions to red pigment have been treated with Q-switched Nd:YAG laser, which carries a risk of severe allergic reactions resulting from lysis of phagocytes and release of pigment into the extracellular space.<sup>10</sup>

The increased frequency of tattooing in our setting means that dermatologists should be aware of potential side effects and able to diagnose them correctly. We believe that people who wish to have a tattoo should be informed of the risk of severe reactions, especially when red pigment is used.

## References

1. Mortimer NJ, Chave TA, Johnston G. Red tattoo reactions. *Clin Exp Dermatol.* 2003;28:508–10.
2. Antony FC, Harland CC. Red ink tattoo reactions: Successful treatment with the Q-switched 532 nm Nd:YAG laser. *Br J Dermatol.* 2003;149:94–8.
3. Bologna JL, Jorizzo JL, Schaffer JV. *Dermatology.* 3rd ed UK: Elsevier; 2012. p. 2269.
4. Ortiz AE, Alster TS. Rising concern over cosmetic tattoos. *Dermatol Surg.* 2012;38:424–9.
5. Ministerio de Sanidad y Consumo. Agencia española de medicamentos y productos sanitarios. Traducción de la resolución del consejo de Europa sobre tatuajes y maquillajes permanentes, 15 jul 2008 [Accessed 8 Sep 2013]. Available at: [http://www.aemps.gob.es/cosmeticosHigiene/cosmeticos/docs/resolucionCE-tatuajes\\_junio-2008.pdf](http://www.aemps.gob.es/cosmeticosHigiene/cosmeticos/docs/resolucionCE-tatuajes_junio-2008.pdf)
6. Polimon I, Ortiz FJ, Comión A, Zarco C, Rodríguez JL, Iglesias L. Reacciones al color rojo de los tatuajes. *Actas Dermosifiliogr.* 2001;92:337–41.
7. Guerra JR, Alderuccio JP, Sandhu J, Chaudhari S. Granulomatous tattoo reaction in a young man. *Lancet.* 2013;382:284.
8. Kluger N, Godenèche J, Vermeulen C. Granuloma annulare within the red dye of a tattoo. *J Dermatol.* 2012;39:191–3.
9. Lynch JM, Barrett TL. Collagenolytic (necrobiotic) granulomas: Part II—the “red” granulomas. *J Cutan Pathol.* 2004;31:409–18.
10. Ashinoff R, Levine VJ, Soter NA. Allergic reactions to tattoo pigment after laser treatment. *Dermatol Surg.* 1995;21:291–4.

C. Martín-Callizo,<sup>a,\*</sup> J. Marcoval,<sup>a</sup> R.M. Penín<sup>b</sup>

<sup>a</sup> Servicio de Dermatología, Hospital Universitari de Bellvitge, L'Hospitalet del Llobregat, Barcelona, Spain

<sup>b</sup> Anatomía Patológica, Hospital Universitari de Bellvitge, L'Hospitalet del Llobregat, Barcelona, Spain

\* Corresponding author.

E-mail address: [claramartincallizo@gmail.com](mailto:claramartincallizo@gmail.com) (C. Martín-Callizo).