




# ACTAS Dermo-Sifiliográficas

Full English text available at  
www.actasdermo.org



## CASE AND RESEARCH LETTERS

### Ultrasound Diagnosis of Calcified Skin Deposits<sup>☆</sup>



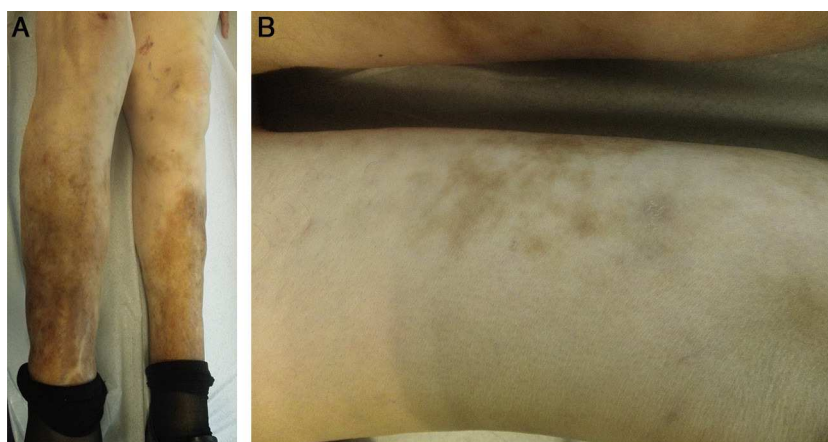
#### Depósitos cálcicos cutáneos diagnosticados mediante ecografía

Calcified deposits in the skin are rare.<sup>1</sup> When they are formed of mature bone with the presence of trabeculae they are called ossification, whereas deposits of amorphous material are called calcification. The presence of calcium on histology is diagnostic, though this can be difficult in some cases. Ultrasound is a rapid, noninvasive technique that provides *in vivo* information that can be very useful for the study of these lesions.<sup>2</sup> We present the case of a 71-year-old woman whose relevant past history included systemic lupus, kidney failure, and secondary hyperparathyroidism. She was on long-term treatment with risendronate, torasemide, allopurinol, and prednisone. She was seen for painful lesions that had arisen on her legs 4 months earlier.

On physical examination, both legs were indurated and presented hyperpigmentation (Fig. 1A) with hard,

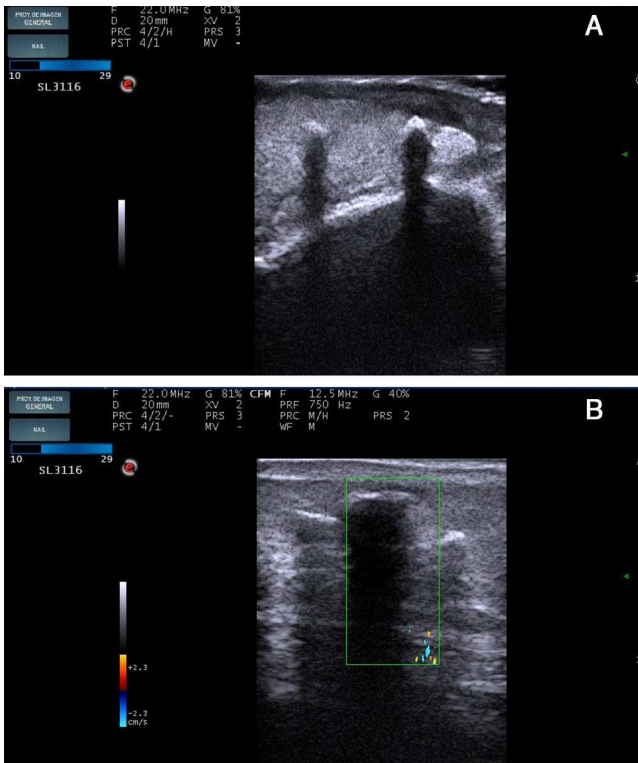
well-defined subcutaneous nodules over which there were brownish-erythematous macules with a reticular pattern (Fig. 1B). The blood tests gave the following results related to her underlying disease: hemoglobin, 10.7 mg/dL; creatinine, 1.8 mg/dL; urea, 119 mg/dL; sodium, 138 mmol/L; potassium, 4.7 mmol/L; parathyroid hormone, 114 pg/mL; calcium, 9 mg/dL; phosphorus, 3.7 mg/dL. Ultrasound study (Esaote My Lab One with a variable frequency linear array of 18-22 MHz with a lateral resolution of 240 μm) demonstrated a thickened and hypoechoic dermis, suggestive of inflammation, and hyperechoic deposits with a density similar to bone and with a linear morphology. These deposits were located in the dermis and in the subcutaneous cellular tissue and left an acoustic shadow (Fig. 2A). Flow was absent on Doppler study (Fig. 2B). Skin biopsy revealed fibrotendinous tissue with mature cartilage (Fig. 3).

Despite the lack of histological confirmation, the diagnosis of calcium deposits was supported by the clinical manifestations and the ultrasound findings. The patient died due to rupture of an aneurysm of an internal iliac artery and no further tests could be performed.



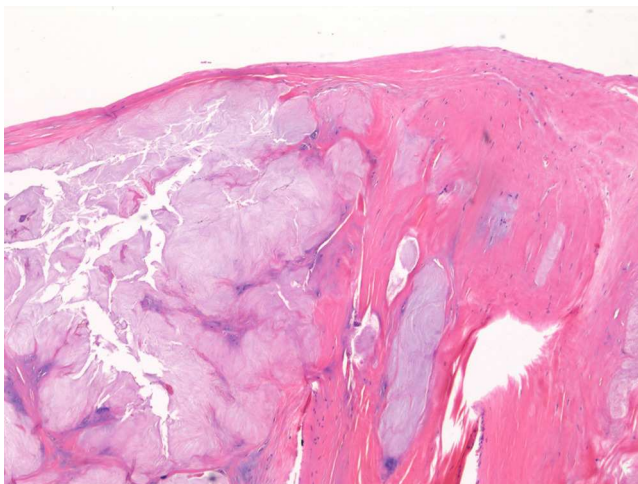
**Figure 1** A, Clinical photograph. Symmetrical involvement of both legs, with hyperpigmentation. B, Clinical photograph. Hard, well-defined subcutaneous nodules over which brownish-erythematous macules with a reticular pattern can be observed.

<sup>☆</sup> Please cite this article as: Lorente-Luna M, Alfigeme Roldán F, González Lois C. Depósitos cálcicos cutáneos diagnosticados mediante ecografía. *Actas Dermosifiliogr.* 2015;106:586–588.



**Figure 2** A, Ultrasound image. B mode: sagittal section showing increased thickness and decreased echogenicity of the dermis, compatible with inflammation, and hyperechoic deposits with a linear morphology that produce an acoustic shadow. The deposits are located in the dermis and in the subcutaneous cellular tissue. B, Ultrasound image. Doppler study: absence of flow.

Soft-tissue calcifications have been associated with rheumatologic disorders, although they are considered rare in systemic lupus erythematosus.<sup>3</sup> Since 1975, soft-tissue calcifications have been classified into various subtypes: metastatic, dystrophic, idiopathic, tumoral, and calciphy-



**Figure 3** Histology. Fibrotendinous tissue with mature cartilage. Hematoxylin-eosin, original magnification  $\times 10$ .

laxis. Metastatic calcifications appear in healthy tissue and are due to changes in phosphorus and calcium metabolism. They are associated with hyperparathyroidism and tumors. Dystrophic calcifications develop without changes in phosphorus and calcium metabolism, in tissues previously damaged by diseases such as lupus, scleroderma, or dermatomyositis. Tumoral calcifications are due to a genetic disorder, with lesions in pressure areas and close to joints. Idiopathic calcifications develop in otherwise healthy individuals. Calciphylaxis is characteristic of patients with advanced chronic kidney failure and is due to calcification of the walls of small vessels.<sup>4</sup> Ossification is much rarer and has primary forms (Albright hereditary osteodystrophy and osteoma cutis) and secondary forms that arise in scars, tissues affected by collagen diseases, and inflammatory lesions due to metaplasia of a preexisting lesion.<sup>1</sup> The deposits are usually asymptomatic and are detected as incidental findings on x-ray. Lesions vary from whitish papules or nodules of firm consistency to skin ulcers. Ossification is harder than calcification. Livedo racemosa is a rare finding and is associated with altered venous drainage.<sup>5</sup> Advanced lesions can cause pain, inflammation, joint deformity, and nerve entrapment. The differential diagnosis is broad. Pilomatrixomas, calcified epidermal cysts, and foreign body reactions must be ruled out when the lesions are localized, whereas panniculitis, lipodermatosclerosis, vasculitis, and vascular ulcers must be excluded when there are widespread or ulcerated lesions with inflammatory signs. To further complicate the situation, any of these dermatoses can coexist with the calcium deposits. On ultrasound, the deposits are hyperechoic, with a similar density to bone, and they produce a posterior acoustic shadow in the case of ossification. Calcifications are less echogenic.<sup>5</sup> Skin deposits are usually oval, whereas they are linear when they arise in blood vessel walls. Ultrasound is considered to be the investigation of choice for the early diagnosis and follow-up of calcium deposits, as it is more sensitive and specific than radiography.<sup>6</sup> Histology is the gold standard. Treatment has not been standardized. Surgical resection, intralesional corticosteroids, carbon dioxide laser therapy, and even intravenous immunoglobulin have been used to treat localized lesions, whereas diltiazem, probenecid, minocycline, aluminum hydroxide, and the bisphosphonates have been employed in widespread lesions, with favorable results in isolated cases.<sup>7</sup> In our patient it was not possible to determine whether the lesions were calcifications or ossifications, though the clinical manifestations and ultrasound findings would suggest they were multiple secondary ossifications. Through our presentation of this case, we would like to draw attention to the increasing importance of skin ultrasound and its indications, particularly for the investigation of calcium deposits, as it has a very high sensitivity for these lesions and can be the key to diagnosis if histology is not conclusive.

## References

1. Urbina F, Pérez L, Sudy E, Misad C. Calcificación y osificación cutánea. *Actas Dermosifiliogr.* 2001;92:255-69.
2. Wortsman X. Common applications of dermatologic sonography. *J Ultrasound Med.* 2012;31:97-111.
3. Park YM, Lee SJ, Kang H, Cho SH. Large subcutaneous calcification in systemic lupus erythematosus: Treatment with oral aluminum

hydroxide administration followed by surgical excision. *J Korean Med Sci.* 1999;14:589–92.

4. Reiter N, El-Shabrawi L, Leinweber B, Berghold A, Aberer E. Calcinosi cutis: Part I. Diagnostic pathway. *J Am Acad Dermatol.* 2011;65:1–12.
5. Lekich C, Parsi K. Heterotopic ossification of small saphenous vein and panniculitis ossificans of chronic venous insufficiency presenting with livedo racemosa. *Phlebology.* 2013;29:401–6.
6. Popken F, König DP, Tantow M, Rütt J, Kausch T, Peters KM. Possibility of sonographic early diagnosis of heterotopic ossification after total hip-replacement. *Unfallchirurg.* 2003;106:28–31.
7. Reiter N, El-Shabrawi L, Leinweber B, Berghold A, Aberer E. Calcinosi cutis: Part II. Treatment options. *J Am Acad Dermatol.* 2011;65:15–22.

M. Lorente-Luna,<sup>a,\*</sup> F. Alfageme Roldán,<sup>b</sup>  
C. González Lois<sup>c</sup>

<sup>a</sup> Servicio de Dermatología, Hospital Central de la Defensa Gómez-Ulla, Madrid, Spain

<sup>b</sup> Servicio de Dermatología, Hospital Universitario Puerta de Hierro Majadahonda, Madrid, Spain

<sup>c</sup> Servicio de Anatomía Patológica, Hospital Universitario Puerta de Hierro Majadahonda, Madrid, Spain

\* Corresponding author.

E-mail address: m.lorente.luna@gmail.com  
(M. Lorente-Luna).

## Granulomatous Reactions to Red Tattoo Pigments: A Description of 5 Cases<sup>☆</sup>



### Reacciones granulomatosas a los tatuajes rojos: presentación de 5 lesiones

Tattooing has been practiced for more than 8000 years. During the last 30 years, the practice has spread widely in developed countries.<sup>1</sup>

Complications of tattooing include transmission of infectious diseases (mainly mycobacterial diseases, which are often associated with the color gray, through use of non-sterile water as a diluent), underlying skin diseases resulting from an isomorphic process, and even tumors at the site of the tattoo. Furthermore, injecting a foreign substance into the skin can induce a toxic or immune response.<sup>2</sup>

Table 1 presents the characteristics of the study patients. The first case involved a woman who experienced intense itching and raised red areas after receiving a multicolored tattoo (Fig. 1). The following patient, who had granuloma annulare as a child, experienced itching in the red areas of a multicolored tattoo (Fig. 2A), in which some parts were raised and others eroded, with production of material

(Fig. 2B). Brownish maculopapular lesions appeared 1 month later, taking on an irregular circinate pattern on the dorsum of the foot and distal end of the lower left leg (Fig. 2C). Histopathology of the lesions revealed granuloma annulare. The third patient had received a green and red tattoo, which progressed with subcutaneous nodules that became ulcerated on the red areas (Fig. 2B). The fourth patient complained of itching and inflammation on the red areas of a tattoo placed on her right wrist 15 days earlier. The inflammation progressed to form a large ulcer (Fig. 1C). Five months after the onset of symptoms on the wrist, the patient also complained of inflammation and discomfort on a tattoo that had been placed 5 years previously (Fig. 1D).

Histopathology of the 5 lesions revealed an inflammatory reaction with multiple multinucleated giant cells and pigment compatible with foreign body granuloma (Fig. 3). The results of microbiology studies based on staining and culture (including mycobacteria) were negative for all 5 lesions. In the second case, systemic sarcoidosis was ruled out by chest x-ray and determination of angiotensin-converting enzyme in blood.

Adverse cutaneous hypersensitivity reactions to tattoos are not uncommon and are attributed to the materials injected. Red is the color most commonly associated with

**Table 1** Characteristics of 5 Lesions in 4 Patients.

Lesion	Age y	Sex	Time Between Tattoo and Onset of Symptoms	Site	Clinical Appearance	Treatment
1	28	Female	2 y	Right forearm	Erythema/Inflammation	Topical corticosteroids
2	24	Female	4 mo	Dorsum of right foot	Erosion	Intralesional corticosteroid
3	23	Female	1 mo	Right ankle	Ulcer	Topical antibiotic
4	38	Female	15 d	Right wrist	Ulcer	Topical, oral, and intralesional corticosteroids. Excision
5			> 5 y	Left ankle	Erythema/Inflammation	

<sup>☆</sup> Please cite this article as: Martín-Callizo C, Marcoval J, Penín RM. Reacciones granulomatosas a los tatuajes rojos: presentación de 5 lesiones. *Actas Dermosifiliogr.* 2015;106:588–590.