

These opportunistic fungi gain entry through injuries or wounds caused by trauma, with most cases involving major trauma, such as traffic accidents, farming accidents (wound contamination) and surgery. There have, however, also been descriptions of infections by Mucorales fungi following minor trauma, including bites and stings. There have been reports of *S. vasiformis* infection in a patient pecked by a magpie<sup>9</sup> and stung by a scorpion.<sup>10</sup> The first case was resolved by wound debridement and administration of amphotericin B, although a skin graft was required to repair the wound defect. In the second case, amputation of the affected leg was necessary.

Infections due to *S. vasiformis* are probably underdiagnosed as these fungi do not easily produce spores in standard fungal media. A high index of clinical suspicion is therefore necessary to ensure early treatment and avoid amputations and fatal outcomes.

## References

1. Skiada A, Rigopoulos D, Larios G, Petrikos G, Katsambas A. Global epidemiology of cutaneous zygomycosis. *Clin Dermatol*. 2012;30:628–32.
  2. Gomes MZR, Lewis RE, Kontoyiannis DP. Mucormycosis caused by unusual mucormycetes, non-Rhizopus, -Mucor and Lichtheimia species. *Clin Microbiol Rev*. 2011;24:411–45.
  3. Cefai C, Elliot TSJ, Nutton RW, Lockett AE, Pooley J. Zygomycetic gangrenous cellulitis. *Lancet*. 1987;330:1337–8.
  4. Gómez Merino E, Blanch Sancho JJ, Iñiguez de Onzoño L, Terancl Juan I, Mateos Rodríguez F, Solera Santos J, et al. Lesión necrótica en cuero cabelludo tras traumatismo. *Rev Clin Esp*. 2003;203:451–2.
  5. García-Martínez J, López-Medrano F, Alhambra A, del Palacio A. Rhinocerebral zygomycosis caused by *Saksenaea vasiformis* in a diabetic patient. *Mycoses*. 2008;51:549–53.
  6. Domínguez MC, Sánchez J, Carmona E, Vergara-López S. Paciente anciana con lesiones cutáneas de rápida progresión. *Enferm Infecc Microbiol Clin*. 2012;30:43–5.
  7. Mayayo E, Stchigel AM, Cano JF, Bernal-Escoté X, Guarro J. Fascitis necrotizante por *Saksenaea vasiformis* en una paciente inmunocompetente tras un accidente de tráfico. *Rev Iberoam Micol*. 2013;30:57–60.
  8. Gómez Camarasa C, Rojo-Martín MD, Miranda-Casas C, Alastruey-Izquierdo A, Aliaga-Martínez L, Labrador-Molina JM, et al. Disseminated infection due to *Saksenaea vasiformis* secondary to cutaneous mucormycosis. *Mycopathologia*. 2014;177:97–101.
  9. Wilson PA. Zygomycosis due to *Saksenaea vasiformis* caused by a Magpie peck. *Med J Austr*. 2008;189:521–2.
  10. Lechevalier P, Hermoso DG, Carol A, Bonacorsi S, Ferkdadji L, Fitoussi F, et al. Molecular diagnosis of *Saksenaea vasiformis* cutaneous infection after scorpion sting in an immunocompetent adolescent. *J Clin Microbiol*. 2008;46:3169–72.
- I.M. Coronel-Pérez,<sup>a,\*</sup> E.M. Rodríguez-Rey,<sup>a</sup>  
L. Castilla-Guerra,<sup>b</sup> M.C. Domínguez<sup>c</sup>
- <sup>a</sup> Servicio de Dermatología, Hospital de la Merced, Área de Gestión Sanitaria de Osuna, Sevilla, Spain  
<sup>b</sup> Servicio de Medicina Interna, Hospital de la Merced, Área de Gestión Sanitaria de Osuna, Sevilla, Spain  
<sup>c</sup> Servicio de Microbiología, Hospital de la Merced, Área de Gestión Sanitaria de Osuna, Sevilla, Spain
- \* Corresponding author.  
E-mail address: mcoronel@aedv.es (I.M. Coronel-Pérez).

## Photoallergic Contact Dermatitis Due to Chlorpromazine: A Report of 2 Cases<sup>☆</sup>



### Queilitis fotoalérgica de contacto por clorpromazina: descripción de 2 casos

#### Case 1

The patient was a 64-year-old woman referred to the skin allergy unit of our dermatology department with a 1-year history of chronic pruritic fissured cheilitis on the lower lip (Fig. 1). The physical examination also revealed dermatitis at the outer margin of the right lower eyelid that appeared in outbreaks, as well as cracked and dyshidrotic dermatitis on the tip of the right thumb that had been present for as long as the cheilitis.

Patch testing was performed with the standard series of the Spanish Contact Dermatitis and Skin Allergy Research Group (GEIDAC) and a cosmetics series. The results were positive for cobalt chloride (+++) with no present relevance.

The patient had been taking Largactil drops (chlorpromazine) 5 mg/24 h to treat irritable bowel syndrome for 1 year.

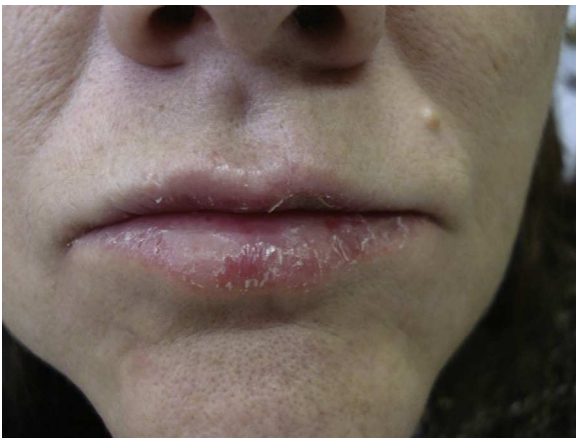Photopatch testing was performed with chlorpromazine 0.1% in petrolatum (irradiation, 5 J/cm<sup>2</sup>). The result for the patch was negative (-), and that of the photopatch was positive (++) . Phototesting was not performed. Given the suspicion of contact photoallergy to chlorpromazine, the drug was switched to levopromazine after patch testing with levopromazine at 1% and 0.1% in petrolatum (patch and photopatch negative).

The patient was free of lesions at a follow-up visit a few weeks later. The condition has been controlled for more than 4 years, with no new outbreaks.

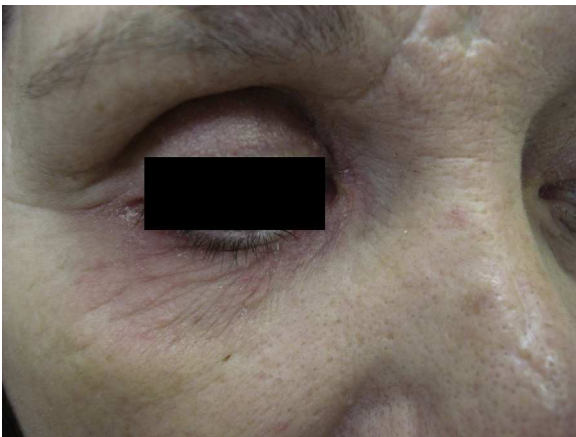
#### Case 2

A 52-year-old woman was referred for possible contact dermatitis on the right lower eyelid that had begun 2 years previously (Fig. 2). She also reported pruritic chronic cheilitis that was sometimes cracked and painful and dated from

<sup>☆</sup> Please cite this article as: Esteve-Martínez A, Ninet Zaragoza V, de la Cuadra Oyanguren J, Oliver-Martínez V. Queilitis fotoalérgica de contacto por clorpromazina: descripción de 2 casos. *Actas Dermosifiliogr*. 2015;106:518–520.



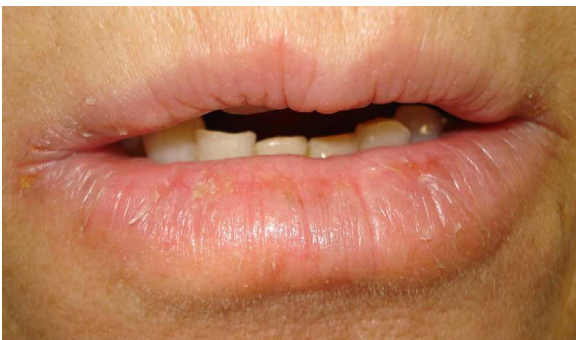**Figure 1** Chronic eczematous involvement of the lip (presenting complaint).



**Figure 2** Eczema affecting the upper and lower eyelids.

the same period (Fig. 3). She wore a polymethyl methacrylate ocular prosthesis as a result of enucleation of the right eye after a traffic accident. She was taking eyedrops (Oftalmosa Cusí hydrocortisone ophthalmic ointment, Terramycin ophthalmic ointment 1%, Oftalmowell eyedrops, and Hidrathea eyedrops), as well as several drugs to treat brain injury sequelae resulting from the accident.

Phototesting was performed, as was patch testing with the standard GEIDAC series, a cosmetic series, an acrylate series, and the patient's own products, including all the ophthalmic ointments and eyedrops. The results were



**Figure 3** Chronic cracked cheilitis.

positive for paraphenyldiamine and mercury, with no present relevance.

Further questioning revealed that one of the drugs she was taking was Largactil drops 3 mg/d.

Given our experience with patient 1, we performed photopatch testing with 0.1% chlorpromazine in petrolatum+UV-A (irradiation, 5 J/cm<sup>2</sup>). The result of the patch was negative (-), and that of the photopatch was positive (++) in the phototest, which was performed while the patient was taking chlorpromazine (3 mg/d), the minimal erythema dose for UV-B (22.7 mJ/cm<sup>2</sup>) and the response to UV-A were considered normal for the patient's skin type (II) and according to local phototesting values.<sup>1</sup>

We also observed dermatitis on the tip of the index finger of the right hand, which was the one used to open the Largactil container, and a punctiform eczematous lesion on the palm, where she sometimes placed the drug before taking it. The patient also reported symptoms of photosensitivity at the onset of her condition (when she was taking chlorpromazine [18 mg/d]), which had not appeared since the dose was reduced to 3 mg/d. Chlorpromazine was switched to levopromazine after photopatch testing with levopromazine at 1% and 0.1% in petrolatum (patch and photopatch negative).

The patient was free of lesions at the follow-up visit 15 days later and has remained asymptomatic for the last 4 years.

## Discussion

Chlorpromazine is a classic antipsychotic drug of the aliphatic phenothiazine class. It can cause allergic contact dermatitis, especially phototoxic and photoallergic reactions. In fact, it is the archetypal photosensitizing drug. Chlorpromazine has been reported to affect patients who take it and persons who handle it, for example, those caring for people treated with chlorpromazine or persons exposed to the drug in the workplace (eg, nurses, pharmacists, and vets).<sup>2-4</sup> In the review of photopatch testing performed by the Spanish Photobiology Group, chlorpromazine 0.1% was positive only twice, and its relevance was unknown.<sup>5</sup>

We present 2 cases of photoallergic contact dermatitis in women taking chlorpromazine. There are no previous reports in the literature of photoallergic contact dermatitis manifesting as chronic fissured cheilitis and caused by chlorpromazine. Both patients had dermatitis on the tips of the fingers used to open the container. This manifestation has been described elsewhere.<sup>3</sup> In addition, both patients had occasional or continuous outbreaks of eyelid eczema on the side of the dominant hand.

Both patients only presented symptoms of contact photosensitivity to the drug despite systemic exposure.<sup>6</sup> The workup should have been completed with phototesting in patient 1 while she was taking the drug in order to ensure the absence of photosensitivity.

Lastly, we also showed that there was no cross-photosensitization between the aliphatic phenothiazines chlorpromazine and levopromazine; therefore, this drug could be a good option in patients with symptoms of photosensitivity caused by chlorpromazine.

## Acknowledgments

We are grateful to Nurse Imma Sierra Talavantes for her incalculable assistance in the diagnostic tests.

## References

1. Martínez Lozano J, Utrillas Esteban MP, Pedrós Esteban R, Tena Sangüesa F, de la Cuadra Oyanguren J, Pérez Ferriols A, et al. Algunas evidencias clínicas sobre la necesidad del calibrado de simuladores solares usados en dermatología. *Actas Dermosifiliogr.* 2001;92:444–51.
2. Emmert B, Schauder S, Palm H, Hallier E, Emmert S. Disabling work-related persistent photosensitivity following photoallergic contact dermatitis from chlorpromazine and olaquinox in a pig breeder. *Ann Agric Environ Med.* 2007;14:329–33.
3. Monteagudo-Paz A, Salvador JS, Martínez NL, Granados PA, Martínez PS. Pulpitis as clinical presentation of photoallergic contact dermatitis due to chlorpromazine. *Allergy.* 2011;66:1503–4.

4. Giomi B, Difonzo EM, Lotti L, Massi D, Francalanci S. Allergic and photoallergic conditions from unusual chlorpromazine exposure: Report of three cases. *Int J Dermatol.* 2010;50:1276–8.
5. De la Cuadra-Oyanguren J, Pérez-Ferriols A, Lecha-Carretero M, Giménez-Arnau AM, Fernández-Redondo V, Ortiz de Frutos FJ, et al. Results and assessment of photopatch testing in Spain: Towards a new standard set of photoallergens. *Actas Dermosifiliogr.* 2007;98:96–101.
6. Barbaud A, Collet E, Martin S, Granel F, Trechot P, Lambert P, et al. Contact sensitization to chlorpromethazine can induce persistent light reaction and cross photoreactions to other phenothiazines. *Contact Dermatitis.* 2001;44:373–4.

A. Esteve-Martínez,\* V. Ninet Zaragoza,  
J. de la Cuadra Oyanguren, V. Oliver-Martínez

*Departamento de Dermatología, Consorcio Hospital General Universitario de Valencia, Valencia, Spain*

\* Corresponding author.

*E-mail address: aemder@gmail.com* (A. Esteve-Martínez).

## Cutaneous Plasmacytosis in a White Man<sup>☆</sup>



### Plasmocitosis cutánea en un varón de raza blanca

A 56-year-old man with no relevant history sought medical attention for asymptomatic rash with onset 1 year earlier. The physical examination revealed multiple brown-red papules distributed symmetrically on the trunk, arms, and buttocks (Fig. 1A and 1B). The Darier sign was negative and neither hepatosplenomegaly nor swollen lymph nodes could be palpated. In the skin biopsy, a perivascular and periadnexal dermal infiltrate was observed, consisting of monomorphic plasma cells, with no atypia or mitoses, with lymphocytes, and scant mastocytes (Fig. 2). Serum lactase dehydrogenase, beta-2-microglobulin, and tryptase, as well as 24-hour N-methyl-imidazole acetic acid in urine were normal. Serology for syphilis, hepatitis B virus, hepatitis C virus, human immunodeficiency virus, and *Borrelia burgdorferi* were negative. The Mantoux test was positive, although we later learned that the patient had received antituberculosis treatment in childhood. Levels of serum proteins and electrophoresis were normal. Determination of immunoglobulin (Ig) by centrifugation revealed slightly decreased IgM, with normal levels of IgG, subclasses of IgG, and IgA. We did not detect Bence Jones proteinuria or free light chains in urine. Histochemical study of the second sample showed predominance of plasma cells (CD138+), which expressed both light Ig chains, demonstrating the polyclonality of the infiltrate, and a normal number of mastocytes (ckit+). Congo red staining ruled out the presence of amyloid deposits. In view of the above findings, cutaneous plasmacytosis was diagnosed and a chest-abdominal-pelvic computed tomography study was

requested along with bone marrow biopsy, though no signs of extracutaneous infiltration were detected. IL-6 serum was normal, and the polymerase chain reaction assay for human herpes virus-8 (HHV-8) was negative. The patient has been in clinical, laboratory, and radiological follow-up for 2.5 years, during which time he has remained stable without treatment and without spread of the disease.

Cutaneous and systemic plasmacytosis is a rare lymphoplasmacytic disorder of unknown cause, reported mainly in middle-aged Japanese men; 11 cases have been reported in the white population.<sup>1–9</sup> Kimura<sup>2</sup> coined the term cutaneous plasmacytosis, with reference to the exclusively cutaneous infiltration by mature plasma cells. Subsequently, Watanabe<sup>2</sup> reported systemic plasmacytosis with infiltration by mature plasma cells in more than 2 organs (including the skin and lymph nodes) accompanied by polyclonal hypergammaglobulinemia.

Clinically, the condition is characterized by persistent and asymptomatic or mildly itchy multiple macules, papules, plaques, and brown-red nodules, distributed symmetrically on the trunk, face, and proximal part of the limbs, without palmoplantar involvement.<sup>10</sup> Simultaneously, or subsequently, extracutaneous manifestations may appear due to infiltration by plasma cells, with enlarged peripheral lymph nodes being the most common finding.<sup>3,6,7,10</sup> Infiltration of bone marrow has also been reported.<sup>6–9</sup> Other findings of extracutaneous infiltration reported include hepatosplenomegaly, interstitial pneumonia, and nephropathy, though histopathological confirmation was not available in most cases.<sup>4–8</sup> Patients with systemic involvement can show constitutional symptoms.<sup>2,3,7–9</sup> Often, polyclonal hypergammaglobulinemia can appear, mainly of IgG and IgA.<sup>2–10</sup> Our patient, however, had an IgM deficit that we did not consider to be clinically relevant. Anemia and increased erythrocyte sedimentation rate or total serum proteins have also been reported.<sup>4–9</sup>

Histologically, skin lesions are characterized by a periadnexal and perivascular dermal infiltrate of mature, polyclonal plasma cells, without atypia, and with a variable

<sup>☆</sup> Please cite this article as: López-Gómez A, Salas-García T, Ramírez-Andreo A, Poblet-Martínez E. Plasmocitosis cutánea en un varón de raza blanca. *Actas Dermosifiliogr.* 2015;106:520–522.