




ACTAS Derma-Sifiliográficas

Full English text available at
www.actasdermo.org



PRACTICAL DERMOSCOPY

Unexpected Diagnosis of Basal Cell Carcinoma[☆]



Diagnóstico «por los pelos»

Case Presentation

A 28 year old man with no significant past medical history and no androgenetic alopecia consulted for a scalp lesion that had been identified by chance following a haircut (Fig. 1). Clinically, the lesion was a poorly defined, completely asymptomatic and lightly pigmented plaque.

Comment

The first diagnosis considered was basal cell carcinoma, although given the patient's age and the site of the lesion a melanocytic lesion with fibrotic features was also a possibility. Dermoscopy revealed a multicolored lesion with poorly defined borders and a bright white spot that corresponded to a milia-like cyst. The dermoscopic findings did not fulfill any of the criteria for a melanocytic lesion, although a few isolated gray-brown globular structures were observed. A single blue-gray rhomboid-ovoid structure was visible in the center of the lesion. While follicular openings were preserved, dark brown granular structures were seen in a perifollicular distribution (Fig. 2).

In consultation with the patient, it was decided to conduct an additional investigation with *in vivo* reflectance confocal microscopy. This revealed refractile nests of nucleated cells with peripheral palisading and dark cleft-like spaces (Fig. 3).

In view of the dermoscopic and confocal microscopy findings consistent with basal cell carcinoma, a complete excision of the lesion was performed and the diagnosis of infiltrative basal cell carcinoma was confirmed histologically (Fig. 4).

The scalp, besides being an anatomical area that is normally hidden, has particular clinical, dermoscopic, and histologic characteristics because it is highly vascularized and has a high density of pilosebaceous units. Consequently

skin lesions on the scalp, in addition to going unnoticed during physical examination, also pose a diagnostic challenge.

Between 13% and 33% of people have a nevus or nevi on the scalp. Of these, up to 5% are considered atypical, a type found more often in young people.^{1,2}

In the present case, since the lesion, had irregular borders and was asymmetric, pigmented, multicolored, and measured more than 6mm in diameter, the differential diagnosis included fibrosing blue nevus and melanocytic nevus with atypical features and fibrosis. Moreover, no

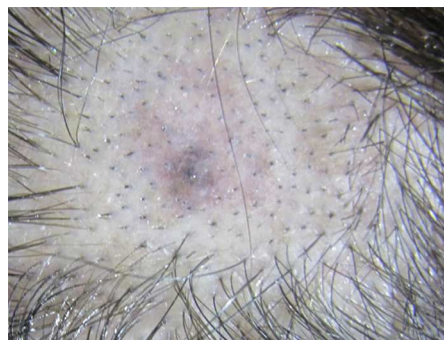

Figure 1 Clinical image of the lesion, an asymptomatic brown macule with poorly defined edges located on the apex of the scalp.

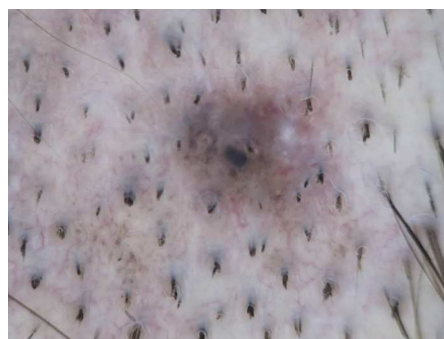

Figure 2 Dermoscopic image showing the asymmetric pattern of structures and irregular edges. The lesion is multicolored, with light and dark brown, blue-gray, and red areas as well as a bright white spot corresponding to a milia-like cyst. Oval structures can be discerned. While the vascular structures are not clearly apparent, fine vessels giving rise to diffuse erythema can be seen.

[☆] Please cite this article as: Pigem R, Gomes A, Bennàssar A, Carrera C. Diagnóstico «por los pelos». Actas Dermosifiliogr. 2015;106:425–426.

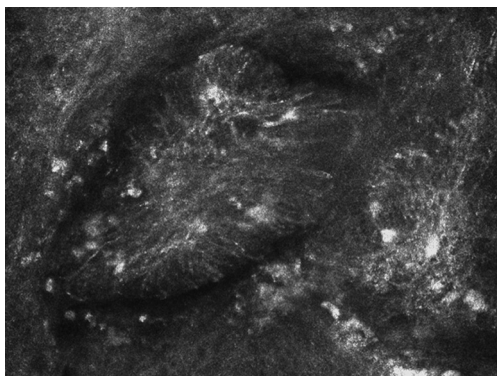


Figure 3 Image obtained using reflectance confocal microscopy showing hyperrefractile groups of cells arranged in nests.

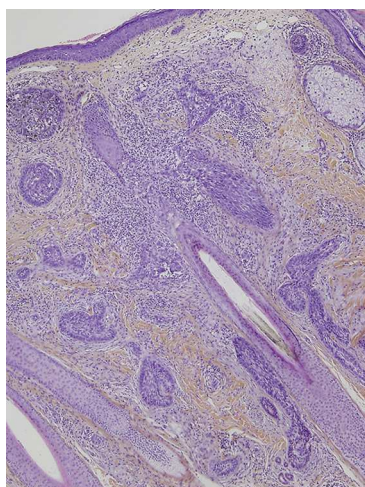


Figure 4 Histologic micrograph showing nests and cords of basaloid cells infiltrating the dermis and a hair follicle cut lengthwise (hematoxylin-eosin $\times 40$).

information was available on the time elapsed since onset. The brown-gray globular structures revealed by dermoscopy could be confused with the actual globules of a melanocytic lesion. We also considered the possibility

that the lesion might be an adnexal tumor—such as a basaloid follicular hamartoma, a trichoepithelioma, or a trichoblastoma—given the presence of a milium-like cyst and perifollicular pigmented structures. The typical dermoscopic features reported for basaloid follicular hamartoma include a globular and cobblestone pattern with white, pink, and deep gray areas, horny plugs, and milium-like cysts.³

This case highlights the importance of a detailed exploration of the scalp since even a young patient with no risk factors may develop an infiltrative basal cell carcinoma. This histologic subtype rarely presents as a hyperpigmented lesion.⁴ Finally, *in vivo* confocal microscopy allowed us to confirm the diagnosis of basal cell carcinoma suspected on the basis of dermoscopic findings, and to perform surgical excision of the lesion immediately.

References

1. Zalaudek I, Schmid K, Niederkorn A, Fink-Puches R, Richtig E, Wolf I, et al. Proposal for clinical-dermoscopic classification of scalp naevi. *Br J Dermatol.* 2014;170:1065–72.
2. De Giorgi V, Sestini S, Grazzini M, Janowska A, Boddi V, Lotti T. Prevalence and distribution of melanocytic naevi on the scalp: A prospective study. *Br J Dermatol.* 2010;162:345–9.
3. Mauleón C, Valdivielso M, Chavarría E, Hernanz JM, Casado I. Simultaneous presentation of localized basaloid follicular hamartoma and epithelioid blue nevus in a 44-year-old patient. *Actas Dermosifiliogr.* 2011;102:233–5.
4. Longo C, Lallas A, Kyrgidis A, Rabinovitz H, Moscarella E, Ciardo S, et al. Classifying distinct basal cell carcinoma subtype by means of dermoscopy and reflectance confocal microscopy. *J Am Acad Dermatol.* 2014;71:716–24.

R. Pigem,* A. Gomes, A. Bennàssar, C. Carrera

Unitat de Melanoma, Servicio de Dermatología, Hospital Clínic, Universitat de Barcelona, Barcelona, Spain

* Corresponding author.

E-mail address: RPIGEM@clinic.ub.es (R. Pigem).