

restoring normal iron levels<sup>4</sup>; this diagnosis had to be considered in our patient as the first biopsies were compatible with this skin disorder.

From a clinical point of view, the differential diagnosis must include other skin conditions that have been described in association with bariatric surgery, such as dermatosis-arthritis syndrome, neutrophilic dermatosis attributed to the formation of circulating immune complexes produced in the blind loop of bowel,<sup>5</sup> and acrodermatitis related to zinc deficiency.<sup>6</sup> We also considered the perforating dermatoses, although no association with bariatric surgery has been reported.

The increase in obesity in western society means that bariatric surgery will become more common. The conclusion from the present case is that patients undergoing bariatric surgery must be followed up closely by a multi-disciplinary team that is aware of the nutritional risks and complications, as well as the appropriate therapeutic strategies that patients must follow for life.

## References

1. Panetta C, Polino G, Muscardin L, Donati M, Danati P. Biliopancreatic diversion: When a cure becomes a disease. *Am J Dermatopathol.* 2014;36:258–9.
2. Zalesin KC, Miller WM, Franklin B, Mudugal D, Rao Buragadda A, Nori-Janosz K, et al. Vitamin A deficiency after gastric bypass surgery: An underreported postoperative complication. *J Obes.* 2011;2011, pii: 760695. doi: 10.1155/2011/760695.
3. Ocón Bretón J, Cabrejas Gómez M, Altemir Trallero J. Frinoderma secundario a déficit de vitamina A en un paciente con derivación biliopancreática. *Nutr Hosp.* 2011;26:421–4.
4. Weijmer MC, Neering H, Welten C. Preliminary report: Furunculosis and hypoferraemia. *Lancet.* 1990;336:464–6.
5. Gómez-Diez E, Mas Vidal A, Soler T, Vázquez-López F, Pérez Oliva N. Vitamin A deficiency and bowel-associated dermatosis-arthritis syndrome secondary to biliopancreatic diversion for obesity. *Actas Dermosifiliogr.* 2010;101:900–2.
6. Cunha SF, Gonçalves GA, Marchini JS, Roselino AM. Acrodermatitis due to zinc deficiency after combined vertical gastroplasty with jejunioileal bypass: Case report. *Sao Paulo Med J.* 2012;130:330–5.

L. Abad,<sup>a,\*</sup> T. Omiste,<sup>b</sup> J. Vera,<sup>c</sup> Y. Gilaberte<sup>d</sup>

<sup>a</sup> *Medicina de Familia y Comunitaria, Hospital San Jorge, Huesca, Spain*

<sup>b</sup> *Servicio de Medicina Interna, Hospital San Jorge, Huesca, Spain*

<sup>c</sup> *Servicio de Anatomía Patológica, Hospital San Jorge, Huesca, Spain*

<sup>d</sup> *Servicio de Dermatología, Hospital San Jorge, Huesca, Spain*

\* Corresponding author.

E-mail address: [laura.abad.polo@gmail.com](mailto:laura.abad.polo@gmail.com) (L. Abad).

## Herpes Zoster in Children Vaccinated Against Varicella-Zoster Virus: Experience in our Hospital<sup>☆</sup>



### Herpes zóster en niños vacunados contra el virus varicela zóster: experiencia en nuestro hospital

To the Editor:

The introduction of the varicella zoster virus (VZV) vaccine was expected to eliminate herpes zoster (HZ) in vaccinated children. However, several years later we continue to treat cases of HZ in children. We describe 8 cases of pediatric HZ that were recorded between 2010 and 2013 during duty shifts at the dermatology service of Hospital Universitario Fundación Alcorcón. During this period the population living in the catchment area of the hospital corresponded to 247 000 inhabitants. The clinical and epidemiological characteristics of the patients are shown in [Table 1](#) and [Figure 1](#). A slight male predominance was observed, with a male to female ratio of 6:2. Ages ranged from 18 months to 5 years

(mean, 3.5 years). All the patients had been vaccinated with a single dose between 15 and 17 months of age. The mean time from vaccination to HZ onset was 2.2 years, with the earliest case detected only 3 months after vaccination. Polymerase chain reaction (PCR) for VZV was performed in 2 cases, both of which were positive. The necessary technique for differentiation between the vaccine and wild strain was unavailable in our hospital. The most frequently affected dermatomes were those of the lower limbs. Treatment varied depending on the extent and duration of the lesions, and the discomfort reported by the patients. Treatment with oral acyclovir was required in 5 of the 8 cases; the remaining patients received topical treatments consisting of astringent soaks and antibiotic ointments. None of the patients had risk factors for immunosuppression or associated comorbidities. Just 3 patients had atopic dermatitis, but none of them had required oral corticosteroid therapy in the preceding year. Six of the 8 patients had undergone laboratory testing in the preceding month, with no abnormalities detected. A favorable clinical course was observed with the prescribed treatments. Subsequent follow-up revealed no complications such as scarring and postherpetic neuralgia or recurrences.

The VZV vaccine is a live attenuated vaccine derived from the Oka strain of VZV. Its use in children under 12 years was approved in 2003 (Varivax). Although the latest guidelines of the Spanish Association of Pediatrics recommend administering 2 doses (the first at 12–15 months and the second at 2–3 years), this dosing schedule is used by only 3 autonomous communities (Ceuta, Melilla, and Navarra).

<sup>☆</sup> Please cite this article as: Caro-Gutiérrez D, López-Esteban J, Naz-Villalba E, Ayala-Bernaldo de Quiros L. Herpes zóster en niños vacunados contra el virus varicela zóster: experiencia en nuestro hospital. *Actas Dermosifiliogr.* 2015;106:329–331.

**Table 1** Clinical and Epidemiological Characteristics of Patients.

Patient	Sex	AD/Asthma	Immunosuppression	Hemogram	Age at Vaccination, mo	→→	Age, mo	Site	PCR	Second Episode	Treatment
1	Girl	AD	No	–	16	43	59	Thigh	No	No	Topical
2	Boy	No	No	Normal	15	7	22	Thigh	+	No	Oral acyclovir
3	Boy	No	No	Normal	15	56	71	Chest	No	No	Oral acyclovir
4	Boy	No	No	Normal	15	29	44	Face	+	No	Oral acyclovir
5	Boy	No	No	-	17	20	37	Ankle	No	No	Oral acyclovir
6	Girl	DA	No	Normal	15	14	29	Thigh	No	No	Topical
7	Boy	DA	No	Normal	15	3	18	Thigh	No	No	Oral acyclovir
8	Boy	No	No	Normal	15	48	63	Arm	No	No	Topical

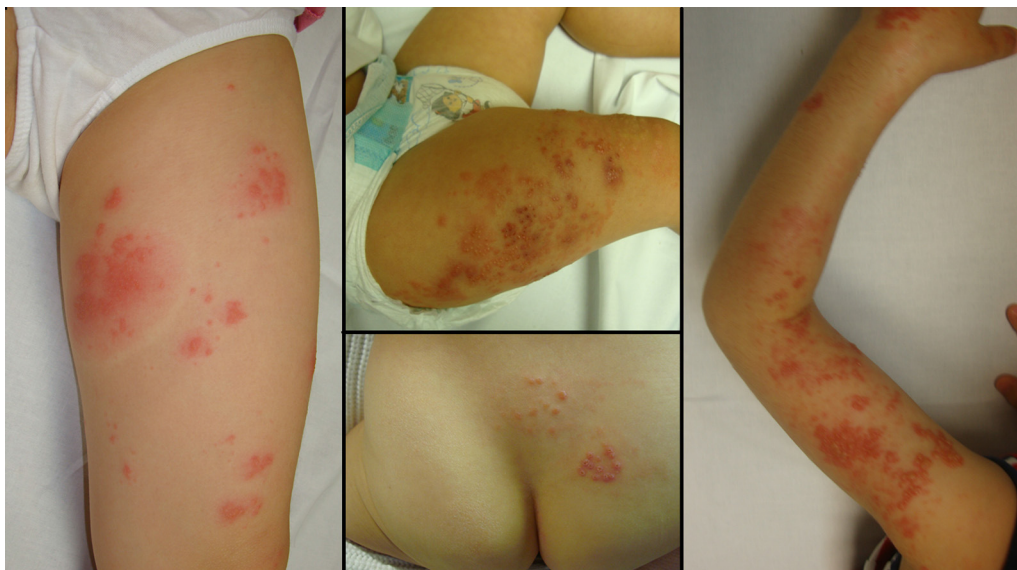Abbreviations: →→, months from vaccination to onset of herpes zoster infection; AD, atopic dermatitis; PCR, polymerase chain reaction.

The general trend is to administer a single dose at 11 to 12 years. Between 2010 and 2013 children in Madrid received a single dose at 15 months, and vaccination was recommended for children aged 11 who were seronegative and had not been previously vaccinated. These recommendations were recently changed, and as of January 1, 2014, vaccination is only recommended for 12-year-olds who have not been previously vaccinated and have not contracted HZ.

A total absence of HZ in vaccinated children was expected with the introduction of the VZV vaccine, but several years later HZ cases continue to be recorded in both vaccinated and healthy children. PCR was performed in some of these cases, and was positive for the Oka strain.<sup>1-4</sup> This strain may be reactivated, causing disseminated zoster (which occurs if antibody titers are low, and is often mistaken for wild-type infection) or metameric zoster.<sup>3</sup> The latter condition is probably underdiagnosed owing to the belief that the vaccine strain is incapable of reactivating, the rarity of HZ in children, and the fact that postvaccination HZ is relatively mild and thus may account for fewer consultations.<sup>3</sup> Reactivation may be more frequent

if titers of anti-VZV are low<sup>3</sup> and if a rash develops after vaccination, as it is postulated that skin lesions enable the passage of VZV to the nerves and the establishment of latent infection.<sup>2,5</sup> Postvaccination HZ is distinguished from HZ after primary infection mainly based on the associated lesions. Postvaccination HZ lesions are generally smaller, less painful, and contain fewer vesicles. Moreover, these lesions predominantly develop on lumbosacral rather than thoracic dermatomes, given the greater proximity of the former to the site of vaccine administration.<sup>6</sup>

In conclusion, we have presented 8 cases of HZ; all patients were under 5 years of age, healthy, and had been vaccinated for VZV. Although cases of reactivation of the Oka strain of VZV have been reported, recent studies found no increase in the incidence of HZ in vaccinated children.<sup>7</sup> However, no epidemiological studies have assessed the true incidence of HZ in children since the introduction of routine vaccination in Spain. Molecular characterization of the virus could provide more information on the incidence of HZ after VZV vaccination.



**Figure 1** Clinical characteristics of the herpes zoster lesions in 4 of the patients in our series.

## References

- Liang MG, Heidelberg KA, Jacobson RM, McEvoy MT. Herpes zoster after varicella immunization. *J Am Acad Dermatol*. 1998;38:761–3.
  - Uebe B, Sauerbrei A, Burdach S, Horneff G. Herpes zoster by reactivated vaccine varicella zoster virus in a healthy child. *Eur J Pediatr*. 2002;161:442–4.
  - Krause PR, Klinman DM. Varicella vaccination: Evidence for frequent reactivation of the vaccine strain in healthy children. *Nat Med*. 2000;6:451–4.
  - Fahlbush M, Wesselmann U, Lehmann P. Herpes zoster after varicella-zoster vaccination. *Hautarzt*. 2013;64:107–9.
  - Sharrar R, LaRussa P, Galea SA, Steinberg SP, Sweet AR, Keatley RM, et al. The postmarketing safety profile of varicella vaccine. *Vaccine*. 2000;19:916–23.
  - Civen R, Chaves SS, Jumaan A, Wu H, Mascola L, Gargiullo P, et al. The incidence and clinical characteristics of HZ among children and adolescents after implementation of varicella vaccination. *Pediatr Infect Dis J*. 2009;28:954–9.
  - Baxter R, Ray P, Tran TN, Black S, Shinefield HR, Coplan PM, et al. Long-term effectiveness of varicella vaccine: A 14-year, prospective cohort study. *Pediatrics*. 2013;131:e1389–96.
- D. Caro-Gutiérrez,<sup>a,\*</sup> J.L. López-Esteban,<sup>a</sup>  
E. Naz-Villalba,<sup>a</sup> L. Ayala-Bernaldo de Quiros<sup>b</sup>
- <sup>a</sup> Servicio de Dermatología, Hospital Universitario Fundación Alcorcón, Madrid, Spain  
<sup>b</sup> Servicio de Pediatría, Hospital Universitario Fundación Alcorcón, Madrid, Spain
- \*Corresponding author.  
E-mail addresses: [carogutierrezd@gmail.com](mailto:carogutierrezd@gmail.com),  
[mdcaro@fhalcorcon.es](mailto:mdcaro@fhalcorcon.es) (D. Caro-Gutiérrez).

## Vertically Orientated Telangiectasias and Pruritus on the Thorax of a Patient With Early Superior Vena Cava Syndrome Secondary to a Malignant Thymoma<sup>☆</sup>



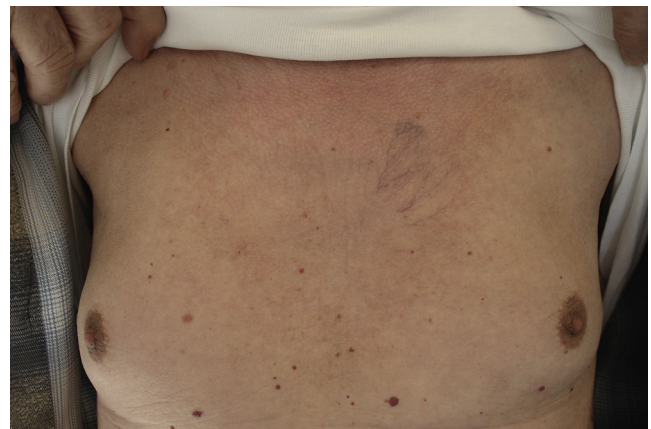
### Telangiectasias verticalizadas y prurito en el tórax en un paciente con síndrome de cava superior inicial secundario a un timoma maligno

Thymoma is the most common primary tumor of the anterior mediastinum. Symptoms are due to compression by the tumor or to various paraneoplastic syndromes. However, 50% of patients are asymptomatic at the time of diagnosis.<sup>1</sup> We describe the case of a patient who developed pruritus and telangiectasias on the trunk as the initial signs of a malignant thymoma.

The patient was a 78-year-old man who was seen in outpatients for the progressive appearance of telangiectasias on the skin of the anterior chest wall over the previous 3 months. He reported that he had previously had a skin rash in the area but that it had resolved by the time of consultation. The patient complained of intense pruritus and malaise that even affected nighttime rest.

He did not report chest pain or respiratory difficulty. His past history included a bladder tumor that was in remission. A chest x-ray and abdominal ultrasound performed 2 years earlier had shown no alterations. Physical examination revealed telangiectasias in a vertical distribution, most prominent on the left hemithorax, with no other changes and

no other dilated, larger caliber vessels (Figs. 1 and 2). There were no relevant findings on examination of the face and neck and no palpable masses or lymph nodes. In view of the intensity of the symptoms reported by the patient, cervical and thoracic computed tomography (CT) was requested to rule out an underlying lesion. The CT revealed a retrosternal mass of 5 × 2.5 cm with enlarged perilesional and pericardial lymph nodes and compression of the superior vena cava (Fig. 3). The differential diagnosis included teratoma, lymphoma, and thymoma. The patient did not report weight loss or night sweats, and his general state of health was normal. Cytology from a fine-needle aspiration biopsy was compatible with thymoma. The patient was evaluated by the thoracic surgeons and the tumor was considered inoperable. The final diagnosis was malignant sclerosing thymoma. Studies of tumor spread excluded metastatic disease and there were no symptoms of paraneoplastic syndromes, such as myasthenia gravis. The patient started combined treatment with adriamycin and radiation therapy with a partial regression of the mass. The telangiectases did not vary, but



**Figure 1** Telangiectasias on the left hemithorax. Examination revealed no other alterations. The rash described by the patient had resolved at the time of diagnosis.

<sup>☆</sup> Please cite this article as: Laguna C. Telangiectasias verticalizadas y prurito en el tórax en un paciente con síndrome de cava superior inicial secundario a un timoma maligno. *Actas Dermosifiliogr*. 2015;106:331–332.