

Successful Treatment of Disseminated Granuloma Annulare With Narrowband UV-B Phototherapy[☆]



Resolución de granuloma anular diseminado con fototerapia UVB de banda estrecha

Disseminated granuloma annulare (DGA) is an inflammatory disease that tends to follow a chronic course and is resistant to multiple treatments.

We report the case of a 80-year-old woman with asymptomatic lesions that had developed 3 years earlier. The lesions initially developed on the arms, later spreading to the abdomen, back, and legs, and improved during the summer months. The patient had undergone treatment with topical corticosteroids for several weeks with no improvement. Her relevant medical history included hypertension and retinal detachment. Physical examination revealed well-defined, annular red-purple plaques several

centimeters in diameter with a smooth surface and a raised edge (Fig. 1, A and B). These plaques were much flatter in sun-exposed areas of the forearms and legs. A biopsy of one of the plaques on the arm showed lymphohistiocytic granulomas in the upper and middle dermis, with degeneration of connective tissue and mucin deposition associated with a lymphocytic inflammatory infiltrate, leading to a diagnosis of DGA. The patient was prescribed several cycles of oral prednisone (30 mg per day in decreasing doses for periods of 6 weeks) and topical corticosteroids (15 days) with no improvement. Although asymptomatic, the plaques were esthetically unpleasant; it was thus decided to treat the patient with phototherapy. Psoralen-ultraviolet-A (PUVA) therapy was ruled out as the patient had experienced 2 episodes of retinal detachment. The patient underwent narrowband ultraviolet-B (NB-UVB) phototherapy 3 times per week for 2.5 months, following a dose escalation protocol for skin phototype II. In total, 27 sessions were performed and the patient received a cumulative dose of 26.155 J/cm². The patient showed good tolerance and an excellent response, with the affected body surface area

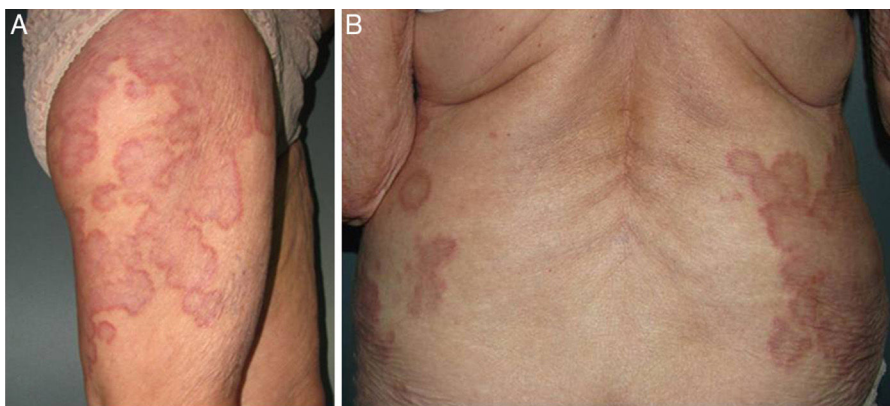


Figure 1 A and B, Right thigh and lumbar region before treatment.

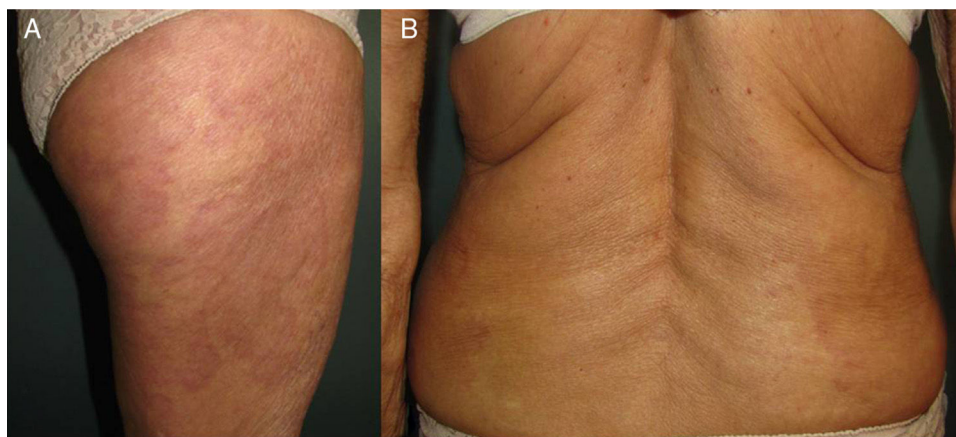


Figure 2 A and B, Right thigh and lumbar region after 27 treatment sessions.

[☆] Please cite this article as: Solano-López G, Concha-Garzón MJ, de Argila D, Daudén E. Successful Treatment of Disseminated Granuloma Annulare With Narrowband UV-B Phototherapy. *Actas Dermosifiliogr.* 2015;106:240-241.

decreasing from 28 to almost 0 (Fig. 2, A and B). Upon discharge, daily sun exposure was recommended.

This is the second reported case of DGA treated with NB-UVB. The only other report in the literature describes a patient who underwent 24 weekly sessions, and received an accumulated dose of 15 J/cm².¹ While that patient's lesions began to improve in the third week, their near total disappearance occurred only after treatment had ended, with no recurrences during 6 months of follow up. In our case, which involved a larger affected body surface area, a higher accumulated dose, and a shorter interval between sessions, the patient remains free of lesions after 1 year of follow up.

A lack of evidence-based treatment guidelines makes DGA treatment challenging for the dermatologist. Around 30 different treatments have been described, mostly in isolated cases or small series, and all with varying results. Among the most commonly used treatments are topical, oral, intralesional, and intramuscular corticosteroids, biological agents, surgery, laser treatment, and phototherapy.² Good results have been described with PUVA, retinoid PUVA, and UVA1.³⁻⁵

In addition to being difficult to treat, recurrences are common in DGA. A retrospective study of 33 patients treated with PUVA found that while 66% showed improvements, most patients experienced recurrences within the first 2 years.⁴ Although several treatment sessions are required for resolution, itching, if present, is relieved early on.

NB-UVB phototherapy, with an emission spectrum of 311-313 nm, has been used for many years to treat psoriasis, and poses a lower risk of erythema and carcinogenicity than broadband UVB. Furthermore, it is well known that NB-UVB exerts a greater suppressive effect on lymphoproliferation and cytokine production than broadband UVB.⁶ NB-UVB has been shown to be safe and efficacious in the treatment of a growing number of dermatological diseases, even in pediatric populations.⁷

Several variables should be considered when selecting systemic treatment for DGA, including the patient's baseline blood evaluations, comorbidities, interactions with other drugs, potential adverse effects, and prior treatments.²

Despite having found only one similar case reported in the literature,¹ we believe that in cases like the present one, in which PUVA was contraindicated, treatment with NB-UVB phototherapy is worth attempting.

References

1. Inui S, Nishida Y, Itami S, Katayama I. Disseminated granuloma annulare responsive to narrowband ultraviolet B therapy. *J Am Acad Dermatol.* 2005;53:533-4.
2. Thornsberry LA, English JC 3rd. Etiology, diagnosis, and therapeutic management of granuloma annulare: An update. *Am J Clin Dermatol.* 2013;14:279-90.
3. Wollina U, Langner D. Treatment of disseminated granuloma annulare recalcitrant to topical therapy: A retrospective 10-year analysis with comparison of photochemotherapy alone versus photochemotherapy plus oral fumaric acid esters. *J Eur Acad Dermatol Venereol.* 2012;26:1319-21.
4. Browne F, Turner D, Goulden V. Psoralen and ultraviolet A in the treatment of granuloma annulare. *Photodermatol Photoimmunol Photomed.* 2011;27:81-4.
5. Schnopp C, Tzaneva S, Mempel M, Schulmeister K, Abeck D, Tanew A. UVA1 phototherapy for disseminated granuloma annulare. *Photodermatol Photoimmunol Photomed.* 2005;21:68-71.
6. Tjioe M, Smits T, van de Kerkhof PC, Gerritsen MJ. The differential effect of broad band vs narrow band UVB with respect to photodamage and cutaneous inflammation. *Exp Dermatol.* 2003;12:729-33.
7. Brazzelli V, Carugno A, Rivetti N, Cananzi R, Barruscotti S, Borroni G. Narrowband UVB phototherapy for pediatric generalized pityriasis lichenoides. *Photodermatol Photoimmunol Photomed.* 2013;29:330-3.

G. Solano-López,* M.J. Concha-Garzón, D. de Argila, E. Daudén

Servicio de Dermatología, Hospital Universitario de la Princesa, Madrid, Spain

*Corresponding author.

E-mail address: guitje1@hotmail.com

(G. Solano-López).

A Tumor in Images: Anetodermic Pilomatrixoma[☆]



Un tumor en imágenes: pilomatrixoma anetodérmico

To the Editor:

Pilomatrixoma or pilomatricoma is a relatively common benign cutaneous tumor that is derived from immature cells in the matrix of the hair follicle. It presents clinically as a slow-growing solid nodular lesion. There are 2 peaks in its incidence, the first during the first 20 years of life and the

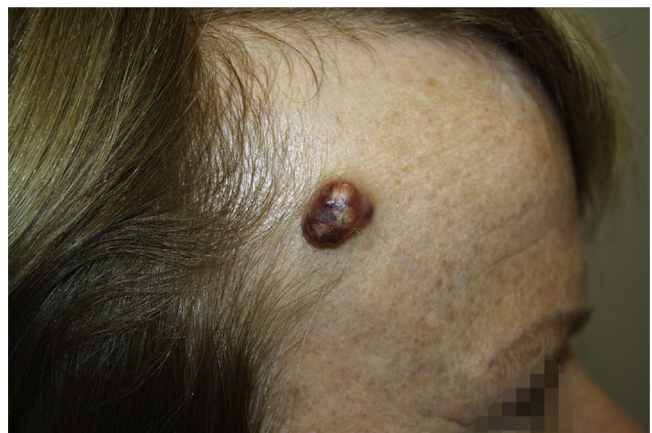

Figure 1 Clinical image showing a multicolor excrecent tumor measuring 15 mm across, with a well-defined border in the right frontoparietal region.

[☆] Please cite this article as: Martínez-Morán C, Echeverría-García B, Nájera L, Borbujo J. Un tumor en imágenes: pilomatrixoma anetodérmico. *Actas Dermosifiliogr.* 2015;106:241-243.