




ACTAS Derma-Sifiliográficas

Full English text available at
www.actasdermo.org



CASE AND RESEARCH LETTERS

***Malassezia* Growth on Peritumoral Skin After Routine Methyl-5-Aminolevulinate Photodynamic Therapy for Actinic Keratosis and Nonmelanoma Skin Cancer**[☆]



Crecimiento de *Malassezia* en Piel Peritumoral Tras Terapia Fotodinámica con Metil-5-aminolevulinato para Queratosis Actínica y Cáncer de Piel No Melanoma

To the Editor:

Malassezia (Pityrosporum) species are lipophilic yeasts that are recognized as commensals of the skin of warm-blooded vertebrates.¹ Aryl-hydrocarbon receptor (AhR) ligands produced by *Malassezia* species have been implicated in carcinogenesis, suggesting that this yeast may contribute to the development of skin cancer, particularly basal cell carcinoma (BCC).² This hypothesis suggests that skin cancer treatments that combine antitumoral and antimicrobial effects may be particularly effective.

We investigated the effect of routine methylaminolevulinate photodynamic therapy (MAL-PDT) on *Malassezia* species present in the flora of peritumoral skin. The participants were patients with non-melanoma skin cancer who were treated with MAL-PDT (Metvix® in combination with Aktelite® red light illumination, 37 J/cm²) in the Dermatology Department of the Hospital General San Jorge (Huesca, Spain) between September and November 2012.

Swab samples were taken from a 2-cm² area of skin within 1 cm of the lesion before and after MAL-PDT. Control swab samples were taken from an adjacent area of healthy skin before and after exposure to red light illumination only. The skin was not prepared before swabbing. Swabs were then

used to immediately inoculate the entire surface of individual Dixon plates, which were incubated at 35 °C.

Malassezia species were identified by micromorphology (morphological microscopy), cultural characteristics (effect of temperature, subculture on Sabouraud agar, growth and appearance on Leeming and Notman agar, Dixon modified media, CHROMagar, and Tween agar), biochemical characteristics (catalase production, bile esculin test), and the assimilation profile when grown on Tween agar.³

All data are presented as the mean and standard deviation (SD). Differences between groups were evaluated using the Mann–Whitney *U* test, Kruskal–Wallis test, and Wilcoxon matched-pairs signed ranked test, assuming a confidence level of 95% (i.e., $P < .05$). Analyses were performed using IBM SPSS software (Version 19.0). The study was approved by the regional ethics committee for clinical research.

Thirty patients (19 men and 11 women) participated in the study. Of these, 19 (63.3%) were treated for actinic keratosis, 10 (33.4%) for BCC, and 1 (3.3%) for Bowen disease. Lesions were most commonly located on the forehead (26.7%) and scalp (23.3%), followed by the nose (16.7%), back (10%), cheek (6.7%), neck (6.7%), chest (6.7%), and ear (3.3%).

In 13 patients *Malassezia* species were detected in both the peritumoral and control areas before treatment. The most commonly found species was *Malassezia globosa* (10 patients), either alone or in combination with other species, followed by *Malassezia sympodialis* (3 patients). Treatment resulted in a decrease in the number of colonies in the peritumoral and control areas in 10 and 8 patients, respectively. The mean number of colonies observed before treatment was 46.00 (50.67) in the peritumoral area and 63.38 (119.44) in the control area. MAL-PDT resulted in a significant decrease in the number of colonies in the peritumoral area (20.46[33.94], $P = .023$); this effect was not observed in the control area after exposure to red light illumination (40.69[61.49], $P = .22$) (Fig. 1).

The decrease in the mean number of colonies induced by MAL-PDT was significantly greater in patients that were positive for both *M. globosa* and *M. sympodialis* (76[15.06]) than in those with *M. globosa* alone (12.36[20.54]) or with other *Malassezia* species ($P = .007$). We found no association between the mean number of *Malassezia* colonies and patient gender ($P = .70$), tumor type ($P = .95$), or tumor location ($P = .21$).

[☆] Please cite this article as: Gilaberte Y, Aspiroz C, Alejandre C, Rezusta A. Crecimiento de *Malassezia* en Piel Peritumoral Tras Terapia Fotodinámica con Metil-5-aminolevulinato para Queratosis Actínica y Cáncer de Piel No Melanoma. Actas Dermosifiliogr. 2015;106:70–71.

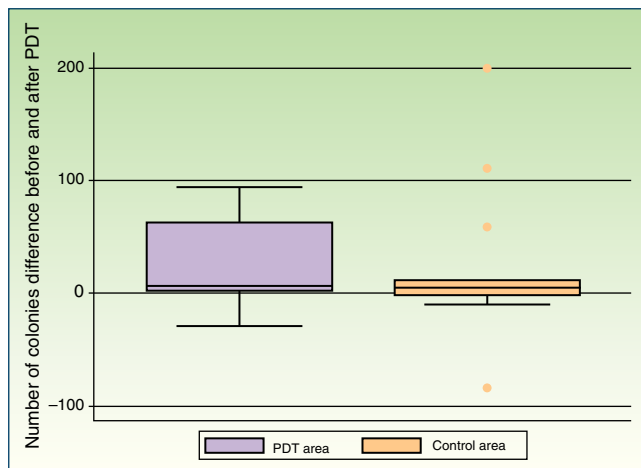


Figure 1 Box plot shows the difference in the number of *Malassezia* colonies before and after exposure of the peritumoral area and the adjacent control area to MAL-PDT and red light illumination, respectively.

Our results demonstrate that routine MAL-PDT attenuates the growth of *Malassezia* species on peritumoral skin. This observation is in line with previous reports describing the effectiveness of MAL-PDT in pityriasis versicolor,⁴ recalcitrant *Malassezia* folliculitis,⁵ and onychomycosis.⁶ The inhibitory effect of MAL-PDT on *M. globosa* was greater than that observed for *M. sympodialis*, suggesting that sensitivity to MAL-PDT varies among *Malassezia* species. In line with this view, differential sensitivity to PDT in vitro has been described for other yeast species, such as *Candida*.⁷ In most patients, we observed a decrease in the number of *Malassezia* colonies in the control area after exposure to red light illumination, in agreement with previous reports describing the inhibitory effects of a red light-emitting diode on the growth of bacteria and yeast.⁸

There are 2 main limitations to our study. First, statistical power was limited by the small sample size, although this effect was somewhat offset by using each patient as their own control. Second, the potential fungicidal effect of MAL in the absence of illumination was not evaluated. While neither aminolevulinic acid nor MAL exert cytotoxic effects when administered in vivo without illumination, high concentrations of aminolevulinic acid can be toxic to certain cell types in vitro.⁹

Bryld and coworkers¹⁰ reported no significant changes in bacterial flora after MAL-PDT. MAL-PDT may be a particularly attractive treatment option if it could effectively eliminate *Malassezia* species without damaging cutaneous bacterial flora, especially if the proposed role of *Malassezia* species in carcinogenesis is confirmed.

In summary, our findings demonstrate that MAL-PDT exerts a significant antifungal effect in vivo against commensal *Malassezia* species in non-melanoma skin cancer.

Acknowledgement

We thank Dr. G. Gaitanis for constructive comments and critical review of the manuscript.

References

1. Crespo Erchiga V, Delgado Florencio V. *Malassezia* species in skin diseases. *Curr Opin Infect Dis*. 2002;15:133–42.
2. Gaitanis G, Velegaki A, Magiatis P, Pappas P, Bassukas ID. Could *Malassezia* yeasts be implicated in skin carcinogenesis through the production of aryl-hydrocarbon receptor ligands. *Med Hypotheses*. 2011;77:47–51.
3. Kaneko T, Makimura K, Abe M, Shiota R, Nakamura Y, Kano R, et al. Revised culture-based system for identification of *Malassezia* species. *J Clin Microbiol*. 2007;45:3737–42.
4. Kim Y, Kim Y. Successful treatment of pityriasis versicolor with 5-aminolevulinic acid photodynamic therapy. *Arch Dermatol*. 2007;143:1218–20.
5. Lee J, Kim B, Kim M. Photodynamic therapy: new treatment for recalcitrant *Malassezia* folliculitis. *Lasers Surg Med*. 2010;42:192–6.
6. Aspiroz C, Gilaberte Y, Paz-Cristóbal P, Rezusta A. Distal onycholysis resolved with photodynamic therapy in an elderly patient on multiple medication. *Enferm Infecc Microbiol Clin*. 2011;29:626–8.
7. Rezusta A, López-Chicón P, Paz-Cristobal MP, Alemany-Ribes M, Royo-Díez D, Agut M, et al. In vitro fungicidal photodynamic effect of hypericin on *Candida* species. *Photochem Photobiol*. 2012;88:613–9.
8. Peloi LS, Soares RR, Biondo CE, Souza VR, Hioka N, Kimura E. Photodynamic effect of light-emitting diode light on cell growth inhibition induced by methylene blue. *J Biosci*. 2008;33:231–7.
9. McCarron P, Donnelly R, Gilmore B, Woolfson A, McClelland R, Zawislak A, et al. Phototoxicity of 5-aminolevulinic acid in the HeLa cell line as an indicative measure of photodynamic effect after topical administration to gynecological lesions of intraepithelial form. *Pharm Res*. 2004;21:1871–9.
10. Bryld L, Jemec G. The bacterial flora of the skin surface following routine MAL-PDT. *J Dermatolog Treat*. 2006;17:222–3.

Y. Gilaberte,^{a,b,*} C. Aspiroz,^{b,c} C. Alejandro,^d A. Rezusta^{b,e}

^a Unit of Dermatology, Hospital San Jorge, Huesca, Spain

^b Health Science Institute of Aragón, Zaragoza, Spain

^c Microbiology Section, Hospital Royo Villanova, Zaragoza, Spain

^d Laboratory of Microbiology, Municipal Institute of Public Health, Zaragoza, Spain

^e IIS Aragón, Department of Microbiology, University Hospital Miguel Servet, University of Zaragoza, Zaragoza, Spain

* Corresponding author.

E-mail addresses: ygilaberte@salud.aragon.es, ygilaberte@gmail.com (Y. Gilaberte).