

2. Johnstone MA, Albert DM. Prostaglandin-induced hair growth. *Surv Ophthalmol.* 2002;47 Suppl 1:S185-202.
3. Law SK. Bimatoprost in the treatment of eyelash hypotrichosis. *Clin Ophthalmol.* 2010;4:349-58.
4. Demitsu T, Manabe M, Harima N, Sugiyama T, Yoneda K, Yamada N. Hypertrichosis induced by latanoprost. *J Am Acad Dermatol.* 2001;44:721-3.
5. Inoue K, Wakakura M, Inoue J, Matsuo H, Hara T, Tomita G. Adverse reaction after use of latanoprost in Japanese glaucoma patients. *Nippon Ganka Gakkai Zasshi.* 2006;110:581-7.
6. Monselise A, Shapiro J, Lui H. Inner canthus hypertrichosis: a side effect of prostaglandin analogue treatment for glaucoma. *J Cutan Med Surg.* 2011;15:298-9.
7. Ortiz-Perez S, Olver JM. Hypertrichosis of the upper cheek area associated with travoprost treatment of glaucoma. *Ophthal Plast Reconstr Surg.* 2010;26:376-7.
8. Rouxel AM, Roguedas-Contios AM, Misery L. Malar and ciliary hypertrichosis induced by bimatoprost. *Ann Dermatol Venereol.* 2007;134:780-1.
9. Hart J, Shafranov G. Hypertrichosis of vellus hairs of the malar region after unilateral treatment with bimatoprost. *Am J Ophthalmol.* 2004;137:756-7.
10. Mukhopadhyay R, Plumb A. A rare complication from prostaglandin analogue therapy. *Clin Exp Optom.* 2009;92:137-8.
11. Chen CS, Wells J, Craig JE. Topical prostaglandin F(2alpha) analog induced poliosis. *Am J Ophthalmol.* 2004;137:965-6.
12. Alm A, Grierson I, Shields MB. Side effects associated with prostaglandin analog therapy. *Surv Ophthalmol.* 2008;53 Suppl 1:S93-105.

S. Özyurt,^{a,*} G. Seyman Çetinkaya^b

^a *Dermatology Clinic, İzmir Atatürk Education and Research Hospital, İzmir, Turkey*

^b *Internal Medicine Clinic, İzmir Atatürk Education and Research Hospital, İzmir, Turkey*

* Corresponding author.

E-mail address: ozyurtselcuk@yahoo.com (S. Özyurt).

Skin Self-examination Using Smartphone Photography to Improve the Early Diagnosis of Melanoma[☆]



Autocontrol fotográfico mediante smartphones para mejorar el diagnóstico precoz del melanoma

To the Editor:

Patient skin self-examination has proven to be very useful in the secondary prevention of melanoma.¹⁻⁴ Various studies show that campaigns to raise awareness and to encourage skin self-examination make it possible to diagnose thinner melanomas, thus improving prognosis.⁵ Self-examination can be optimized by taking photographs according to a specific protocol.⁶ This photographic record facilitates identification of new lesions and reveals significant changes in existing ones. An additional advantage of photographic self-examination systems is that they improve patient adherence and accuracy in self-examination.² Other useful measures in photographic self-examination include comparison of photographs against mole mapping diagrams⁷ and visual images of benign and malignant lesions.

At present, photographic self-examination by patients aimed at secondary prevention of melanoma is not a habitual practice,⁸ even though it has proven to be effective.¹⁻⁴ The reasons for this observation include ignorance of the importance of photographic surveillance, the inconvenience

of taking photographs with a camera from which the images then have to be downloaded and stored on a computer, and the lack of adherence to self-examination due to forgetfulness.

We present a technology-based solution to foster patient self-examination, namely, an application for smartphones (FotoSkin®) that enables patients to take regular photographs of their skin according to a specific protocol (mole mapping). These photographs can then be taken to the clinic in order to provide the dermatologist with a more accurate picture of how moles and other types of skin lesions are evolving (Fig. 1). The application also includes 3 sections aimed at improving patients' knowledge of skin cancer, raising awareness, and, therefore, promoting adherence to self-examination and visits to the dermatologist. The sections are the following: 1) an information section showing the patient the differences between benign lesions and suspicious or malignant lesions; 2) a section with algorithms to determine the phototype, risk of melanoma, and level of actinic damage; and 3) a dynamic section showing the local UV index and providing practical advice on photoprotective measures and healthy sun exposure.

The main objective of FotoSkin® is to act as a photographic record of the patient's moles and other skin lesions that can later be shown to the dermatologist at checkups (Fig. 2). Visualization of changes in the lesions thus improves the dermatologist's diagnostic accuracy and even improves secondary prevention of the melanoma by enabling the patient to see whether the lesions are new or have changed,¹ as well as encouraging the patient to adhere to self-examination and checkups. The secondary objective of FotoSkin® is to improve health education about melanoma, skin cancer, and healthy sun exposure habits.

The application was designed for smartphones and tablets, both of which have several advantages over a computer,⁹ namely, ease of use, rapid photographs and

[☆] Please cite this article as: Vañó-Galván S. Autocontrol fotográfico mediante smartphones para mejorar el diagnóstico precoz del melanoma. *Actas Dermosifiliogr.* 2015;106:75-77.



Figure 1 General design of the smartphone application FotoSkin®.

storage, automatic reminders about self-examinations, and, in particular, portability (patients can take their photographs with them when they visit the dermatologist). FotoSkin® is free to download and use and is available for iOS (iPhone, iPad) and for Android.

In conclusion, new technology can help to improve skin self-examination in secondary skin cancer prevention by means of systematized whole-body photographic mapping, reminders, and visits to the dermatologist. It can also help to improve health education and encourage patients to become actively involved in the care and surveillance of their skin.

Funding

The FotoSkin® application was funded by ISDIN. However, ISDIN did not participate in the preparation of the content included in the application.

Conflicts of Interest

The authors declare that they have no conflicts of interest.

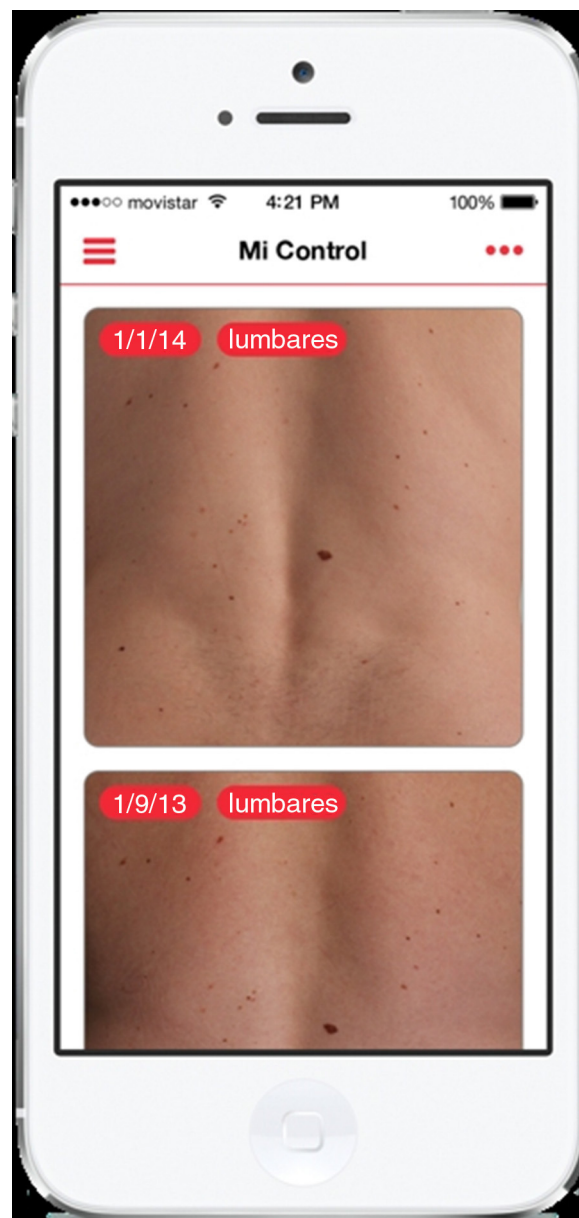


Figure 2 Patient self-examination screen.

References

1. Oliviera SA, Chau D, Christos PJ, Charles CA, Mushlin AI, Halpern AC. Diagnostic accuracy of patients in performing skin self-examination and the impact of photography. *Arch Dermatol.* 2004;140:57–62.
2. McWhirter JE, Hoffman-Goetz L. Visual images for patient skin self-examination and melanoma detection: A systematic review of published studies. *J Am Acad Dermatol.* 2013;69:47–55.
3. Yagerman S, Marghoob A. Melanoma patient self-detection: A review of efficacy of the skin self-examination and patient-directed educational efforts. *Expert Rev Anticancer Ther.* 2013;13:1423–31.
4. Lee KB, Weinstock MA, Risica PM. Components of a successful intervention for monthly skin self-examination for early detection of melanoma: The «Check It Out» trial. *J Am Acad Dermatol.* 2008;58:1006–12.

5. Mitchell JK, Leslie KS. Melanoma death prevention: Moving away from the sun. *J Am Acad Dermatol.* 2013;68:e169–75.
6. Shenoy R, Molenda MA, Mostow EN. The introduction of skin self-photography as a supplement to skin self-examination for the detection of skin cancer. *J Am Acad Dermatol.* 2014;70:e15.
7. Chiu V, Won E, Malik M, Weinstock MA. The use of mole-mapping diagrams to increase skin self-examination accuracy. *J Am Acad Dermatol.* 2006;55:245–50.
8. Korta DZ, Saggar V, Wu TP, Sanchez M. Racial differences in skin cancer awareness and surveillance practices at a public hospital dermatology clinic. *J Am Acad Dermatol.* 2014;70:312–7.
9. Ozdalga E, Ozdalga A, Ahuja N. The smartphone in medicine: A review of current and potential use among physicians and students. *J Med Internet Res.* 2012;14:e128.

S. Vañó-Galván, * J. Paoli, L. Ríos-Buceta, P. Jaén

Servicio de Dermatología, Hospital Ramón y Cajal, Madrid, Spain

*Corresponding author.

E-mail address: sergiovano@yahoo.es (S. Vañó-Galván).