

ACTAS Derma-Sifiliográficas

Full English text available at
www.actasdermo.org



VIDEOS OF SURGICAL PROCEDURES IN DERMATOLOGY

Combined Cutaneous Rotation Flap and Myomucosal Tongue Flap for Reconstruction of an Upper Lip Defect



Combinación de colgajo cutáneo de rotación con colgajo mio-mucoso de lengua para la reconstrucción de defecto del labio superior

A.F. Massa^{a,b,*}, M. Otero-Rivas^b, B. González-Sixto^b, M.Á. Rodríguez-Prieto^b

^a Dermatology Department, Centro Hospitalar de V.N.Gaia/Espinho, EPE, Vila Nova de Gaia, Portugal

^b Dermatology Department, Complejo Asistencial Universitario de León, León, Spain

Introduction

The upper lip is a rare site for nonmelanoma skin cancer. This lip suffers considerably less actinic damage than the lower lip, and reports of upper lip reconstruction are therefore scarce.

Lip reconstruction is a challenge to the dermatological surgeon, particularly when there are full-thickness defects. Adequate opening of the oral orifice must be ensured, without altering sphincter function, and good symmetry of the mouth with correct apposition of the vermilion must be achieved.

We report the case of a white man aged 70 years who presented a recurrent squamous cell carcinoma of the upper lip with an adjacent basal cell carcinoma. Three stages of Mohs micrographic surgery were required to remove the lesions, leaving a full-thickness defect of 3.5 cm×2 cm affecting the left lateral subunit of the upper lip, with a minimal defect at the commissure (Fig. 1).

Procedure

Reconstruction was performed in two stages.

First Operation

For the first stage of the repair, performed under local anesthesia, we designed a cutaneous rotation flap with a lateral pedicle on the left half lip, undermining at the level of the muscle plane.¹ This flap was then positioned in the skin defect of the lip, reaching the vermilion border (Klein's line). The subcutaneous tissue plane was sutured with absorbable 4/0 polyglycolic acid sutures and the skin with 4/0 silk. A new commissure was fashioned by direct closure of the small mucosal defect.

We then designed an ipsilateral tongue flap of approximately the same width as the remaining defect. This flap was undermined in the muscle plane to provide a myomucosal flap to replace not only the vermilion of the upper lip but also the resected part of the orbicularis oris muscle. Flap dissection had to be continued 1 cm beyond the lateral border of the tongue to facilitate advancement of the flap into the defect. The lateral mucosal tongue flap, still attached to the tongue at its inferior border, was sutured to the cuta-

* Corresponding author.

E-mail address: antoniofmassa@gmail.com (A.F. Massa).

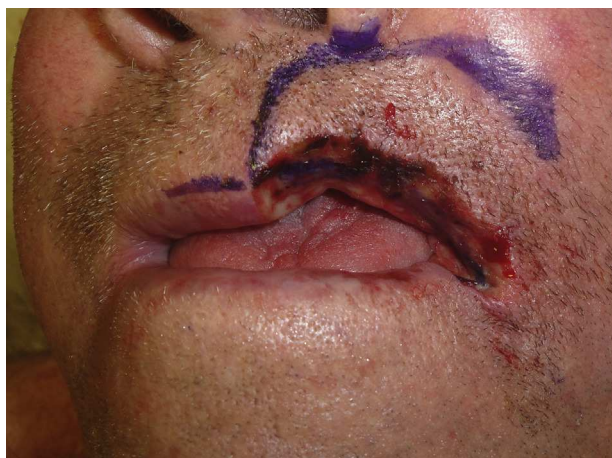

Figure 1 Defect of 3.5 cm × 2 cm after 3 stages of Mohs micrographic surgery to the left upper lip. There is a large defect of the muscle and mucosa and a small skin defect.

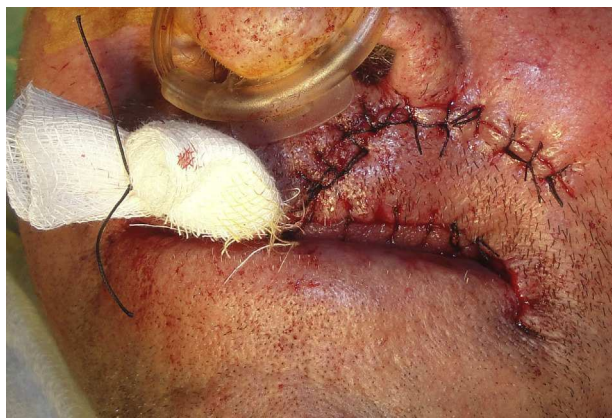

Figure 2 First stage of reconstruction. A cutaneous rotation flap with a lateral pedicle was fashioned from the left half lip, and the vermilion border (Klein's line) was recreated by suturing the lateral tongue flap to the skin flap.

neous lip flap with 4/0 silk (**Fig. 2**), and the tongue was fixed to the upper right half lip with 2/0 silk.

After the operation, the patient was given enteral nutritional support and antibiotic prophylaxis, as well as a short course of corticosteroid therapy to prevent excessive inflammation.

Second Operation

Two weeks after the first operation we divided the bridge between the myomucosal flap and the tongue. The flap was then adjusted and its inferior border was sutured to the posterior border of the lip defect with absorbable 4/0 polyglycolic acid suture. Direct closure of the tongue defect was then performed with 4/0 polyglycolic acid suture.

This 2-flap technique, used after 3 stages of Mohs micrographic surgery, is presented in the accompanying video.

There was no evidence of alterations of taste, speech, or swallowing, and sphincter function of the orbicularis oris muscle was preserved. The cosmetic result was excellent (**Fig. 3**).

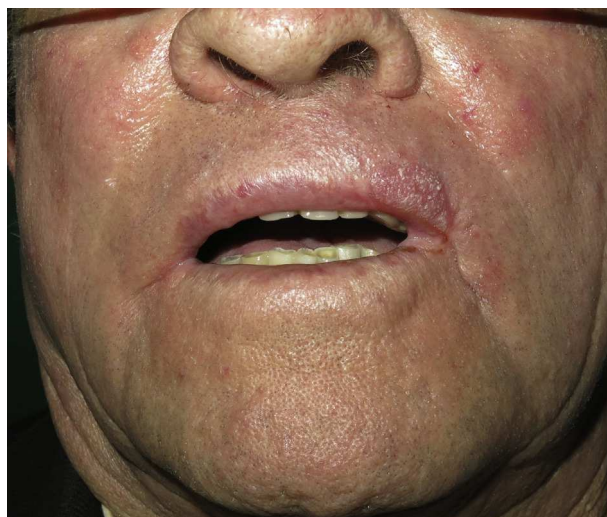


Figure 3 Result 9 months after surgery.

Indications

- Full-thickness defects of the lip with a minor skin defect.

Contraindications

- This technique is unsuitable for patients of advanced age or those with a poor nutritional status, as prolonged nutritional support and a second operation are required.

Complications

- Infection, inflammation and wasting due to the need for a second operation.
- Enteral nutrition is mandatory, and follow-up by an endocrinologist is therefore recommended.

Discussion

The lower lip is considered a single subunit, but the upper lip is divided into 2 lateral subunits and the philtrum. Following the classic principles of facial subunit reconstruction, each subunit should be reconstructed as a whole,² except for small defects in which direct closure is a reasonable option.

In the lip, it is essential to maintain the border between the vermilion and the normal skin (Klein's line), as any alteration would produce a noticeable cosmetic defect. The commissures need to be correctly positioned to avoid microstomia and inadequate mouth opening.³

The appropriate repair procedure for full-thickness defects depends mainly on the lip volume involved. Various techniques, such as Abbe, Estlander, Gilles, and Webster flaps, have been proposed to reconstruct full-thickness defects, but these involve the full height of the lip.⁴ In our opinion, excision of the full height and width of the ipsilateral cutaneous lip or the lower lip to reconstruct the defect of the upper lip in our patient did not seem reasonable.⁵

In our patient, the defect comprised skin, muscle, and mucosa, and all 3 layers must be reconstructed to achieve

a good functional and cosmetic result. We decided to perform a combination of flaps as the defects of the muscle and mucosa were much larger than the skin defect. The cutaneous rotation flap provided skin for the cutaneous part of the lip defect and two of the scars were hidden in natural skin folds.⁶

Tongue flaps have been employed for reconstruction of the vermillion of the upper and lower lips. These provide sufficient muscle to maintain sphincter function of the orbicularis oris muscle, and the mucosa will provide tissue of similar characteristics to the vermillion, giving a good functional result without microstomia. The main disadvantage of tongue flaps is the need for a 2-week period of hospitalization with nutritional support.

The use of a combined tongue flap and cutaneous rotation flap in this case achieved an excellent functional and cosmetic result.

Conflict of Interest

The authors declare no conflict of interest.

Appendix A. Supplementary data

Supplementary data associated with this article can be found, in the online version, at <http://dx.doi.org/10.1016/j.ad.2014.01.009>.

References

1. Samaniego E, Prada C, Rodríguez-Prieto MA. Surgical planes of the head and neck. *Actas Dermosifiliogr*. 2011;102:167–74.
2. Burget GC, Menick FJ. Aesthetic restoration of one-half the upper lip. *Plast Reconstr Surg*. 1986;78:583–93.
3. Malard O, Corre P, Jégoux F, Durand N, Dréno B, Beauvillain C, et al. Surgical repair of labial defect. *Eur Ann Otorhinolaryngol Head Neck Dis*. 2010;127:49–62.
4. Yih WY, Howerton DW. A regional approach to reconstruction of the upper lip. *J Oral Maxillofacial Surg*. 1997;55:383–9.
5. Glenn CJ, Adelson RT, Flowers FP. Split myomucosal advancement flap for reconstruction of a lower lip defect. *Dermatol Surg*. 2012;38:1725–8.
6. Burget GC, Hsiao YC. Nasolabial rotation flaps based on the upper lateral lip subunit for superficial and large defects of the upper lateral lip. *Plast Reconstr Surg*. 2012;130:556–60.