




ACTAS Derma-Sifiliográficas

Full English text available at
www.actasdermo.org



PRACTICAL DERMATOLOGY

Clinical Management of Paradoxical Psoriasiform Reactions During TNF- α Therapy[☆]

R. Navarro,* E. Daudén

Departamento de Dermatología, Hospital Universitario La Princesa, Madrid, Spain

Received 31 December 2012; accepted 25 May 2013

Available online 4 September 2014

KEYWORDS

Psoriasis;
Palmoplantar
pustulosis;
Guttate psoriasis;
Erythrodermia;
Tumor necrosis
factor;
Psoriasiform
reactions;
Adverse effects;
Induced psoriasis

PALABRAS CLAVE

Psoriasis;
Pustulosis
palmoplantar;
Psoriasis guttata;
Eritrodermia;
Factor de necrosis
tumoral;
Reacciones
psoriasiformes;
Efectos adversos;
Psoriasis inducida

Abstract There have been reports of paradoxical induction or worsening of psoriasis during treatment with tumor necrosis factor (TNF) α agents (infliximab, etanercept, adalimumab, and certolizumab). It has been hypothesized that an imbalance between TNF- α and interferon α might have a role in the etiology and pathogenesis of these reactions. Paradoxical psoriasiform reactions can be divided clinically into de novo psoriasis and exacerbation of preexisting psoriasis. The first, which is more common and more extensively described in the literature, occurs in patients without a history of psoriasis who are receiving TNF- α therapy for another inflammatory disorder. The second can occur with or without changes in the morphology of the lesions. In this article, we review the literature on the clinical and histologic features of paradoxical psoriasiform reactions, analyze their clinical course and treatment, and propose a clinical management model for use in routine practice.

© 2012 Elsevier España, S.L.U. and AEDV. All rights reserved.

Reacciones psoriasiformes paradójicas durante el tratamiento con terapia anti-factor de necrosis tumoral. Manejo clínico

Resumen Paradójicamente se han descrito casos de inducción o empeoramiento de una psoriasis durante el tratamiento con todos los agentes anti-factor de necrosis tumoral α (anti-TNF α) (infliximab, etanercept, adalimumab y certolizumab). Se ha postulado que la alteración del equilibrio entre el TNF α y el interferón α estaría implicada en su etiopatogenia. Clínicamente se distinguen varios patrones de reacciones psoriasiformes paradójicas: la psoriasis *de novo* en pacientes que no han presentado anteriormente esta enfermedad y que reciben este tratamiento por otra enfermedad inflamatoria, que es la más frecuente y la mejor descrita, y la exacerbación de una psoriasis preexistente durante la terapia anti-TNF α , que puede presentarse con o sin un cambio de morfología. En este trabajo realizamos una revisión de la literatura

[☆] Please cite this article as: Navarro R, Daudén E. Reacciones psoriasiformes paradójicas durante el tratamiento con terapia anti-factor de necrosis tumoral. Manejo clínico. Actas Dermosifiliogr. 2014;105:752–761.

* Corresponding author.

E-mail address: nat.eraa@hotmail.com (R. Navarro).

en relación con las características clínicas e histológicas de este tipo de reacciones, así como de su evolución y tratamiento, y planteamos un esquema de manejo en la práctica clínica.
© 2012 Elsevier España, S.L.U. y AEDV. Todos los derechos reservados.

Introduction

Psoriasis, a chronic inflammatory disease of unknown etiology, affects approximately 2% to 3% of the population worldwide.¹ It has been speculated that it could be the result of a combination of genetic and environmental factors; a genetic predisposition does exist, but it has not been possible to establish a classic Mendelian pattern of inheritance.

Numerous factors that trigger the onset of psoriasis or aggravate established psoriasis have been described, including infections, stress, and drugs (β -blockers, lithium, . . .).^{1,2}

Several hypotheses and models have been proposed to try to explain the pathogenesis of psoriasis; these have led us to look not only at the skin, but also at the multiple associated comorbid conditions, such as psoriatic arthritis and cardiovascular disease.^{3,4} A unifying hypothesis is the model of the cytokine network, which states that both external stimuli, such as stress, and endogenous ones, such as viruses, neuropeptides, or drug ingestion, can act as triggers that activate a cytokine cascade. These cytokines include tumor necrosis factor (TNF) α , derived from antigen-presenting dendritic cells and keratinocytes, and interferon (IFN) γ produced by activated type 1 helper T cells.¹

Around 90% of individuals with psoriasis have the most common form, the so-called plaque psoriasis or psoriasis vulgaris. In the majority of cases, the disease is mild and can be controlled with topical therapy. However, up to a third of patients develop moderate or severe psoriasis and require systemic therapy, such as phototherapy, acitretin, methotrexate, or ciclosporin.⁵ The toxicity of these drugs and the frequent lack of response to them has led to the appearance over the past 15 years of the so-called biologic therapies, which act at different levels of the inflammatory cascade that gives rise to the plaques of psoriasis.

The use of biologic therapy is increasing worldwide for the treatment not only of psoriasis, but also of other chronic immune-mediated inflammatory diseases, such as rheumatoid arthritis, ankylosing spondylitis, and inflammatory bowel disease. At the present time, the most widely employed drugs are those that inhibit TNF- α (infliximab, etanercept, and adalimumab), though a number of side effects have been reported during their use, including infections, reactivation of latent tuberculosis, demyelinating diseases, and congestive heart failure.⁶⁻⁸

It has been reported that the cutaneous side effects of anti-TNF- α therapy are more prevalent than was previously thought.⁹ These effects include reactions at the site of infusion or injection, skin infections, eczema, and even psoriasis or psoriasiform reactions.¹⁰ Though paradoxical (as these drugs are of demonstrated efficacy in the treatment of psoriasis¹¹⁻¹⁷), case reports and some case series describe patients with exacerbations of their psoriasis or even the

new onset of distinct subtypes of psoriasis during anti-TNF- α therapy.^{9,10,18-73} The most relevant articles and reviews are summarized in [Tables 1 and 2](#).

Moustou et al.¹⁰ published a literature review in which they established the strength of the association between published side effects and the use of 1 or more anti-TNF- α agents, classifying the association as poor, moderate, strong, or definitive. The authors used descriptions of the side effects in meta-analyses, randomized trials, retrospective or prospective studies, case series, and case reports. They analyzed the number of anti-TNF- α agents implicated, the number of distinct inflammatory diseases in which the side effect had occurred during treatment with anti-TNF- α drugs, and the clinical course after withdrawal and reintroduction of the drug. The authors not only described the clinical manifestations of these cutaneous reactions, but they also established that there was a strong relationship between anti-TNF- α therapy and new onset psoriasis or psoriasiform reactions.

Classification

Distinct patterns of paradoxical psoriasiform reactions can be distinguished during treatment with TNF- α -inhibitors ([Fig. 1](#)):

- The induction of new onset psoriasis, which is the appearance of psoriasis lesions in patients who have not previously been diagnosed with this disease and who are receiving anti-TNF- α treatment for another inflammatory disease.
- An exacerbation of pre-existing psoriasis, with or without morphologic differences, during anti-TNF- α therapy.

Pathogenesis of Psoriasiform Reactions

The pathophysiology of the induction or exacerbation of psoriasis during treatment with TNF- α inhibitors is still unknown. A number of theories have been proposed, such as a disruption of the balance between TNF- α and IFN- α , activation of self-reactive T lymphocytes, wrong diagnosis, natural course of the primary disease, or infections that trigger such reactions.^{9,10,25,37} In their article on the pathogenesis of psoriasiform reactions, Collamer et al.²⁵ explained that a disruption of cytokine balance could lead to increased IFN- α production by dendritic cells in genetically predisposed individuals, and that genetic polymorphisms could play a role in this paradoxical reaction secondary to TNF- α blockade.

De Gannes et al.,⁵² in an article published in 2007, demonstrated that patients who developed new onset psoriasis during treatment with anti-TNF- α agents presented

Table 1 Review of the Literature: Articles With at Least 8 Patients who Developed Paradoxical Psoriasiform Reactions During Treatment With Tumor Necrosis Factor α Inhibitors.

Reference	Type of Reaction	Underlying Disease	Total No. of Patients	No. of Patients Receiving Each Anti-TNF- α Agent
Kary et al. (2006) ³⁶	New onset	Rheumatoid arthritis	5	Infliximab, 2; Etanercept, 3; Adalimumab, 4
	Exacerbation with no morphological changes		4	Infliximab, 2; Etanercept, 3; Adalimumab, 1
Goiriz et al. (2006) ³¹	New onset	Rheumatologic Psoriasis	2	Infliximab, 1; Adalimumab, 1; Etanercept, 6
	Morphological changes		6	
De Gannes et al. (2007) ⁵²	New onset	Rheumatologic	15	Infliximab, 5; Etanercept, 6; Adalimumab, 4
Lee et al. (2007) ⁶⁹	New onset	Rheumatologic	6	Infliximab, 3; Etanercept, 2; Adalimumab, 1; Etanercept, 1; Adalimumab, 1
	Exacerbation with no morphological changes		2	
Seneschal et al. (2007) ⁴⁸	New onset	Rheumatologic	13	Infliximab, 7; Etanercept, 3; Adalimumab, 3
Harrison et al. (2009) ⁵⁴	New onset	Rheumatoid arthritis	25	Infliximab, 6; Etanercept, 6; Adalimumab, 13
Cullen et al. (2011) ²⁷	New onset	Inflammatory bowel disease	30	Infliximab, 21; Adalimumab, 7; Certolizumab, 2
Guerra et al. (2012) ³³	New onset	Inflammatory bowel disease	21	Infliximab, 14; Adalimumab, 7

Abbreviation: TNF, tumor necrosis factor.

Table 2 Most Relevant Revisions Published in the Literature.

Reference	Type of Reaction	Underlying Disease	Total No. of Patients	Percentage of Cases With the Different Anti-TNF- α Agents
Collamer et al. (2008) ²⁶	New onset psoriasis and exacerbations with/without morphological changes	Rheumatologic, gastrointestinal, and psoriatic	104	Infliximab, 53; Etanercept, 29; Adalimumab, 18
Wollina et al. (2008) ⁹	New onset psoriasis and exacerbations with/without morphological changes	Rheumatologic, gastrointestinal, and psoriatic	120	Infliximab, 52.5; Etanercept, 30.8; Adalimumab, 21.7
Ko et al. (2009) ³⁷	New onset psoriasis and exacerbations with/without morphological changes	Rheumatologic, gastrointestinal, and psoriatic	127	Infliximab, 55.1; Etanercept, 27.6; Adalimumab, 17.3
Collamer et al. (2010) ²⁵	New onset psoriasis and exacerbations with/without morphological changes	Rheumatologic, gastrointestinal, and psoriatic	207	Infliximab, 59; Etanercept, 19; Adalimumab, 22
Cullen et al. (2011) ²⁷	New onset psoriasis	Gastrointestinal	120	Infliximab, 79; Adalimumab, 17; Certolizumab, 4
Denadai et al. (2012) ²⁸	New onset psoriasis	Gastrointestinal	222	Infliximab, 69.4; Adalimumab, 22.5; Certolizumab, 2.7; Not specified, 5.4

Abbreviation: TNF, tumor necrosis factor.

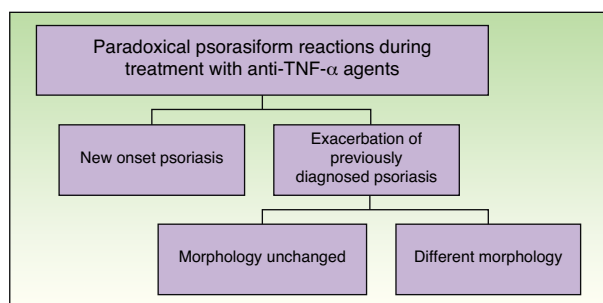


Figure 1 Classification of paradoxical psoriasiform reactions.

elevated expression of antimyxovirus-resistance protein A (MxA), an adenosine triphosphatase that is selectively induced in response to type 1 IFN and could be used as a surrogate marker of lesional type 1 IFN activity. In that study, staining for MxA in biopsies from patients receiving treatment with anti-TNF was more intense than in the biopsies from patients with psoriasis vulgaris not associated with anti-TNF- α therapy. Such an increase would favor the formation of psoriasis lesions in predisposed individuals. Subsequently, Seneschal et al.⁴⁸ described 13 patients who developed distinct subtypes of psoriasis; biopsies from those patients revealed increased production of MxA protein compared with biopsies from healthy skin or from noninduced psoriasis lesions. Those authors concluded that increased IFN- α levels associated with cytokine imbalance (both situations caused by TNF- α inhibition) could play an important role in the appearance of this type of reaction, which they considered to be a drug reaction rather than true psoriasis.

However, another study found no differences between induced and noninduced psoriasis on immunohistochemical analysis with staining for the mRNA of IFN and TNF- α and for vascular endothelial growth factor.⁵³

Some authors believe that there must be a genetic predisposition, as the majority of patients receiving anti-TNF- α therapy for a wide range of diseases do not develop psoriasis. Some environmental factor may also be exerting an effect, as the latency between the initiation of treatment and the appearance of psoriasis is very variable (from days to years).^{25,27,37}

This wide variability makes it difficult to establish a causal relationship in some cases. It is therefore important to exclude any other factor that could trigger the appearance of psoriasis, such as infection, trauma, stress, or new drugs.⁴⁴

According to some authors, paradoxical psoriasiform reactions are the result of a class effect, as cases have been reported with all 3 classic TNF- α inhibitors (infliximab, etanercept, and adalimumab), in frequencies proportional to the prevalence of their use.³⁷ More recently, the phenomenon has been described in patients treated with certolizumab, a newer anti-TNF- α agent. In the literature, we have found a review article describing 6 cases related to this drug in patients with inflammatory bowel disease, in addition to another case from our own records.²⁷ Recurrence after the administration of a distinct anti-TNF- α drug supports the class effect theory.^{25,27,33,36,37,55}

Reports have also been published of cases of new onset psoriasis or exacerbations during treatment with psoriasis

drugs other than the TNF- α inhibitors, including drugs such as efalizumab, ciclosporin, and anthralin, as well as after phototherapy or glucocorticoid withdrawal.⁵⁵ Furthermore, other biologic agents have been implicated, such as abatacept in a patient who developed guttate psoriasis during treatment with etanercept and, 2 years later, a further episode with the same morphology during treatment with abatacept.⁷⁰ For Rallis et al.⁴⁴ this suggests a gap in our understanding of the pathophysiology of psoriasis and of the exact mechanism by which some of these drugs act.⁴⁴

New Onset Psoriasis

The large majority of published cases refer to new onset psoriasis, particularly in patients with rheumatologic diseases. Based on published studies, it has been established that the prevalence of psoriasis during anti-TNF- α therapy is between 0.6% and 5.3%, depending on differences between the populations studied and treated.^{27,54} In a recent article on psoriasis induced during treatment with anti-TNF- α drugs for inflammatory bowel disease, the reported prevalence was 1.62%.³³

Data coming from the larger series and from literature reviews are not particularly homogeneous. This, and the fact that not all cases will have been published, could lead to biased conclusions. In a recent review article that included 207 cases (after excluding patients with any known trigger), it was reported that 85% of patients had developed new onset psoriasis.²⁵

There is a female predominance (2 women to 1 man), due to cases associated with rheumatoid arthritis and inflammatory bowel disease.^{25,37} Series of patients with rheumatoid arthritis show the greatest difference, up to 5.3 women to 1 man.⁵⁴ When all cases are included, the mean age at onset is 44.9 years (range, 13-78 years)²⁵; however, the mean age among patients with gastrointestinal disease is lower (30 years).²⁷

Looking at all cases that were fully reviewed, the drug most commonly implicated was infliximab, accounting for 55.1% to 59% cases.^{25,37} In their review of the literature, Ko et al.³⁷ identified 127 cases reported up to September 2007. Those authors stated that the second most common drug was etanercept (27.6%) and, finally, adalimumab (17.3%). However, in a more recent series by Collamer et al.,²⁵ 22% of all cases were on treatment with adalimumab and 17% with etanercept.

Cullen et al.²⁷ performed a review of 120 cases, including 30 cases of their own, with the additional inclusion criterion of a history of inflammatory bowel disease. Their results indicated that 79% had received infliximab, 17% adalimumab, and 4% the new drug, certolizumab; it must be taken into account that etanercept is not approved for use in inflammatory bowel disease.

Those percentages were proportional to the use of each one of the drugs. In contrast, in a series of patients from the British Society for Rheumatology Biologics Register, with a description of 25 cases of new onset psoriasis in a cohort of 9826 patients with AR, 13 were on treatment with adalimumab.⁵⁴ That group of 25 patients was compared with another group formed of patients receiving treatment with disease-modifying antirheumatic drugs; none of the patients

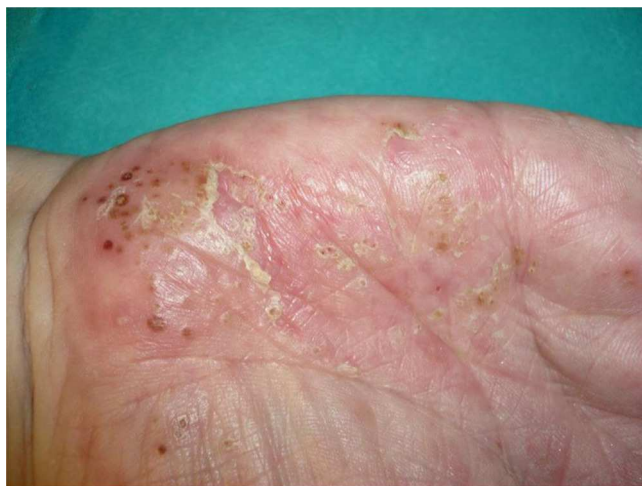

Figure 2 Desquamating erythematous plaques with pustules on their surface. These developed on the palms of a patient on treatment with adalimumab for rheumatoid arthritis.

in the latter group developed psoriasis after a follow-up of 2.81 years.

The latency is very variable, from days to 80 months, with a mean of 10.5 months. In the review by Ko et al.,³⁷ the latency was shorter in patients treated with etanercept, although 42.9% were exacerbations of previously known psoriasis rather than new onset psoriasis. Other authors, such as Chen et al.,²⁴ who published a review of cases arising with etanercept, have also reported a shorter latency with this drug. In the 25 patients included in the review by those authors, the mean latency was 3.5 months after the initiation of treatment.

More than half of published cases have occurred in patients with rheumatologic diseases, particularly rheumatoid arthritis, which accounts for 42.5% to 50.4% of cases, depending on the study.^{25,37}

Overall, the cases reported have been of any type of psoriasis and at any site: vulgaris, guttate, inverse, or generalized or palmoplantar pustulosis (Fig. 2); the latter subtype was the most common form in the larger series and reviews.^{9,25,37} Adalimumab has been reported to be the drug most frequently implicated in palmoplantar pustulosis, and more than half of the paradoxical reactions described with this drug are of this subtype. However, in the article by Ko et al.,³⁷ patients treated with etanercept were more likely to develop plaque psoriasis, though this finding is probably not evaluable because, as commented above, the events in that study were exacerbations in almost half of cases.

The fact that the incidence of palmoplantar pustulosis in cases of psoriasis induced by TNF- α inhibitors is twice the incidence in the general population with psoriasis could suggest greater TNF- α expression in the eccrine glands of susceptible individuals.⁶⁷

In a review that only included patients with inflammatory bowel disease, the authors stated that these patients most commonly presented involvement of the palms and soles (43%) and of the scalp (42%).²⁷ However, in a recent series from Spain including 21 patients with inflammatory bowel disease, the most common form was plaque psoriasis, predominantly affecting the limbs (62%), though the trunk and the scalp were also affected.³³

Between 36% and 100% of patients, depending on the series, were receiving other psoriasis treatments concomitantly, including methotrexate and azathioprine, which have thus not been shown to be capable of preventing this type of reaction.^{25,27,33}

The treatment most frequently used for this side effect has been topical therapy with corticosteroids, employed in almost 40% of cases according to the review by Ko et al.,³⁷ with no other changes in treatment. Resolution of the flare of psoriasis was reported in a quarter of patients. Topical therapy associated with withdrawal of the implicated anti-TNF- α agent was employed in a further 50%. The use of systemic psoriasis treatments, with or without interruption of the implicated agent, was more successful than the topical treatments (44% achieved resolution of the lesions). Only 15% of the patients who were changed to an alternative anti-TNF- α agent achieved a satisfactory response, while this figure rose to 64% among those who received treatments with a different mechanism of action. Those authors therefore considered that the essential action was to discontinue the anti-TNF- α agent. In mild or moderate cases, they recommended topical treatments or phototherapy in monotherapy or in combination with acitretin, depending on the response, whereas ciclosporin and methotrexate could be of benefit in acute or serious cases. In those cases in which the skin lesions did not resolve, no differences were found with regard to severity of the episode or type or distribution of the psoriasis compared with patients in whom the lesions resolved.

In the review by Cullen et al.²⁷ of patients with inflammatory bowel disease, approximately 50% responded to topical therapy, as also found in the study by Collamer et al.,²⁵ in which the majority of patients responded to conservative treatment, without withdrawal of the implicated drug. In some patients with rheumatoid arthritis who developed psoriasis, whether of new onset or an exacerbation, interruption or dose reduction of the implicated drug caused the skin lesions to improve or disappear.³⁶

The more recent incorporation of other drugs with distinct mechanisms of action, such as ustekinumab, an anti-p40 agent, broadens the spectrum of treatments for this type of reaction. Spanish authors described a patient with Crohn disease who developed psoriasis with 2 anti-TNF- α drugs, infliximab and adalimumab. Ustekinumab, at a dose of 90 mg every 8 weeks, achieved remission of the skin lesions, while control of the gastrointestinal disease was maintained with azathioprine and mesalazine.⁴⁷ In contrast, there has also been a case report in which, despite this treatment, an episode of palmoplantar pustulosis did not resolve or even got worse.⁴⁶ More recently, Puig et al.⁴³ reported their experience in another patient with psoriatic arthritis and performed a review of cases treated with ustekinumab. Those authors concluded that this drug could be a good therapeutic option in patients who develop paradoxical reactions with TNF- α inhibitors.

Exacerbation of Previous Psoriasis

Although exacerbations of previous psoriasis, with or without changes of morphology, have been more common in the daily clinical practice of the authors, exacerbations only

accounted for 15% of cases included in the review of 207 patients by Collamer et al.²⁵ It is thus difficult to establish the characteristics of this type of reaction. Comparison of these patients with those with new onset psoriasis shows no significant difference according to sex; the agent most frequently implicated has been etanercept (62%), followed by the monoclonal antibodies (infliximab [23%] and adalimumab [15%]). Further studies are needed to clarify whether this difference is significant or arises because etanercept is the most widely used agent in dermatology. Collamer et al. considered that patients with psoriasis and psoriatic arthritis tended to develop lesions that differed from their previous psoriasis, most commonly presenting as guttate psoriasis. In 38% of such patients, the lesions resolved after discontinuation of the implicated agent and complete or partial remission was achieved in 53% while maintaining the implicated agent and adding other psoriasis treatments. The data on recurrence with other anti-TNF- α drugs are not evaluable jointly due to the heterogeneity of the patients and the short follow-up in some cases, and we will therefore discuss each subtype separately.

Exacerbation of Previous Psoriasis With No Change in Morphology

In 2010, Mourao et al.⁵⁵ published a review of 5 previously reported cases and added a further 3 cases to describe the exacerbation of previous psoriasis during treatment with an anti-TNF- α agent. In 1 of the patients, etanercept lost efficacy after 41 months and the skin disease subsequently worsened during treatment with adalimumab and infliximab. The latency period of these exacerbations has been very variable, with reports of 2 weeks to 32 months after the start of exposure. There were no clear triggering factors.

The possibility of reappearance of the skin lesions has also been described in patients with latent psoriasis who receive treatment with anti-TNF- α therapy to control rheumatoid arthritis. Kary et al.³⁶ described 3 patients, of whom 2 developed an episode of pustular psoriasis and the other of plaque psoriasis. In the opinion of those authors, the clinical improvement after withdrawal or dose reduction of the implicated drug supports the relationship with the drug.

In some patients with psoriatic arthritis, the skin lesions have deteriorated while the arthritis has responded adequately to treatment.⁵⁵

Exacerbation of Previous Psoriasis With a Change in Morphology

Few data are available in the literature on exacerbations in which the morphology of the psoriasis changes during treatment with biologic agents. Our experience suggests that this type of reaction is more common than the literature to date would indicate. In 2007, a paper published by our department described 8 cases of new onset or exacerbation of psoriasis.³¹ Six of those patients developed guttate psoriasis between 15 days and 18 months after starting treatment with etanercept for severe plaque psoriasis. None of the patients presented other triggers. Substitution of the biologic agent by ciclosporin was necessary to control the

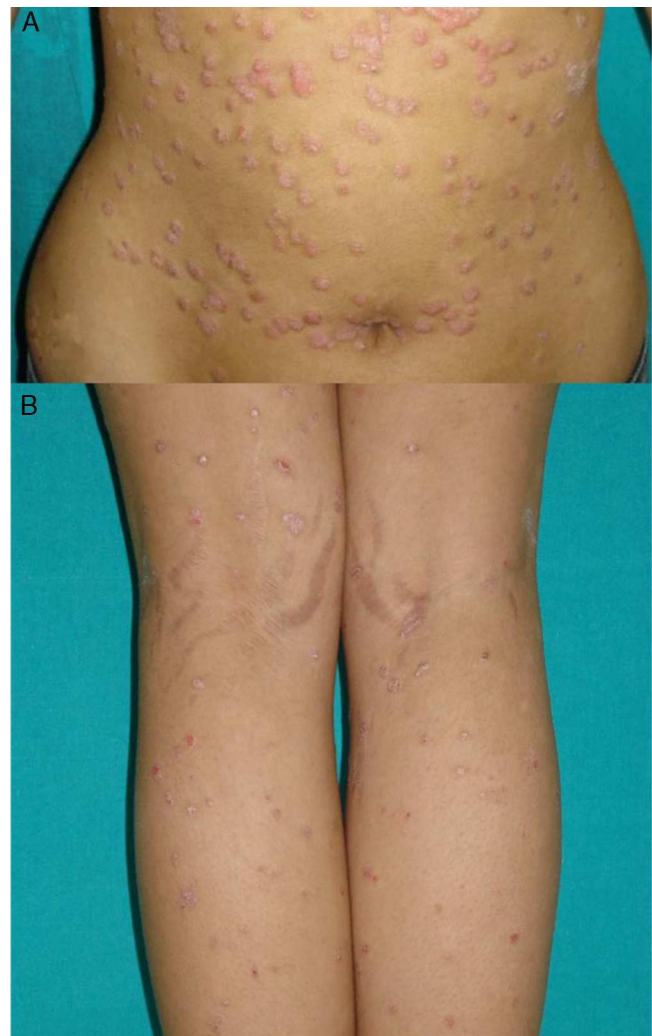

Figure 3 Patient with a history of plaque psoriasis who presented a sudden outbreak of small desquamating erythematous plaques with a drop-like appearance: A, On the abdomen. B, On the posterior aspect of the lower limbs.

psoriasis in 1 of the patients due to a lack of response to topical corticosteroids. This type of paradoxical reaction is characterized by the sudden onset of small drop-like lesions predominantly in areas not previously affected by psoriasis, while the original plaques remain in remission (Fig. 3). These outbreaks should not be confused with a flare or exacerbation of the psoriasis of a different origin, not induced by the biologic agent; in these cases the new lesions are similar to the previous psoriasis lesions and appear in the same areas. Nor should they be confused with a flare-up of psoriasis, which is typically defined as a deterioration of the psoriasis of more than 125% compared to the baseline situation, or a change in morphology induced by the biological agent, but after its interruption. The changes in morphology to which we are referring in this section occur without discontinuation of the drug.

Mössner et al.³⁹ published a series of 5 patients (3 men and 2 women) who developed palmoplantar pustulosis during or after treatment with infliximab for plaque psoriasis. In 1 of their patients, the palmoplantar changes were

associated with widespread pustular lesions. In 3 of the cases, there was a simultaneous exacerbation of the plaques. None of them had previously presented generalized or palmoplantar pustular psoriasis. The latency period varied between 3 and 40 weeks. Risk factors included infection in 1 patient and abrupt withdrawal of the infliximab in another. Lesion control by the addition of topical corticosteroids without the withdrawal of infliximab was only achieved in 1 patient.

Spanish authors have reported the case of a patient on treatment with etanercept for plaque psoriasis. The patient developed pustular psoriasis 24 hours after undergoing the tuberculin test, which could have been the trigger.⁷³

An erythrodermic form of psoriasis appearing after starting the drug, with a shorter latency period than other types of psoriasiform reaction, has occasionally been reported, and we have also observed this in our clinical practice. Santos-Juanes et al.⁵⁷ described 2 patients with plaque psoriasis who had previously received numerous psoriasis treatments with suboptimal responses. Those patients developed erythroderma during treatment with etanercept, but were subsequently stable during treatment with infliximab and adalimumab. However, both patients showed an improvement of more than 80% in the PASI (Psoriasis Area Severity Index) after 4 weeks of treatment with ustekinumab.⁵⁷

Histopathologic Characteristics

Histological confirmation was only available for 39.4% of the 127 cases reviewed by Ko et al.³⁷ Some authors consider that these reactions present a histology compatible with palmoplantar pustulosis or psoriasis, indistinguishable from cases unrelated to anti-TNF- α therapy.³⁶

However, Seneschal et al.,⁴⁸ who described in detail the biopsies of their patients with psoriasiform reactions during anti-TNF- α therapy, did find some differences. Skin biopsy

had been performed in 11 of their 13 cases. Clinically the lesions were typical small areas of plaque psoriasis, associated with palmoplantar pustulosis or keratoderma in 3 of them. In 5 patients, the authors observed a psoriasiform pattern with parakeratosis, hyperkeratosis, and acanthosis. Three of those 5 cases also presented a lichenoid infiltrate, and another 3 biopsies also showed a focal lichenoid pattern. Keratinocyte necrosis was detected in 3 patients. Seven of the samples had signs of spongiosis with epidermal edema, and a unilocular subcorneal pustule was observed in another case.

Recently, Laga et al.⁶⁸ evaluated the histological spectrum of psoriasiform reactions associated with anti-TNF- α therapy in 16 biopsies from 9 patients. Those authors reported different histologic patterns, including lichen planus-type dermatitis, sterile pustular folliculitis, and a pattern similar to psoriasis. They concluded that correlation with the clinical findings was crucial to be able to make a diagnosis in this type of reaction. In our opinion, reactions that do not correspond clinically or histologically to palmoplantar pustulosis or psoriasis should not be included in the group of psoriasiform reactions induced by or associated with anti-TNF- α drugs.

In favor of this opinion, other authors consider that the histologic findings of psoriasiform reactions are identical or very similar to the patient's psoriasis prior to anti-TNF- α therapy and differ from pustular drug reactions. They include epidermal hyperplasia, parakeratosis, epidermal lymphocyte infiltrates, dilated capillaries, and intraepidermal pustulosis.⁵³

Initial Management

The steps detailed below and in Tables 3 and 4 should be followed for the management of any patient who develops a paradoxical psoriasiform reaction during treatment with any anti-TNF- α agent:

Table 3 Initial Management of Patients With New Onset Psoriasis During Treatment With Tumor Necrosis Factor α Inhibitors.

Medical Background	History of the Underlying Disease	Psoriasis	Additional Tests
Medical and surgical diseases Usual medication	Clinical course Previous treatments	Disease duration Clinical forms Personal/family background Exclude triggers	Routine blood tests Skin biopsy for confirmation

Table 4 Initial Management of Patients With an Exacerbation of Previously Diagnosed Psoriasis During Treatment With Tumor Necrosis Factor α Inhibitors.

Medical Background	Previous Form of Psoriasis	Episode of Psoriasis During anti-TNF- α Treatment	Additional Tests
Medical and surgical diseases Usual medication	Clinical course Clinical forms Previous treatments	Disease duration Clinical forms Exclude triggers	Routine blood tests, ASLO, and pharyngeal exudate Skin biopsy for confirmation

Abbreviations: ASLO, antistreptolysin O antibody; TNF, tumor necrosis factor.

Table 5 General Treatment of Paradoxical Psoriasiform Reactions.**Treatment Sequence**

1. Add topical therapy (high-strength corticosteroids, vitamin D analogs, or combinations of the two)
2. Substitute the implicated drug (preferably by one with a different mechanism of action)
3. Combined therapy with another systemic treatment:
In mild or moderate cases: phototherapy and/or acitretin
In severe cases: ciclosporin or methotrexate

- A detailed medical history should be obtained, including the following information:
 - Sociodemographic details.
 - Personal and family history of psoriasis.
 - Personal medical and surgical history, including a drug history, paying particular attention to the duration of drug treatments.
 - Details of the duration of the underlying disease that required the biologic therapy and concomitant or previous therapies administered.
 - Details of the duration of the current biologic treatment and the dose at the time of onset of the reaction.
 - Clinical course of the episode of psoriasis, the type or types of lesion, and history of similar rashes.
 - Information sufficient to exclude possible triggering factors, such as infection, stress, or the initiation of treatment with new drugs.

The management of these patients is not well established. The following recommendations are based on our experience and on published reviews:

- Laboratory tests including complete blood count, liver and kidney function tests, antistreptolysin O antibody, and pharyngeal exudate at the start of the episode.
- Except in clinically characteristic cases, 1 or several biopsies of the skin lesions. This is useful for diagnostic confirmation because, as some authors have stated, not all reactions described as psoriasiform are true psoriasis.

The general treatment of paradoxical psoriasiform reactions is summarized in [Table 5](#). However, based on our experience and on our review of the literature, we consider it useful to detail the treatment of each one of the subtypes:

- In patients with new onset psoriasis during treatment with TNF- α inhibitors, the initial use of topical therapy with high-strength corticosteroids, vitamin D analogs, or combinations of the 2 is recommended. If this does not control the episode, 2 situations may arise. When it is necessary to continue the anti-TNF- α drug responsible for inducing the psoriasis because it adequately controls the patient's underlying nondermatologic disease without serious side effects, partial control of the skin lesions with topical therapy may be acceptable, with the possible addition of other therapies (phototherapy or systemic therapy). If it is not essential to continue the anti-TNF- α agent, it is best to substitute the implicated drug. Because of the

possible class effect of the anti-TNF- α drugs, we recommend that the new therapy should act via a pathway that does not inhibit TNF- α in order to avoid a deterioration or recurrence of the skin disease.

- In case of erythrodermic psoriasis, the first step in all patients should be to substitute the drug by another with a rapid response, such as ciclosporin or ustekinumab, to treat the episode.
- In patients with a change in the morphology of the psoriasis, which is not serious in the majority of cases, the most widely used initial option is to continue using the same drug at the same dose and to prescribe topical therapy. If this is insufficient to control the episode, we recommend substitution of the first agent by another drug, preferably one with a different mechanism of action, as in cases of new onset psoriasis. Though possible, the option to add another systemic drug is, in our experience, less effective. This delays the substitution, which will be necessary in the large majority of patients in the end. However, therapeutic modalities such as phototherapy in monotherapy or in combination with acitretin in mild or moderate cases, or drugs such as ciclosporin or methotrexate in more serious cases, have been shown to be useful in some patients, as mentioned above in the text.

Ethical Disclosures

Protection of human and animal subjects. The authors declare that no experiments were performed on humans or animals for this investigation.

Confidentiality of data. The authors declare that they followed their hospital's regulations regarding the publication of patient information and that written informed consent for voluntary participation was obtained for all patients.

Right to privacy and informed consent. The authors declare that no private patient data are disclosed in this article.

Conflicts of Interest

Dr E. Daudén undertakes or has undertaken the following activities: member of Advisory Boards, consultant, reception of grants, research support, participation in clinical trials and fees for lectures with the following pharmaceutical companies: Abbott, Astellas, Biogen, Centocor Ortho Biotech Inc, Galderma, Glaxo, Janssen-Cilag, Leo Pharma, MSD, Pfizer, Novartis, Stiefel, Wyeth Pharmaceuticals, 3M and Celgene.

Dr. R. Navarro declares that she has no conflicts of interest.

References

1. Nestle FO, Kaplan DH, Barker J. Psoriasis. *N Engl J Med*. 2009;361:496–509.
2. Fry L, Baker BS. Triggering psoriasis: The role of infections and medications. *Clin Dermatol*. 2007;25:606–15.
3. Dauden E, Castaneda S, Suarez C, Garcia-Campayo J, Blasco AJ, Aguilar MD, et al., Working Group on Psoriasis-associated

- comorbidities. Integrated approach to comorbidity in patients with psoriasis. *Actas Dermosifiliogr.* 2012;103:1–64.
4. Dauden E, Castaneda S, Suarez C, Garcia-Campayo J, Blasco AJ, Aguilar MD, et al. Clinical practice guideline for an integrated approach to comorbidity in patients with psoriasis. *J Eur Acad Dermatol Venereol.* 2012;103:1–64.
 5. Johnson-Huang LM, Lowes MA, Krueger JG. Putting together the psoriasis puzzle: An update on developing targeted therapies. *Dis Model Mech.* 2012;5:423–33.
 6. Leombruno JP, Einarson TR, Keystone EC. The safety of anti-tumour necrosis factor treatments in rheumatoid arthritis: Meta and exposure-adjusted pooled analyses of serious adverse events. *Ann Rheum Dis.* 2009;68:1136–45.
 7. Ribera M, Leal L, Luelmo J. Etanercept and infections. *Actas Dermosifiliogr.* 2010;101:70–6.
 8. Rongioletti F, Burlando M, Parodi A. Adverse effects of biological agents in the treatment of psoriasis. *Am J Clin Dermatol.* 2010;11:35–7.
 9. Wollina U, Hansel G, Koch A, Schonlebe J, Kostler E, Haroske G. Tumor necrosis factor-alpha inhibitor-induced psoriasis or psoriasiform exanthemata: First 120 cases from the literature including a series of six new patients. *Am J Clin Dermatol.* 2008;9:1–14.
 10. Moustou AE, Matekovits A, Dessinioti C, Antoniou C, Sfikakis PP, Stratigos AJ. Cutaneous side effects of anti-tumor necrosis factor biologic therapy: A clinical review. *J Am Acad Dermatol.* 2009;61:486–504.
 11. Pariser DM, Leonardi CL, Gordon K, Gottlieb AB, Tying S, Papp KA, et al. Integrated safety analysis: Short- and long-term safety profiles of etanercept in patients with psoriasis. *J Am Acad Dermatol.* 2012;67:245–56.
 12. Menter A, Tying SK, Gordon K, Kimball AB, Leonardi CL, Langley RG, et al. Adalimumab therapy for moderate to severe psoriasis: A randomized, controlled phase III trial. *J Am Acad Dermatol.* 2008;58:106–15.
 13. Gordon KB, Langley RG, Leonardi C, Toth D, Menter MA, Kang S, et al. Clinical response to adalimumab treatment in patients with moderate to severe psoriasis: Double-blind, randomized controlled trial and open-label extension study. *J Am Acad Dermatol.* 2006;55:598–606.
 14. Gordon KB, Gottlieb AB, Leonardi CL, Elewski BE, Wang A, Jahreis A, et al. Clinical response in psoriasis patients discontinued from and then reinitiated on etanercept therapy. *J Dermatolog Treat.* 2006;17:9–17.
 15. Barker J, Hoffmann M, Wozel G, Ortonne JP, Zheng H, van Hoogstraten H, et al. Efficacy and safety of infliximab vs methotrexate in patients with moderate-to-severe plaque psoriasis: Results of an open-label, active-controlled, randomized trial (RESTORE1). *Br J Dermatol.* 2011;165:1109–17.
 16. Reich K, Burden AD, Eaton JN, Hawkins NS. Efficacy of biologics in the treatment of moderate to severe psoriasis: A network meta-analysis of randomized controlled trials. *Br J Dermatol.* 2012;166:179–88.
 17. Reich K, Nestle FO, Papp K, Ortonne JP, Evans R, Guzzo C, et al. Infliximab induction and maintenance therapy for moderate-to-severe psoriasis: A phase III, multicentre, double-blind trial. *Lancet.* 2005;366:1367–74.
 18. Aslanidis S, Pырpasopoulou A, Douma S, Triantafyllou A. Tumor necrosis factor- α antagonist-induced psoriasis: Yet another paradox in medicine. *Clin Rheumatol.* 2008;27:377–80.
 19. Bhutani T, Koo J. Paradoxical worsening of psoriasis when switching from etanercept to adalimumab: A case series. *J Dermatolog Treat.* 2011;22:75–8.
 20. Boms S, Sehr T, Jappe U, Enk A. First manifestation of psoriasis vulgaris in tumor necrosis factor receptor-associated periodic syndrome during treatment with etanercept. *Hautarzt.* 2008;59:653–5.
 21. Bruzzese V. Diffused suberitrodermic psoriasis induced by infliximab. *Reumatismo.* 2007;59:328–31.
 22. Bruzzese V, Pepe J. Efficacy of cyclosporine in the treatment of a case of infliximab-induced erythrodermic psoriasis. *Int J Immunopathol Pharmacol.* 2009;22:235–8.
 23. Cavailles A, Ingen-Housz-Oro S, Djennane S, Rafea M, Fiszenson-Albala F, Weber N, et al. Occurrence of psoriasis in a patient presenting Shulman fasciitis treated with infliximab. *Ann Dermatol Venereol.* 2007;134:363–7.
 24. Chen LA, Su LH, Chang YJ, Hsu YL, Tsai TH. New-onset psoriasis associated with etanercept therapy. *J Dermatol.* 2010;37:378–80.
 25. Collamer AN, Batafarano DF. Psoriatic skin lesions induced by tumor necrosis factor antagonist therapy: Clinical features and possible immunopathogenesis. *Semin Arthritis Rheum.* 2010;40:233–40.
 26. Collamer AN, Guerrero KT, Henning JS, Batafarano DF. Psoriatic skin lesions induced by tumor necrosis factor antagonist therapy: A literature review and potential mechanisms of action. *Arthritis Rheum.* 2008;59:996–1001.
 27. Cullen G, Kroshinsky D, Cheifetz AS, Korzenik JR. Psoriasis associated with anti-tumour necrosis factor therapy in inflammatory bowel disease: A new series and a review of 120 cases from the literature. *Aliment Pharmacol Ther.* 2011;34:1318–27.
 28. Denadai R, Teixeira FV, Steinwurz F, Romiti R, Saad-Hossne R. Induction or exacerbation of psoriatic lesions during anti-TNF- α therapy for inflammatory bowel disease: A systematic literature review based on 222 cases. *J Crohns Colitis.* 2013;7:517–24.
 29. Fernandes IC, Torres T, Sanches M, Velho G, Lago P, Selores M. Psoriasis induced by infliximab. *Acta Med Port.* 2011;24:709–12.
 30. Fouache D, Goeb V, Massy-Guillemant N, Avenel G, Bacquet-Deschryver H, Kozyreff-Meurice M, et al. Paradoxical adverse events of anti-tumour necrosis factor therapy for spondyloarthropathies: A retrospective study. *Rheumatology (Oxford).* 2009;48:761–4.
 31. Goiriz R, Dauden E, Perez-Gala S, Guhl G, Garcia-Diez A. Flare and change of psoriasis morphology during the course of treatment with tumour necrosis factor blockers. *Clin Exp Dermatol.* 2007;32:176–9.
 32. Grinblat B, Scheinberg M. The enigmatic development of psoriasis and psoriasiform lesions during anti-TNF therapy: A review. *Semin Arthritis Rheum.* 2008;37:251–5.
 33. Guerra I, Algaba A, Perez-Calle JL, Chaparro M, Marin-Jimenez I, Garcia-Castellanos R, et al. Induction of psoriasis with anti-TNF agents in patients with inflammatory bowel disease: A report of 21 cases. *J Crohns Colitis.* 2012;6:518–23.
 34. Iborra M, Beltran B, Bastida G, Aguas M, Nos P. Infliximab and adalimumab-induced psoriasis in Crohn's disease: A paradoxical side effect. *J Crohns Colitis.* 2011;5:157–61.
 35. Joyau C, Veyrac G, Dixneuf V, Jolliet P. Anti-tumour necrosis factor alpha therapy and increased risk of de novo psoriasis: Is it really a paradoxical side effect? *Clin Exp Rheumatol.* 2012;30:700–6.
 36. Kary S, Worm M, Audring H, Huscher D, Renelt M, Sorensen H, et al. New onset or exacerbation of psoriatic skin lesions in patients with definite rheumatoid arthritis receiving tumour necrosis factor alpha antagonists. *Ann Rheum Dis.* 2006;65:405–7.
 37. Ko JM, Gottlieb AB, Kerbleski JF. Induction and exacerbation of psoriasis with TNF-blockade therapy: A review and analysis of 127 cases. *J Dermatolog Treat.* 2009;20:100–8.
 38. Manni E, Barachini P. Psoriasis induced by infliximab in a patient suffering from Crohn's disease. *Int J Immunopathol Pharmacol.* 2009;22:841–4.
 39. Mossner R, Thaci D, Mohr J, Patzold S, Bertsch HP, Kruger U, et al. Manifestation of palmoplantar pustulosis during or after

- infliximab therapy for plaque-type psoriasis: Report on five cases. *Arch Dermatol Res.* 2008;300:101–5.
40. Park BC, Lim HJ, Kim BS, Lee WJ, Kim Do W, Lee SJ. Repeated paradoxical aggravation of preexisting psoriasis during infliximab treatment for Crohn's disease. *Ann Dermatol.* 2009;21:60–2.
 41. Passarini B, Infusino SD, Barbieri E, Varotti E, Gionchetti P, Rizzello F, et al. Cutaneous manifestations in inflammatory bowel diseases: eight cases of psoriasis induced by anti-tumor-necrosis-factor antibody therapy. *Dermatology.* 2007;215:295–300.
 42. Perez-Alvarez R, Perez-de-Lis M, Ramos-Casals M. Biologics-induced autoimmune diseases. *Curr Opin Rheumatol.* 2012.
 43. Puig L, Morales-Munera CE, Lopez-Ferrer A, Geli C. Ustekinumab treatment of TNF antagonist-induced paradoxical psoriasis flare in a patient with psoriatic arthritis: Case report and review. *Dermatology.* 2012;225:14–7.
 44. Rallis E, Korfitis K, Stavropoulou E, Papaconstantis M. Onset of palmoplantar pustular psoriasis while on adalimumab for psoriatic arthritis: A «class effect» of TNF-alpha antagonists or simply an anti-psoriatic treatment adverse reaction? *J Dermatolog Treat.* 2010;21:3–5.
 45. Richetta A, Mattozzi C, Carlomagno V, Maiani E, Carboni V, Giancristoforo S, et al. A case of infliximab-induced psoriasis. *Dermatol Online J.* 2008;14:9.
 46. Safa G, Martin A, Darrieux L. Exacerbation of infliximab-induced palmoplantar psoriasis under ustekinumab therapy in a patient with ankylosing spondylitis. *J Clin Rheumatol.* 2011;17:385–6.
 47. Sanso Sureda A, Rocamora Duran V, Sapina Camaro A, Royo Escosa V, Bosque Lopez MJ. Ustekinumab in a patient with Crohn's disease and anti-TNF-alpha-induced psoriasis. *Gastroenterol Hepatol.* 2011;34:546–50.
 48. Seneschal J, Milpied B, Vergier B, Lepreux S, Schaeverbeke T, Taieb A. Cytokine imbalance with increased production of interferon-alpha in psoriasiform eruptions associated with antitumor necrosis factor-alpha treatments. *Br J Dermatol.* 2009;161:1081–8.
 49. Sfrikakis PP, Iliopoulos A, Elezoglou A, Kittas C, Stratigos A. Psoriasis induced by anti-tumor necrosis factor therapy: A paradoxical adverse reaction. *Arthritis Rheum.* 2005;52:2513–8.
 50. Steinwurz F, Denadai R, Saad-Hossne R, Queiroz ML, Teixeira FV, Romiti R. Infliximab-induced psoriasis during therapy for Crohn's disease. *J Crohns Colitis.* 2012;6:610–6.
 51. Viguier M, Richette P, Bachelez H, Wendling D, Aubin F. Paradoxical adverse effects of anti-TNF-alpha treatment: Onset or exacerbation of cutaneous disorders. *Expert Rev Clin Immunol.* 2009;5:421–31.
 52. De Gannes GC, Ghoreishi M, Pope J, Russell A, Bell D, Adams S, et al. Psoriasis and pustular dermatitis triggered by TNF- α inhibitors in patients with rheumatologic conditions. *Arch Dermatol.* 2007;143:223–31.
 53. Cuchacovich R, Espinoza CG, Virk Z, Espinoza LR. Biologic therapy (TNF-alpha antagonists)-induced psoriasis: A cytokine imbalance between TNF-alpha and IFN-alpha? *J Clin Rheumatol.* 2008;14:353–6.
 54. Harrison MJ, Dixon WG, Watson KD, King Y, Groves R, Hyrich KL, et al. Rates of new-onset psoriasis in patients with rheumatoid arthritis receiving anti-tumour necrosis factor alpha therapy: Results from the British Society for Rheumatology Biologics Register. *Ann Rheum Dis.* 2009;68:209–15.
 55. Mourao AF, Rustin M, Isenberg D. Exacerbation of psoriatic skin lesions in patients with psoriatic arthritis receiving anti-tumour necrosis factor-alpha therapy: Description of 3 cases and review of the literature. *Clin Exp Rheumatol.* 2010;28:408–10.
 56. Santos-Juanes J, Galache C. Psoriasiform skin reactions during treatment with etanercept. *Actas Dermosifiliogr.* 2010;101:106–10.
 57. Santos-Juanes J, Coto-Segura P, Mas-Vidal A, Galache Osuna C. Ustekinumab induces rapid clearing of erythrodermic psoriasis after failure of antitumour necrosis factor therapies. *Br J Dermatol.* 2010;162:1144–6.
 58. Fiorino G, Allez M, Malesci A, Danese S. Review article: Anti TNF-alpha induced psoriasis in patients with inflammatory bowel disease. *Aliment Pharmacol Ther.* 2009;29:921–7.
 59. Sari I, Akar S, Birlilik M, Sis B, Onen F, Akkoc N. Anti-tumour necrosis factor-alpha-induced psoriasis. *J Rheumatol.* 2006;33:1411–4.
 60. English PL, Vender R. Occurrence of plantar pustular psoriasis during treatment with infliximab. *J Cutan Med Surg.* 2009;13:40–2.
 61. Wendling D, Balblanc JC, Briancon D, Brousse A, Lohse A, Deprez P, et al. Onset or exacerbation of cutaneous psoriasis during TNFalpha antagonist therapy. *Joint Bone Spine.* 2008;75:315–8.
 62. Pirard D, Arco D, Debrouckere V, Heenen M. Anti-tumor necrosis factor alpha-induced psoriasiform eruptions: Three further cases and current overview. *Dermatology.* 2006;213:182–6.
 63. Lebas D, Staumont-Salle D, Solau-Gervais E, Flipo RM, Delaporte E. Cutaneous manifestations during treatment with TNF-alpha blockers: 11 cases. *Ann Dermatol Venereol.* 2007;134:337–42.
 64. Severs GA, Lawlor TH, Purcell SM, Adler DJ, Thompson R. Cutaneous adverse reaction to infliximab: Report of psoriasis developing in 3 patients. *Cutis.* 2007;80:231–7.
 65. Costa-Romero M, Coto-Segura P, Suarez-Saavedra S, Ramos-Polo E, Santos-Juanes J. Guttate psoriasis induced by infliximab in a child with Crohn's disease. *Inflamm Bowel Dis.* 2008;14:1462–3.
 66. Alghamdi KM, Khurram H, Rikabi A. Worsening of vitiligo and onset of new psoriasiform dermatitis following treatment with infliximab. *J Cutan Med Surg.* 2011;15:280–4.
 67. Michaelsson G, Kajermo U, Michaelsson A, Hagforsen E. Infliximab can precipitate as well as worsen palmoplantar pustulosis: Possible linkage to the expression of tumour necrosis factor-alpha in the normal palmar eccrine sweat duct? *Br J Dermatol.* 2005;153:1243–4.
 68. Laga AC, Vleugels RA, Qureshi AA, Velazquez EF. Histopathologic spectrum of psoriasiform skin reactions associated with tumor necrosis factor-alpha inhibitor therapy. A study of 16 biopsies. *Am J Dermatopathol.* 2010;32:568–73.
 69. Lee HH, Song IH, Friedrich M, Gauliard A, Detert J, Rowert J, et al. Cutaneous side-effects in patients with rheumatic diseases during application of tumour necrosis factor-alpha antagonists. *Br J Dermatol.* 2007;156:486–91.
 70. Brigant F, Clavel G, Chatelain D, Lok C, Chaby G. Letter: A case of generalized guttate psoriasis induced by etanercept with relapse after abatacept. *Dermatol Online J.* 2011;17:11.
 71. Denadai R, Teixeira FV, Saad-Hossne R. Letter: Pathogenesis of tumour necrosis factor-alpha antagonists-induced psoriasiform lesions. *Aliment Pharmacol Ther.* 2012;36:77–8.
 72. Denadai R, Teixeira FV, Saad-Hossne R. The onset of psoriasis during the treatment of inflammatory bowel diseases with infliximab: Should biological therapy be suspended? *Arq Gastroenterol.* 2012;49:172–6.
 73. Guinovart RM, Ferrándiz C, Bielsa I, Carrascosa JM. Episode of pustular psoriasis after a tuberculin test in a patient with plaque psoriasis on treatment with etanercept. *Actas Dermosifiliogr.* 2011;102:828–30.