




# ACTAS Derma-Sifiliográficas

Full English text available at  
[www.actasdermo.org](http://www.actasdermo.org)



## E-CASE REPORT

# The Usefulness of Ultrasound Imaging in Digital and Extradigital Glomus Tumors<sup>☆</sup>



M.E. Gómez-Sánchez,<sup>a,\*</sup> F. Alfageme-Roldán,<sup>b</sup> G. Roustán-Gullón,<sup>b</sup>  
M.A. Segurado-Rodríguez<sup>c</sup>

<sup>a</sup> Servicio de Dermatología, Complejo Hospitalario Universitario de Albacete, Albacete, Spain

<sup>b</sup> Servicio de Dermatología, Hospital Puerta de Hierro Majadahonda, Madrid, Spain

<sup>c</sup> Servicio de Dermatología, Hospital del Sureste, Arganda del Rey, Madrid, Spain

Received 1 June 2013; accepted 14 February 2014

### KEYWORDS

Extradigital glomus tumor;  
Subungual glomus tumor;  
Ultrasound;  
Diagnosis;  
Doppler

### PALABRAS CLAVE

Tumor glómico extradigital;  
Tumor glómico subungueal;  
Ultrasonidos;  
Diagnóstico;  
Doppler

**Abstract** Recent years have witnessed an increase in the use of ultrasound imaging of the skin in the field of dermatology, as the technique reveals details of vessels and other structures that cannot be detected on physical examination. Extradigital glomus tumors are rarely seen in clinical practice and can pose a diagnostic challenge for dermatologists. We report on 4 patients with a clinical suspicion of extradigital glomus tumor and on 1 patient with a clinical suspicion of subungual glomus tumor. All 5 patients underwent ultrasound examination in B mode and color and pulsed-wave Doppler prior to surgical excision of the tumor and histologic examination, which confirmed the diagnosis in each case. Ultrasound imaging of the skin, combined with clinical findings, provided a simple, noninvasive way of making a prompt diagnosis and identifying the exact location of the lesion for surgical removal.

© 2013 Elsevier España, S.L.U. and AEDV. All rights reserved.

### Tumores glómicos digitales y extradigitales. Utilidad de la ecografía cutánea

**Resumen** En los últimos años se ha observado un aumento del uso de la ecografía cutánea en el campo de la dermatología, al proporcionar detalles estructurales y/o vasculares que con la simple exploración física no se pueden apreciar. Los tumores glómicos extradigitales son lesiones poco frecuentes en la práctica clínica y pueden suponer un reto diagnóstico para el dermatólogo. Presentamos 4 pacientes con sospecha clínica de tumor glómico extradigital y un paciente con sospecha de tumor glómico subungueal. A cada paciente se le realizó exploración ecográfica en modo B, doppler color y doppler pulsado, exéresis quirúrgica y análisis histológico que confirmó el diagnóstico sospechado. El uso de la ecografía cutánea añadida a los datos

<sup>☆</sup> Please cite this article as: Gómez-Sánchez ME, Alfageme-Roldán F, Roustán-Gullón G, Segurado-Rodríguez MA. Tumores glómicos digitales y extradigitales. Utilidad de la ecografía cutánea. Actas Dermosifiliogr. 2014;105:e45–e49.

\* Corresponding author.

E-mail address: [m.gomsanchez@hotmail.com](mailto:m.gomsanchez@hotmail.com) (M.E. Gómez-Sánchez).

clínicos permitió de una manera sencilla e inocua evitar retrasos diagnósticos y determinar la localización exacta para una adecuada exéresis quirúrgica.

© 2013 Elsevier España, S.L.U. y AEDV. Todos los derechos reservados.

## Introduction

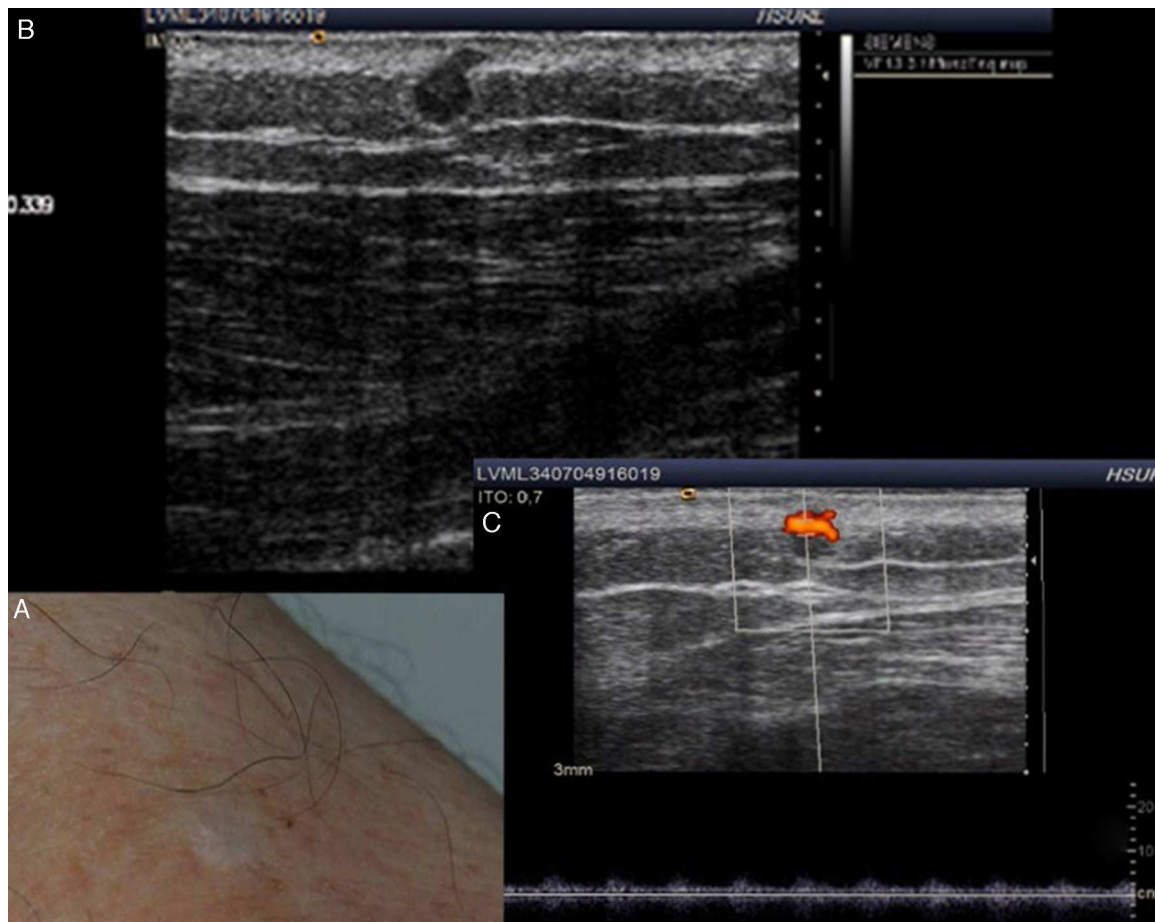
Glomus tumors are an uncommon type of benign neoplasm derived from a structure known as the neuromyoarterial glomus, which contributes to regulation of body temperature.<sup>1-5</sup> These structures are most often found in the skin, in particular in the subungual region.<sup>1</sup> Subungual glomus tumors are suspected when a lesion is found at this typical site,<sup>6</sup> accompanied by a clinical presentation of sensitivity to cold and severe pain that can be

spontaneous or arise after minimal contact. In contrast, diagnosis of extradigital glomus tumors is often mistaken or delayed given the low incidence of such lesions.<sup>3,5</sup> In this study, we aimed to assess the correlation between clinical, histopathologic, and ultrasound findings for extradigital glomus tumors, and compare these findings with the characteristics of digital glomus tumors. We also aimed to describe the usefulness of ultrasound and color Doppler imaging in the diagnosis, surgical treatment, and follow-up of these tumors.

**Table 1** Clinical Cases: Clinical and Ultrasound Characteristics of the Glomic Tumors.

	Case 1	Case 2	Case 3	Case 4	Case 5
<b>Age</b>	65	60	46	67	46
<b>Sex</b>	Male	Male	Female	Male	Female
<b>Site</b>	Lateral face of the elbow	Thigh	Thigh	Lateral face of the elbow	Nail
<b>Clinical Characteristics</b>	Pink macule of 0.5 cm, with a punctiform, erythematous-violaceous papule with central elevation Very painful on palpation	Scar-like macule with poorly defined borders Nodule or underlying tumor not palpable Painful on application of pressure	Two violaceous papules of 0.5 cm with a smooth surface on an erythematous-violaceous base Painful on application of pressure	Palpable nodule with overlying skin of erythematous-blue color, with irregular border, measuring 0.8 cm Painful to touch	Nail dystrophy on the medial face of the first finger of the right hand Very painful to touch and sensitive to the cold at this site
<b>Lesion duration</b>	5 years	35 years	1 year	6 years	4 years
<b>Prior Treatment</b>	No	Electrocoagulation	Electrocoagulation	No	No
<b>Relapse after excision</b>	No	No	No	No	No
<b>Ultrasound study</b>					
<i>B Mode</i>					
<b>Site</b>	Dermis	Dermis-hypodermis	Dermis	Dermis-hypodermis	Dermis
<b>Echostructure</b>	Solid lesion	Solid lesion	Solid lesion, form of use	Solid lesion	Ovaluated lesion
<b>Borders or forms</b>	Regular form	Regular border	Well-defined borders	Well-defined	Well-defined, regular border
<b>Echogenicity</b>	Hypoechoic, homogeneous	Hypoechoic, heterogeneous	Hypoechoic, heterogeneous	Hypoechoic, heterogeneous	Isoechoic
<b>Stalk sign</b>	+	+	-	+	-
<i>Color Doppler</i>					
<b>Flow ±</b>	+	+	+	+	+
<b>Site:</b>	Intralesional	Intralesional	Intralesional	Intralesional	Intralesional
intralesional/ perilesional/both					
<i>Spectral Doppler</i>					
<b>Type of flow:</b>	Arterial	Both	Arterial	Arterial	Arterial
arterial/ venous/both					

Source: Amitay-Laish et al.<sup>14</sup>



**Figure 1** A, Clinical examination of the left thigh shows a scar-like macule with poorly defined borders. B, B mode Doppler ultrasound shows a solid, hypoechoic, spherical lesion with a regular border at the dermal-hypodermal interface. A hypoechoic prolongation in the form of a stalk is seen in the upper part of the lesion. C, Color Doppler mode shows increased vascularization.

## Care Report

We present a total of 5 patients (Table 1), attended in our dermatology department. Three were men and 2 were women, and ages ranged from 42 to 65 years. All patients were seen for longstanding lesions present for several years on the limbs; all were painful with local sensitivity. With clinical suspicion of glomus tumor, each patient underwent a preoperative ultrasound study with a device equipped with a high frequency probe. Images were taken in B mode and color Doppler mode. Pulsed Doppler techniques were also used to characterize blood flow in intratumoral and peritumoral vessels. All patients had similar ultrasound findings, consistent with a vascularized tumor embedded in soft tissue. Once the extent of the lesion had been defined with the help of ultrasound, it was excised and the surgical defect was directly closed. In the case of the subungual lesion, the tumor was fully excised with access achieved by raising the proximal nail bed. After excision, the surgical defect was closed (Figures 1 and 2).

The histologic findings were consistent with glomus tumor, with well-defined solid nodules surrounded by compact fibrotic tissue and no encapsulation. These nodules were comprised of monomorphous polygonal groups of

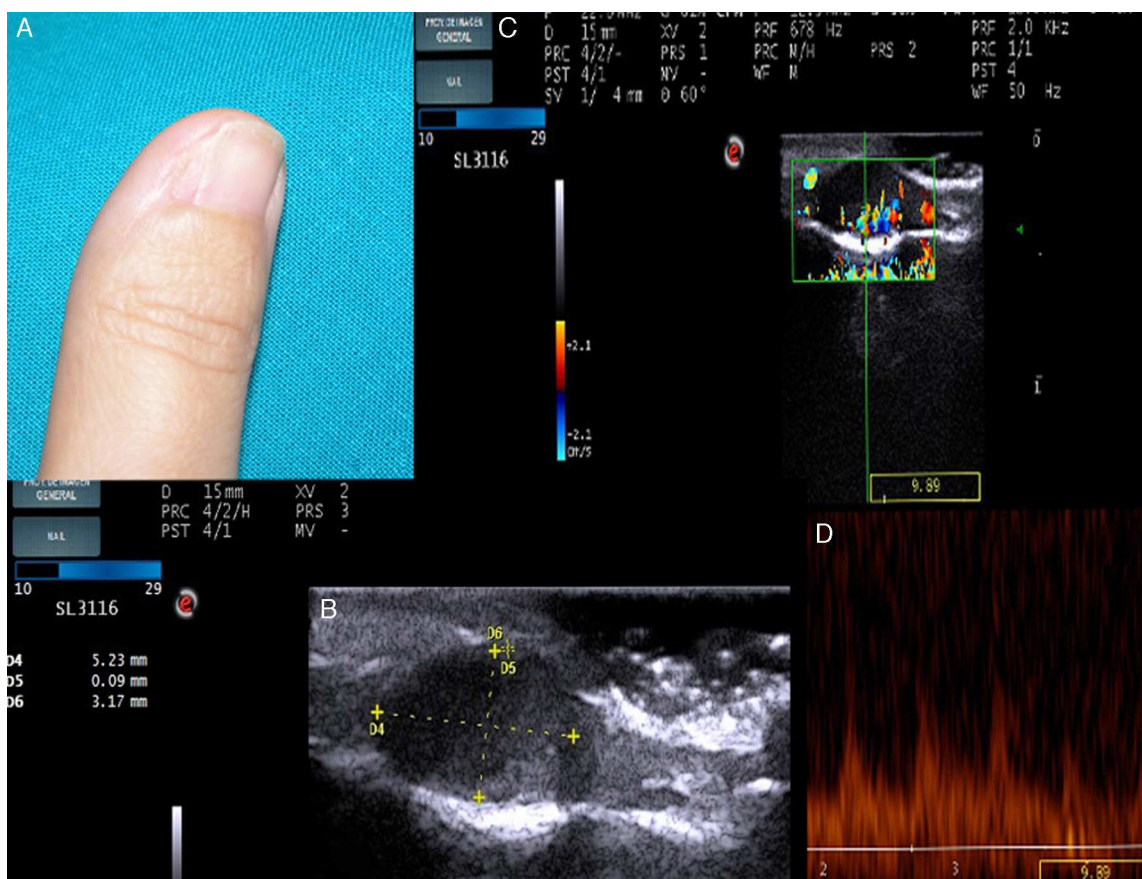
glomus cells. Small vascular spaces could be discerned among these cell groups, surrounded by a fascicle of endothelial cells. In the immunohistochemical study, smooth muscle stained positive for actin and negative for desmin.

Subsequently, all patients underwent regular clinical and ultrasound follow-up and remained free of signs of recurrence. In the patient with a subungual glomus tumor, substantial nail dystrophy was present after surgery as a sequelae.

## Discussion

It is estimated that glomic tumors comprise 1.6% of all soft tissue tumors<sup>5,7</sup> and 4.5% of all tumors on the hand. They are classified into 2 variants: solitary glomus tumors and multiple glomus tumors, with clinical and anatomopathologic differences.<sup>1</sup>

Solitary tumors are the most common and are the subject of the discussion in this article.<sup>1</sup> They can manifest in the form of erythematous-violaceous nodule, red-pink or blue tipped macule, or increased curvature or deformity of the nail plate.<sup>8</sup> Glomus tumors are classified according to their site as digital and extradigital. Extradigital tumors are less



**Figure 2** A, The examination shows nail dystrophy on the medial face of the first finger of the right hand. B, B mode Doppler image showing a well-defined, solid hypoechoic lesion with an oval form and regular borders. C, In Color Doppler mode, extensive vascularization can be seen in the nail bed. D, Spectral analysis shows low grade systolic arterial flow within the lesion.

common. The typical clinical presentation is one of localized pain and sensitivity and hypersensitivity to cold (Table 2).<sup>1-8</sup>

Our patients were aged between 60 and 70 years in the case of extradigital sites and all were men, whereas the patient with the digital tumor was a woman in her forties. This is all consistent with what is reported in the literature, even though the sample was not particularly representative given the low number of patients. This difference between sites could be either because the tumor occurs in elderly patients or because often the atypical site of these tumors hinders diagnosis<sup>4</sup> and they are confused with hemangiomas, neuromas, or neurofibromas,<sup>3,5</sup> with subsequent delay in definitive diagnosis. According to some authors, the mean time to definitive diagnosis of extradigital glomus tumors

can vary between 5 and 20 years.<sup>3</sup> In fact, in 1 of the cases presented as an extradigital glomus tumor, correct diagnosis was delayed 35 years due to erroneous initial diagnosis and the fact that use of cryotherapy masked the clinical picture.

Ultrasound has only recently been used as an additional study for diagnosis and follow-up of cutaneous lesions. Applications include a range of inflammatory diseases, benign and malignant tumors, and even esthetics.<sup>9</sup> In the ultrasound images captured in B mode, glomus tumors are seen as small solid, hypoechoic, well-defined nodules, more or less homogenous, with a regular border, most often located in the superficial dermis, with no involvement of the deep layers.<sup>2,4,6,10</sup> In our patients, all tumors were in the dermis except 2 (patients 2 and 4) at the dermal-hypodermal

**Table 2** Clinical Differences Between Subungual and Extradigital Glomus Tumors.

Clinical Characteristics	Subungual Glomus Tumor	Extradigital Glomus Tumor
Sex	Female 2:1	Male 4:1
Age on diagnosis	Twenties and fifties	Forties and sixties
Clinical characteristics	Pain, localized sensitivity and hypersensitivity to cold	Pain
Correct initial diagnosis	Often	Less often

Source: Schiefer et al.<sup>3</sup>; Lee et al.<sup>5</sup>



interface. These did not however penetrate the hypodermis. The color Doppler study shows extensive vascularization inside the tumor, as would be expected with a vascular type tumor such as a glomus tumor.<sup>2,4,10,11</sup> In addition, the pulsed Doppler study usually shows a low-grade systolic murmur. Both characteristics help us to differentiate such tumors, in the first instance, from other nonvascularized soft tissue tumors.<sup>4,12</sup> However, an intense vascular signal in the Doppler study can also be seen in hemangiomas or arteriovenous malformations. Some B-mode ultrasound findings can assist in the differential diagnosis (Table 1). In hemangiomas, grey-scale images do not show such homogeneous echogenicity and the margins are less well defined. In addition, vascular flow is diminished as blood pools are present. Malformations are usually more poorly defined lesions compared to surrounding tissue, with no mass effect, and they show the typical arteriovenous shunt.<sup>4</sup> Three of our patients had the typical stalk sign. This sign corresponds to a hypoechoic prolongation of the lesion by the stalk, which in Doppler mode reveals an intense vascularization characteristic of vascular lesions such as glomus tumors.<sup>2</sup> Nevertheless, images obtained by ultrasound are not specific to any particular lesion, and diagnosis of glomus tumor is clinical, with confirmation from histopathologic study. However, cutaneous ultrasound can guide diagnosis, providing significant information in a simple skin examination.<sup>9</sup> Study of ultrasound images is also very useful for exactly, simply, quickly, and painlessly locating the lesion prior to excision. The technique can reveal the relationship with surrounding tissue to enable complete excision with minimal trauma and so avoid subsequent recurrence.<sup>2,6,13</sup> Ultrasound has been able to detect tumors as small as 1 mm,<sup>2</sup> reflecting its usefulness in the early diagnosis of lesions. The limitations of ultrasound are seen with flat lesions less than 3 mm across<sup>6</sup> and with sites where artifacts may appear, such as subungual if the nail is very thick.<sup>13</sup>

The use of supplementary magnetic resonance imaging is a useful, noninvasive method, but it is more costly and so its use in everyday clinical practice does not appear to be justified.<sup>2,6,8</sup> Radiography is inexpensive and quick, but it is only useful in large tumors and in subungual tumors to differentiate them from subungual exostosis.<sup>6</sup>

In conclusion, we highlight the usefulness of ultrasound for early diagnosis, detailed information on location, and guidance for complex excision of glomus tumors, as observed in our patients.

## Conflicts of Interest

The authors declare that they have no conflicts of interest.

## References

1. Requena L. Tumores glómicos. In: Requena L, editor. *Tumores cutáneos de partes blandas*. 1.<sup>a</sup> ed. Madrid: Aula médica; 2012. p. 597–603.
2. Wortsman X, Jemec GB. Role of high-variable frequency ultrasound in preoperative diagnosis of glomus tumors. *Am J Clin Dermatol*. 2009;10:23–7.
3. Schiefer TK, Parker WL, Anakwenze OA, Amadio PC, Inwards CY, Spinner RJ. Glomus tumors: A 20-year experience. *Mayo Clin Pro*. 2006;81:1337–44.
4. Park HJ, Jeon YH, Kim SS, Lee SM, Kim WT, Park NH, et al. Gray-scale and color doppler sonographic appearances of nonsubungual soft-tissue glomus tumors. *Clin Ultrasound*. 2011;39:305–9.
5. Lee DK, Yang JH, Chang S, Won CH, Lee MW, Choi JH, et al. Clinical and pathological characteristics of extradigital and digital glomus tumours: A retrospective comparative study. *JEADV*. 2011;25:1392–7.
6. Takemura N, Fujii N, Tanaka T. Subungual glomus tumor diagnosis based on imaging. *J Dermatol*. 2006;33:389–93.
7. Rao AG, Indira D, Kamal J. Extra digital glomangioma. *Indian J Dermatol*. 2010;55:397–8.
8. Samaniego E, Crespo A, Sanz A. Claves del diagnóstico y tratamiento del tumor glómico subungueal. *Actas Dermosifiliogr*. 2009;100:875–82.
9. Wortsman X. Common applications of dermatologic sonography. *J Ultrasound Med*. 2012;31:97–111.
10. Baek HJ, Lee SJ, Cho KH, Choo HJ, Lee SM, Lee YH, et al. Subungual tumors: Clinicopathologic correlation with US and MR imaging findings. *Radiographics*. 2010;30:1621–36.
11. Koibuchi H, Fujii Y, Taniguchi N. An unusual case of a glomus tumor developing in a subcutaneous vein of the wrist. *J Clin Ultrasound*. 2008;36:369.
12. Matsunaga A, Ochiai T, Abe I, Kawamura A, Muto R, Tomita Y, et al. Subungual glomus tumour: Evaluation of ultrasound imaging in preoperative assessment. *Eur J Dermatol*. 2007;17:67–9.
13. Chen S, Chen Y, Cheng M, Yeow K, Chen H, Wei F. The use of ultrasonography in preoperative localization of digital glomus tumors. *Plast Reconstr Surg*. 2003;112:115–9.
14. Alfageme F, Cerezo E, Villegas C. *Manual de ecografía cutánea*. Charleston: Createspace Independent Platform Publisher; 2013. p. 79–88.