

10. Ferreira MA, Galvez-Jimenez N. Sirsasana (headstand) pose causing compressive myelopathy with myelomalacia. *JAMA Neurol.* 2013;70:268.

P. García-Martín,<sup>a,\*</sup> M. Llamas-Velasco,<sup>a</sup>  
J. Fraga,<sup>b</sup> A. García-Diez<sup>a</sup>

<sup>a</sup> Servicio de Dermatología, Hospital Universitario de La Princesa, Madrid, Spain

<sup>b</sup> Servicio de Anatomía Patológica, Hospital Universitario de La Princesa, Madrid, Spain

\* Corresponding author.

E-mail address: [pgarciamartin@aedv.es](mailto:pgarciamartin@aedv.es) (P. García-Martín).

## An Amelanotic Dysplastic Melanocytic Nevus Induced by Vemurafenib<sup>☆</sup>



### Nevus melanocítico atípico amelanótico inducido por vemurafenib

Vemurafenib is a B-raf kinase inhibitor developed to treat metastatic melanoma in patients with the *BRAF* V600E mutation, which is found in 40% to 60% of patients with advanced melanoma. It acts by inhibiting the BRAF/MEK/ERK mitogen-activated protein kinase (MAPK) pathway at the BRAF/MEK step. Recent studies have reported that vemurafenib is associated with a 63% reduction in risk of death.<sup>1,2</sup> Adverse effects include joint pain, photosensitivity, alopecia, fatigue, hyperkeratosis, xerosis, nonspecific rash, keratoacanthoma, and squamous cell carcinoma.<sup>3-5</sup> We report the case of a patient with stage IV melanoma who developed a clinically amelanotic dysplastic melanocytic nevus 2 months after starting treatment with vemurafenib.

The patient was a 42-year old white man who had been diagnosed with a stage IV melanoma on the right arm 6 years earlier. Sentinel node biopsy results were positive and the patient underwent right axillary lymph node dissection followed by interferon therapy. Follow-up screening 6 years after surgery led to the detection of 2 pulmonary nodules and metastatic lesions in the C5 and T11 vertebrae, both iliac wings, and the sacrum. After confirmation of the presence of the *BRAF* V600E mutation, treatment was started with 960 mg of vemurafenib every 12 hours. Two months into treatment, we examined a 10 × 8-mm<sup>2</sup> papular lesion on the left thigh that had been absent at the preceding visit, 1 month earlier, and had grown to this size gradually. The lesion was dome-shaped, skin-colored, and asymptomatic (Fig. 1). With a suspected diagnosis of hypertrophic actinic keratosis, complete excisional biopsy of the lesion was performed. Histologic findings included a proliferation of melanocytes in the epidermis and papillary dermis, with mild architectural disorder (Fig. 2). Melanocytes were arranged in nests in the epidermis and papillary dermis, and nuclear pleomorphism was mild. Immunohistochemical staining with Melan-A and HMB-45 showed a proliferation of melanocytes in the basal layer of the epidermis and scattered single melanocytes in the upper layers (Fig. 3). All these findings were consistent with a dysplastic nevus.

<sup>☆</sup> Please cite this article as: Estela Cubells JR, Victoria Martínez AM, Oliver Martínez V, Alegre de Miquel V. Nevus melanocítico atípico amelanótico inducido por vemurafenib. *Actas Dermosifiliogr.* 2014;105:726-727.

In cells with wild-type *BRAF*, vemurafenib increases phosphorylation of ERK (extracellular signal-regulated kinase) and thus paradoxically induces hyperactivation of the MAPK signaling pathway, promoting cell proliferation and survival. Hyperactivation is responsible for adverse effects such as keratoacanthoma, squamous cell carcinoma, and actinic keratosis. This paradoxical activation effect can also trigger progression of benign melanocytic lesions to melanoma.<sup>6</sup> Atypical melanocytic proliferation and the development of new melanomas have been described in patients undergoing treatment with vemurafenib, and vemurafenib-induced changes in preexisting nevi have been observed by dermoscopy.<sup>7</sup>

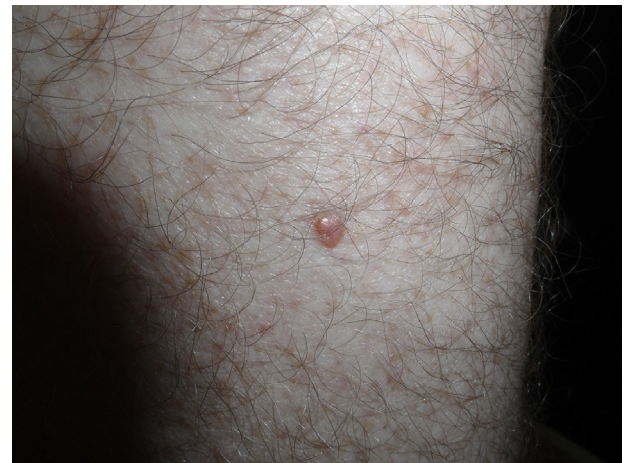

Figure 1 Papular skin-colored lesion on the left thigh.

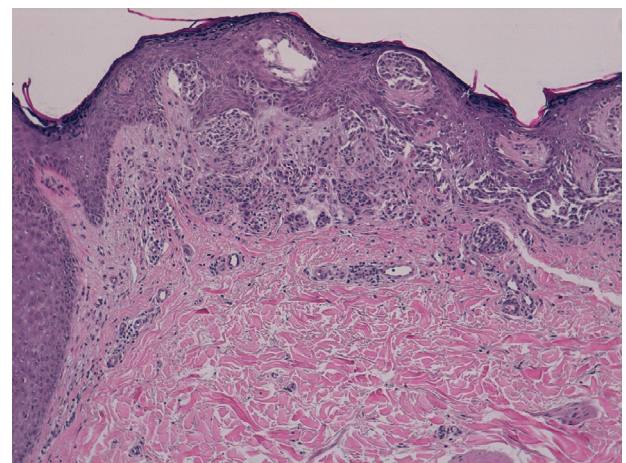
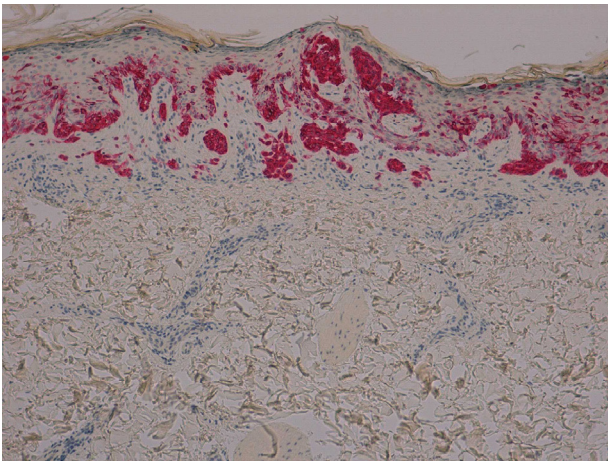


Figure 2 Proliferation of melanocytes in the epidermis and papillary dermis, with mild architectural disorder (hematoxylin-eosin, original magnification ×40).



**Figure 3** Nests of melanocytes in the basal layer of the epidermis with sparse single melanocytes in the upper layers (Melan-A, original magnification  $\times 100$ ).

This case in which a patient on vemurafenib developed an amelanotic dysplastic melanocytic nevus highlights the need to monitor this kind of lesion closely and perform a biopsy if there is any doubt, to ensure early detection of incipient malignancies.

### Bibliografía

1. Chapman PB, Hauschild A, Robert C, Haanen JB, Ascierto P, Larkin J, et al. Improved survival with vemurafenib in melanoma with BRAF V600E mutation. *N Engl J Med.* 2011;364:2507–16.

2. Chu EY, Wanat KA, Miller CJ, Amaravadi RK, Fecher LA, Brose MS, et al. Diverse cutaneous side effects associated with BRAF inhibitor therapy: A clinicopathologic study. *J Am Acad Dermatol.* 2012;67:1265–72.
3. Gerami P, Sorrell J, Martini M. Dermatoscopic evolution of dysplastic nevi showing high-grade dysplasia in a metastatic melanoma patient on vemurafenib. *J Am Acad Dermatol.* 2012;67:e275–6.
4. Huang V, Hepper D, Anadkat M, Cornelius L. Cutaneous toxic effects associated with vemurafenib and inhibition of the BRAF pathway. *Arch Dermatol.* 2012;148:628–33.
5. Kaplan FM, Shao Y, Mayberry MM, Aplin AE. Hyperactivation of MEK-ERK1/2 signaling and resistance to apoptosis induced by the oncogenic B-RAF inhibitor, PLX4720, in mutant N-RAS melanoma cells. *Oncogene.* 2011;30:366–71.
6. Lacouture ME, Duvic M, Hauschild A, Prieto VG, Robert C, Schadendorf D, et al. Analysis of dermatologic events in vemurafenib-treated patients with melanoma. *Oncologist.* 2013;18:314–22.
7. Sosman JA, Kim KB, Schuchter L, Gonzalez R, Pavlick AC, Weber JS, et al. Survival in BRAF V600-mutant advanced melanoma treated with vemurafenib. *N Engl J Med.* 2012;366:707–14.

J.R. Estela Cubells,\* A.M. Victoria Martínez,  
V. Oliver Martínez, V. Alegre de Miquel

*Servicio de Dermatología, Consorcio Hospital General  
Universitario de Valencia, Valencia, España*

\* Corresponding author.

*E-mail address:* j.estela@hotmail.com

(J.R. Estela Cubells).