

exclude skin metastases and B-cell lymphoma. The diagnosis of these lesions must be confirmed histologically. Skin metastases, most commonly from melanoma, are seen as oval anechoic structures with dense vascularization.⁶ B-cell lymphoma presents as a well-defined, hypoechoic nodular lesion with a good vascular supply in the dermis or subcutaneous cellular tissue.⁷

There is only 1 report of a case of cutaneous AHE that gives a description of its sonographic pattern.⁸ In that case, a hyperechoic lesion was observed on the forearm and had a peripheral hypoechoic ring and increased blood flow on Doppler study. The absence of other reports is probably because the condition was considered part of the spectrum of Kimura disease until a few years ago. The 2 diseases, though clinically similar, are now considered to be different entities because of the differences in extracutaneous involvement, laboratory tests, and histological findings, leading to a completely different prognosis. A larger number of articles have been published on Kimura disease. The characteristic image is of a heterogeneous hypoechoic mass with poorly defined borders, situated in the dermis and subcutaneous cellular tissue, with intermingled, hyperechoic and hypoechoic curvilinear structures, which has been called a "woolly" pattern.⁹ The vascularization of the lesions is variable.¹⁰ Our case shows the sonographic characteristics of both diseases as the woolly pattern was observed, associated with hypervascularization and a hypoechoic halo.

Skin ultrasound is a useful tool for the diagnosis of subcutaneous lesions. Although the woolly pattern is characteristic, it does not enable us to distinguish between AHE and Kimura disease. These findings testify to the difficulty of differentiating between the 2 diseases and to the need for histological confirmation.

References

1. Guinovart RM, Bassas-Vila J, Morell L, Ferrándiz C. Hiperplasia angioliinfoide con eosinofilia. Estudio clínico patológico de 9 casos. *Actas Dermosifiliogr*. 2013. En prensa.
 2. Wortsman X. Common applications of dermatologic sonography. *J Ultrasound Med*. 2012;31:97–111.
 3. Kuwano Y, Ishizaki K, Watanabe R, Nanko H. Efficacy of diagnostic ultrasonography of lipomas, epidermal cysts, and ganglions. *Arch Dermatol*. 2009;145:761–4.
 4. Glazebrook KN, Laundre BJ, Schiefer TK, Inwards CY. Imaging features of glomus tumors. *Skeletal Radiol*. 2011;40:855–62.
 5. Restrepo R. Multimodality imaging of vascular anomalies. *Pediatr Radiol*. 2013;43 Suppl 1:141–54.
 6. Schäfer-Hesterberg G, Schoengen A, Sterry W, Voit C. Use of ultrasound to early identify, diagnose and localize metastases in melanoma patients. *Expert Rev Anticancer Ther*. 2007;7:1707–16.
 7. Malaguarnera M, Giordano M, Russo C, Puzzo L, Trainiti M, Consoni AS, et al. Lymphoma of cheek: A case report. *Eur Rev Med Pharmacol Sci*. 2012;16 Suppl 4:4–7.
 8. Mak CW, Tzeng WS, Chen CY, Chou CK, Lin CN. Sonographic appearance of angiolymphoid hyperplasia with eosinophilia in the upper arm. *J Clin Ultrasound*. 2008;36:448–50.
 9. Ching AS, Tsang WM, Ahuja AT, Metreweli C. Extranodal manifestation of Kimura's disease: Ultrasound features. *Eur Radiol*. 2002;12:600–4.
 10. Lin YY, Jung SM, Ko SF, Toh CH, Wong AM, Chen YR, et al. Kimura's disease: Clinical and imaging parameters for the prediction of disease recurrence. *Clin Imaging*. 2012;36:272–8.
- M. Lorente-Luna,^{a,*} F. Alfageme-Roldán,^b D. Suárez-Massa,^c E. Jiménez-Blázquez^a
- ^a *Servicio de Dermatología, Hospital Universitario de Guadalajara, Guadalajara, Spain*
^b *Servicio de Dermatología, Hospital Universitario Puerta de Hierro, Madrid, Spain*
^c *Servicio de Anatomía Patológica, Hospital Universitario Puerta de Hierro, Madrid, Spain*
- * Corresponding author.
E-mail addresses: m.lorente.luna@gmail.com, mlorentel@sescam.jccm.es (M. Lorente-Luna).

Ustekinumab for Hidradenitis Suppurativa: A Case Report[☆]



Ustekinumab en hidradenitis suppurativa: a propósito de un caso

Hidradenitis suppurativa is a chronic and recurrent inflammatory disease that causes disfiguring lesions in areas rich in apocrine sweat glands.¹

Prevalence is estimated at 1% to 4%, women are affected more often than men (at a ratio of 3:1), and onset is typically in the second or third decade of life.^{1,2}

[☆] Please cite this article as: Santos-Pérez MI, García-Rodicio S, del Olmo-Revuelto MA, Pozo-Román T. Ustekinumab en hidradenitis suppurativa: a propósito de un caso. *Actas Dermosifiliogr*. 2014;105:720–722.

While its etiology and pathogenesis are largely unknown, hidradenitis suppurativa is considered a multifactorial disease in which the immune system plays a prominent role. Management of hidradenitis suppurativa should be tailored to lesion severity and distribution assessed according to the Hurley staging system.³ As no specific treatments are available, a wide range of therapeutic options are used with highly variable results. Antibiotics, corticosteroids, and retinoids may be helpful in the early stages and during exacerbations; in advanced or extensive forms of the disease, surgical resection of the affected tissue is imperative.⁴ Biologic agents, particularly tumor necrosis factor (TNF) inhibitors, have been proposed in recent years for recalcitrant forms of hidradenitis suppurativa. Experience with other biologic agents having different mechanisms of action, such as p40 inhibition, is anecdotal.

We report the case of a 50-year-old female smoker with moderate-to-severe hidradenitis suppurativa (Hurley stage

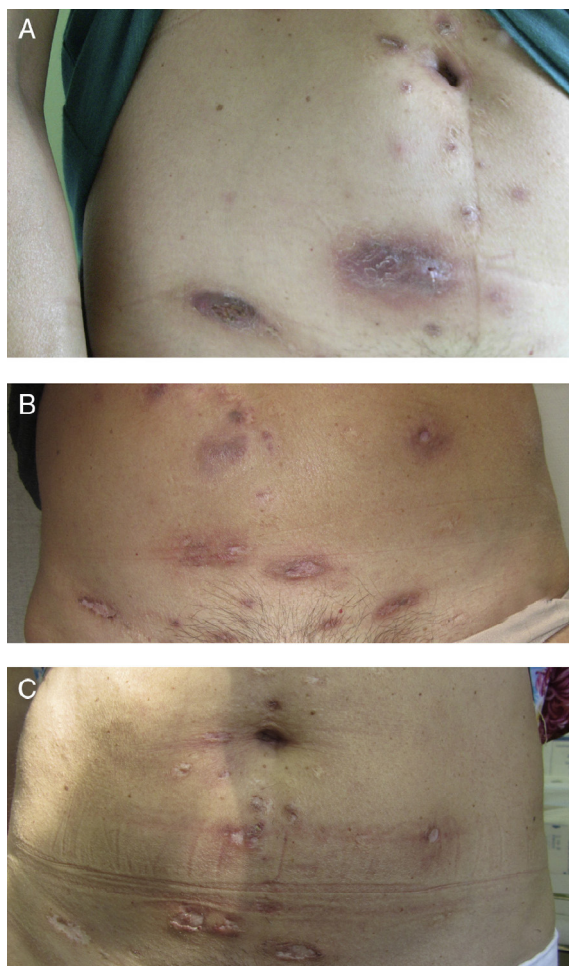


Figure 1 Lesions on the abdomen. A, Before ustekinumab. B, After 1 month of ustekinumab. C, After 8 months of ustekinumab.

II-III). The condition had been diagnosed at age 16 years and had worsened 25 years later. Recent treatments had included a course of isotretinoin and 4 surgical procedures that had involved the face and breasts.

In April 2009, as the condition had proved refractory to treatment, the patient started a new treatment with an 80-mg loading dose of adalimumab, followed by 40 mg every 14 days beginning one week later. Her condition remained stable for 1 year, after which the dosing interval was increased to 21 days. However, 6 months after this change the lesions had worsened and the 14-day regimen was reinstated, with the addition of prednisone for 1 month. Treatment was discontinued 6 months later owing to loss of efficacy (i.e. lesion recurrence) and adverse effects.

After 2 years of adalimumab, the patient was switched to infliximab 5 mg/kg at weeks 0, 2, and 6; however, this regimen was discontinued after 3 doses because the lesions worsened.

In October 2011, because of the severity of her lesions and the lack of other options, off-label treatment was proposed with 45 mg of subcutaneous ustekinumab at weeks 0 and 4, and at 12-week intervals thereafter, and hospital authorization was granted. Disease activity ceased to progress from the start of treatment, although 3 months passed before a clear improvement of the lesions was observed. After 8 months the disease was no longer active (Figs. 1 and 2). At the time of writing, 1½ years into treatment with ustekinumab, the patient has no active lesions and is tolerating therapy well. During the treatment period there were 2 exacerbations. Both were resolved with a 3-week course of antibiotics (amoxicillin-clavulanic acid at 500 mg/8 h in one case, and rifampicin at 300 mg/12 h in the other), plus prednisone.

Hidradenitis suppurativa is an orphan disease, not because its prevalence (1%-4%) is low, but because there are no therapies that produce sustained clinical remission, let alone any curative effect.

Recent studies in hidradenitis suppurativa have highlighted the role of the immune system and its proinflammatory action, including overexpression of interleukins 12 and 23 and of TNF.^{5,6}

TNF inhibitors are a therapeutic option for advanced-stage patients who fail to respond to conventional treatment, but response, if achieved, appears to last only as long as treatment is continued. Because of this drawback, as well as their side effects and high cost, TNF inhibitors are relegated to second- or third-line treatment.⁷ Ustekinumab,

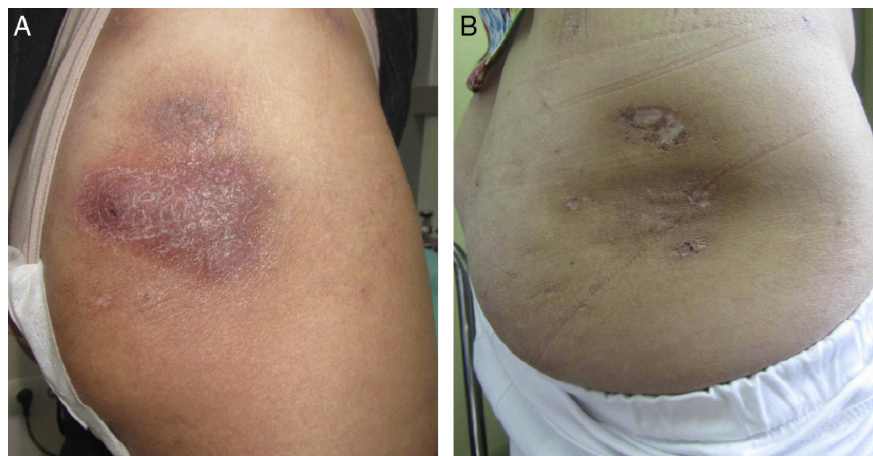


Figure 2 Lesion on the buttocks. A, After 1 month of ustekinumab. B, After 8 months of ustekinumab.

a monoclonal antibody that blocks interleukins 12 and 23, is rarely used to treat hidradenitis suppurativa, and conclusive evidence on its efficacy is lacking.

In the case described, after the patient's condition had failed to respond well to conventional therapy or 2 different TNF inhibitors, we requested authorization for off-label use of ustekinumab, a drug indicated for moderate to severe psoriasis. Treatment was initiated once the authorization was received, and the patient remains clinically stable at the time of writing after 1½ years' treatment.

A review of the literature shows that the experience with ustekinumab in hidradenitis suppurativa is anecdotal, with just one 3-case series in which response to treatment was uneven and 2 individual case reports of patients who had other associated inflammatory skin conditions (psoriasis and Behçet disease).⁸⁻¹⁰

The data presented suggest that ustekinumab could be a therapeutic option for treatment-refractory hidradenitis suppurativa.

References

1. Revuz J. Hidradenitis suppurativa. *J Eur Acad Dermatol Venereol.* 2009;23:985-98.
2. Alikhan A, Lynch PJ, Eisen DB. Hidradenitis suppurativa: A comprehensive review. *J Am Acad Dermatol.* 2009;60:539-63.
3. Hurley HJ. Axillary hyperhidrosis, apocrine bromhidrosis, hidradenitis suppurativa, and familial benign pemphigus: Surgical approach. In: Roenigk RK, Roenigk HH, editors. *Dermatologic surgery.* New York: Marcel Dekker; 1989. p. 729-39.
4. Jemec GB. Clinical practice. Hidradenitis suppurativa. *N Engl J Med.* 2012;366:158-64.

5. Schlapbach C, Hanni T, Yawalkar N, Hunger RE. Expression of the IL-23/Th17 pathway in lesions of hidradenitis suppurativa. *J Am Acad Dermatol.* 2011;65:790-8.
6. Matusiak L, Bieniek A, Szepietowski JC. Increased serum tumour necrosis factor-alpha in hidradenitis suppurativa patients: Is there a basis for treatment with anti-tumour necrosis factor-alpha agents? *Acta Derm Venereol.* 2009;89:601-3.
7. Shuja F, Chan CS, Rosen T. Biologic drugs for the treatment of hidradenitis suppurativa: An evidence-based review. *Dermatol Clin.* 2010;28:511-21.
8. Gulliver WP, Jemec GB, Baker KA. Experience with ustekinumab for the treatment of moderate to severe hidradenitis suppurativa. *J Eur Acad Dermatol Venereol.* 2012;26:911-4.
9. Sharon VR, Garcia MS, Bagheri S, Goodarzi H, Yang C, Ono Y, et al. Management of recalcitrant hidradenitis suppurativa with ustekinumab. *Acta Derm Venereol.* 2012;92:320-1.
10. Baerveldt EM, Kappen JH, Thio HB, van Laar JA, van Hagen PM, Prens EP. Successful long-term triple disease control by ustekinumab in a patient with Behçet's disease, psoriasis and hidradenitis suppurativa. *Ann Rheum Dis.* 2013;72:626-7.

M.I. Santos-Pérez,^{a,*} S. García-Rodicio,^a
M.A. del Olmo-Revuelto,^a T. Pozo-Román^b

^a Servicio de Farmacia, Hospital Universitario del Río Hortega, Valladolid, Spain

^b Servicio de Dermatología, Hospital Universitario del Río Hortega, Valladolid, Spain

* Corresponding author.

E-mail address: marisp243@hotmail.com
(M.I. Santos-Pérez).

Probable Iatrogenic Xanthotrichia[☆]



Xantotriquia probablemente iatrogénica

We report the case of an 82-year-old man who came to our clinic because his hair had acquired a yellowish hue over the previous 10 months. Relevant medical history included chronic ischemic heart disease and dyslipidemia, which had been treated for over 10 years with acetylsalicylic acid (Adiro 1 × 100mg tablet daily) and simvastatin (Pantok 1 × 20mg tablet daily). One year before the consultation, he had been diagnosed with benign prostatic hyperplasia, which was being treated with once daily tamsulosin hydrochloride 0.4 mg (Omnice Ocas).

Physical examination revealed scalp hair with a yellow-orange hue, especially in the frontal and parietal regions (Fig. 1). The patient's natural hair color is gray and he denied using dyes and other hair treatments or making any change in his normal shampoo. His body hair retained its natural whitish color and the physical examination was otherwise

normal. However, the patient also reported that for a few months his sweat had an orange hue while his tears and urine were normal.

Blood tests carried out included direct and total bilirubin, transaminases, alkaline phosphatase, albumin, prothrombin time, complete blood cell count, lactate dehydrogenase, haptoglobin, thyroid hormones, protein electrophoresis, glucose, lipids, and beta-carotene levels. The results of all blood tests and urinalysis were normal. In view of the bright yellow color of the tamsulosin hydrochloride tablet (Omnice Ocas, Astella Pharma), a color produced by yellow iron oxide (E172), and the fact that the onset of the symptom coincided with the introduction of this treatment, we decided to discontinue the drug after consultation with the urology and pharmacy departments. The yellow hair coloring gradually disappeared on follow-up and was undetectable at 10 months (Fig. 2). We have reported the reaction to the Valencian Regional Pharmacovigilance Centre by way of a yellow card. We have also reported it to the pharmaceutical company who manufacture the drug (Astellas Pharma). The company said it was unaware of any association between tamsulosin and this adverse effect and went on to say that the symptom could be caused by an adverse reaction to an excipient.

Hair color changes have been described in association with the consumption of certain drugs and other exogenous

[☆] Please cite this article as: Martí Fajardo N, García Llopis P, Ibáñez Ramón R, Ortega Monzó C. Xantotriquia probablemente iatrogénica. *Actas Dermosifiliogr.* 2014;105:722-723.