




ACTAS Derma-Sifiliográficas

Full English text available at
www.actasdermo.org



NOVELTIES IN DERMATOLOGY

Daylight-Mediated Photodynamic Therapy in Spain: Advantages and Disadvantages[☆]



L. Pérez-Pérez,^{a,b,*} J. García-Gavín,^{a,b} Y. Gilaberte^c

^a Servicio de Dermatología, Gerencia de Gestión Integrada de Vigo, Complejo Hospitalario Universitario de Vigo, Vigo, Spain

^b Clínica Pérez & Gavín Dermatólogos, Vigo, Spain

^c Servicio de Dermatología, Hospital de San Jorge, Huesca, Spain

Received 16 August 2013; accepted 9 October 2013

Available online 31 July 2014

KEYWORDS

Photodynamic therapy;
Daylight-mediated photodynamic therapy;
Methylester of 5-aminolevulinic acid;
5-aminolevulinic acid;
Actinic keratosis;
Treatment

Abstract Photodynamic therapy (PDT) is an option for the treatment of actinic keratosis, Bowen disease, and certain types of basal cell carcinoma. It is also used to treat various other types of skin condition, including inflammatory and infectious disorders. The main disadvantages of PDT are the time it takes to administer (both for the patient and for health professionals) and the pain associated with treatment. Daylight-mediated PDT has recently been reported to be an alternative to the conventional approach. Several studies have shown it to be similar in efficacy to and better tolerated than classic PDT for the treatment of mild to moderate actinic keratosis. Nevertheless, most of these studies are from northern Europe, and no data have been reported from southern Europe. The present article reviews the main studies published to date, presents the treatment protocol, and summarizes our experience with a group of treated patients.

© 2013 Elsevier España, S.L.U. and AEDV. All rights reserved.

PALABRAS CLAVE

Terapia fotodinámica;
Terapia fotodinámica con luz de día;
Metiléster del ácido 5-aminolevulínico;
Ácido 5-aminolevulínico;

Terapia fotodinámica con luz de día en España: ventajas y limitaciones

Resumen La terapia fotodinámica (TFD) constituye una alternativa terapéutica para las queratosis actínicas, la enfermedad de Bowen y determinados carcinomas basocelulares. Se utiliza además para el tratamiento de otras enfermedades cutáneas de diversa naturaleza, incluyendo enfermedades inflamatorias e infecciosas. Los principales inconvenientes de la TFD convencional son el tiempo que consume su realización (al paciente y al personal sanitario) y el dolor que produce. Recientemente se ha descrito la TFD con luz de día (TFDLD) como alternativa al procedimiento convencional. En diversos estudios se ha mostrado similar en eficacia y mejor

[☆] Please cite this article as: Pérez-Pérez L, García-Gavín J, Gilaberte Y. Terapia fotodinámica con luz de día en España: ventajas y limitaciones. Actas Dermosifiliogr. 2014;105:663–674.

* Corresponding author.

E-mail address: lperez@pgdermatologos.com (L. Pérez-Pérez).

Queratosis actínicas; Tratamiento

tolerada que la TFD clásica en el tratamiento de queratosis actínicas leves-moderadas. No obstante, la mayoría de los estudios realizados proceden del norte de Europa, y no existen por ahora resultados en países de la latitud de España. El presente artículo revisa los principales estudios publicados hasta el momento, expone el protocolo de utilización y resume nuestra experiencia en un grupo de pacientes tratados.

© 2013 Elsevier España, S.L.U. y AEDV. Todos los derechos reservados.

Introduction

Photodynamic therapy (PDT) has become established as a treatment for actinic keratosis (AK), Bowen disease, and certain types of basal cell carcinoma over the past decade because it is highly effective for these dermatoses and gives excellent cosmetic results.¹⁻⁵ PDT is currently included in clinical guidelines for treating nonmelanoma skin cancers^{1,4,6-10} and is considered the first line of therapy for multiple AKs and field cancerization.^{4,11-15} The range of indications for PDT has broadened in recent years and now encompasses infectious conditions,¹⁶⁻¹⁹ inflammatory dermatoses,^{8,20-22} adnexal diseases,²³⁻²⁵ skin tumors,^{17,26-28} and photoaging.^{8,29-31} The potential value of PDT as a preventive treatment in transplant patients or those with conditions that are difficult to manage, such as Gorlin syndrome, has also been recognized.³²⁻³⁶ However, the application of conventional PDT¹⁰ is a laborious, time-consuming process for health professionals and patients alike and requires special equipment that takes up space in a clinic. The classic protocol¹⁰ specifies that the photosensitizer should be applied and kept covered (occlusion) for a certain period—usually 4 to 6 hours or more for 5-aminolevulinic acid (5-ALA) or 3 hours for the 5-ALA methylester, or methyl aminolevulinate (MAL). After incubation, the area is exposed to an appropriate source of light. The most common combinations of light sources and doses used in Europe are the Aktelite (Galderma, Lausanne, Switzerland) at 37 J/cm² for approximately 8 minutes and the Waldmann PDT 1200L (Waldmann GmbH & Co, Villingen-Schwenningen, Germany) at 75 to 100 J/cm² for approximately 20 minutes. PDT is not free of adverse effects.³⁷⁻⁴⁴ The most common one, and the most limiting, is pain during illumination, which must sometimes be interrupted; analgesia or local or regional anesthesia may be required.^{45,46}

With the use of portable light sources (Fig. 1) to optimize the procedure and facilitate outpatient treatment,⁴⁷⁻⁴⁹ the concept of ambulatory PDT has emerged.⁵⁰ This modality is costly, however, and is only useful for treating small lesions. The most important methodological simplification introduced in recent years has been the therapeutic use of daylight.^{51,52}

Daylight-Mediated PDT

Daylight PDT uses a combination of direct and reflected sunlight outdoors.⁵³ Using the sun as a light source has encouraged more widespread use of PDT, has lowered costs considerably, and has enhanced adherence.

Clinical Trials and Other Published Studies

The available publications are summarized in Table 1. Strasswimmer and Grande⁵⁴ suggested in 2006 that daylight could activate a photodynamic reaction, a claim that others disputed.⁵⁵ Batchelor and colleagues⁵¹ were the first to report the effective use of daylight PDT to treat multiple scalp AKs in a 90-year-old patient who showed good tolerance of the session. The most important work on this modality has been published since 2008 by the group of Wiegell and colleagues at Hospital Bispebjerg in Denmark. Most of their studies have enrolled patients with AK (Table 1). In a pilot study with 29 patients they initially demonstrated that daylight-mediated PDT was as effective against AKs as red-light PDT using a light-emitting diode as the source; daylight therapy was also much less painful.⁵² The authors suggested that progressive, slower activation of protoporphyrin IX [PpIX] by small amounts of the photosensitizer (rather than rapid activation of large amounts of PpIX in the target tissue after several hours of incubation) might reduce the pain associated with treatment; they also suggested that since red and blue light fall within the spectrum of daylight, this source might be effective in therapy and also facilitate treatment. The use of natural light, therefore, could theoretically be useful and enhance therapy. In a later study they compared the efficacy of daylight-mediated PDT using MAL at concentrations of 16% and 8%, observing no differences in response rates, grades of erythema or pain between patients using the different concentrations.⁵⁶ The authors suggested that MAL concentrations lower than the usual one of 16% could be effective. In 2011 they published the results of the first multicenter trial of daylight PDT in patients with nonhyperkeratotic AKs, finding that outcomes after exposures of 1.5 and 2.5 hours were similar.⁵⁷ The authors recommended a 2-hour exposure time. The 2 later studies confirmed the earlier findings that daylight PDT is effective in nonhyperkeratotic AK. However, this modality proved less effective on hyperkeratotic AK lesions.⁵⁸

Braathén⁵⁹ reported similar results for daylight PDT used to treat facial and scalp AKs in a series of 18 patients in a private practice setting.

The results of a multicenter randomized controlled trial in Australia were recently presented by Shumack and colleagues at the Euro-PDT meeting (the annual conference of the European Society for Photodynamic Therapy in Dermatology) in Madrid from May 31 to June 1, 2013. This study showed that daylight PDT was not inferior to conventional PDT and that it was better tolerated and preferred by both patients and the investigators. This study confirmed the findings of earlier ones done in Nordic settings^{52,56-58} and was the first undertaken in a country with a climate that is

Table 1 Characteristics of the Principal Studies of Daylight-Mediated PDT Treatment of AK.

	Wiegell et al. ⁵²	Wiegell et al. ⁵⁶	Wiegell et al. ⁵⁷	Wiegell et al. ⁵⁸	Braathen ⁵⁹	Shumack et al. ^a
Journal	BJD	BJD	BJD	BJD	ADV	Unpublished
Year of publication	2008	2009	2011	2012	2012	2012
Study design	Randomized, controlled, single blind	Randomized, double blind	Randomized, multicenter	Randomized, multicenter	Retrospective case series	Multicenter, randomized, blinded, within-patient controlled
Country	Denmark	Denmark	Denmark Norway Sweden	Denmark Norway Sweden	Switzerland	Australia
No. of participating centers	1	1	9	9	1	7
Objective	To compare conventional red-light PDT to daylight PDT without occlusion	To compare response rates and adverse events in daylight PDT with 8% or 16% MAL	To compare the efficacy of daylight PDT with MAL after 1.5 or 2.5 h of exposure	To assess the efficacy of PDT with MAL in AK of different levels of severity.	To assess the feasibility of, adherence to, and satisfaction with daylight PDT in private practice	To assess the noninferiority of daylight PDT and the maximum pain caused
Treatment season	June–Sept 2006	June–Sept 2007	June–Oct 2008	June–Oct 2008	April–Sept 2011	Mar–May 2012
Follow-up, mo	3	3	3	3	3	3
No. of treatment sessions	1	1	1	1	1	1
No. of cases	29	30	120	145	18	100
Age, y ^b	73 (63–90)	71 (51–94)	72 (47–95)	72 (47–95)	72 (60–85)	66.9 (42–90)
Sex, M/F	23/6	26/4	96/24	117/28	12/6	75/35
Grade of AK	I, II	I, II, III	I	II, III	I, II	I, II
Principal location	Face, scalp	Face, scalp	Face, scalp	Face, scalp	Face, scalp	Face, scalp
Surface area treated	80 cm ²	80 cm ²	At least 25 cm ²	At least 25 cm ²	1–10 AKs	8 × 18 cm

Table 1 (Continued)

	Wiegell et al. ⁵²	Wiegell et al. ⁵⁶	Wiegell et al. ⁵⁷	Wiegell et al. ⁵⁸	Braathen ⁵⁹	Shumack et al. ^a
Sunscreen	None	P20 (Riemann & Co A/S, Hilleroed, Denmark)	P20	P20	Louis Widmer F15 gel	SPF 30
Time between application of sunscreen and photosensitizer	NA	15 min	15 min	15 min	5–15 min	NS
Photosensitizing agent	MAL 16%	MAL 16%, MAL 8%	MAL 16%	MAL16%	MAL 16%	MAL 16%
Amount of photosensitizer or layer thickness	1 g	1 g	“Thick layer”	1-mm layer	Layer of 0.5–1 mm	NS
Photosensitizer incubation	30 min on the daylight PDT side; 3 h on the conventional PDT side	Wait of 0–120 min before sun exposure	≤ 30 min	≤ 30 min	30 min	≤ 30 min
Occlusion after photosensitizer application	Yes	No	No	No	No	No
Time of day for exposure	NS	11–18 h	8–18:30 h	NS	11–16 h	9–18 h
Exposure duration recommended	2.5 h	Rest of the day	1.5 h vs 2.5 h	1.5 h vs 2.5 h	90 min on a sunny day; 120 min on a partly cloudy or cloudy day	2 h
Light dose	Effective total exposure dose, 34.2 J/cm ² (range, 11.7–65.9 J/cm ²)	Mean effective dose, 30.1 J/cm ² (range, 1.2–69.8 J/cm ²)	Mean effective dose, 1.5 h, 8.6 J/cm ² ; in 2.5 h, 10.2 J/cm ²	100 patients received > 3.5 J/cm ² ; 37 patients received < 3.5 J/cm ²	NS	NS

Table 1 (Continued)

	Wiegell et al. ⁵²	Wiegell et al. ⁵⁶	Wiegell et al. ⁵⁷	Wiegell et al. ⁵⁸	Braathen ⁵⁹	Shumack et al. ^a
Weather conditions	Sunny or partly cloudy	3 patients exposed on cloudy or rainy days	Sunny or partly cloudy (83%); rainy or cloudy (17%)	Sunny or partly cloudy; rainy or cloudy	> 12 °C, on days without rain	Sunny/partly cloudy
Results at 3 mo ^c	79% reduction of AK in the treated area	76.9% reduction in number of AKs (MAL 16%); 79.5% (MAL 8%)	Mean response rates: after 1.5 h, 77.2%; after 2.5 h, 74.6%	Mean response rates: 75.9% in AK I; 61.2% in AK II; 49.1% in AK III	Mean response rate, 77% (range, 0%–100%)	82% reduction in AKs
Pain (scale 0–10)	Mean maximum pain, 2 (1.9)	MAL 16%, 3.7 (2.4); MAL 8%, 3.6 (2.4)	0–1, 92%; 4–7, 7.5%; 8–10, 0.8%	NS	1 patient, 5 out of 10; others, 0	Mean, 0.8
Other adverse effects	Erythema, crusting	Erythema, crusting	Erythema, 74%; pustules, 29%	NS	Erythema, edema, crusting	NS

Abbreviations: ADV, *Actas Dermo-sifiliográficas*; AK, actinic keratosis; BJD, *British Journal of Dermatology*; F, female; M, male; MAL, methyl aminolevulinate; Mar, March; NA, not applicable; NS, not specified; Oct, October; PDT, photodynamic therapy; Sept, September.

^a Unpublished study, presented at the Thirteenth Conference of the European Society for Photodynamic Therapy in Dermatology (Euro-PDT) in Madrid, May 31 to June 1, 2013.

^b Age is shown as mean (range).

^c Response rate refers to the number of lesions showing complete response divided by the number of lesions treated in each patient.

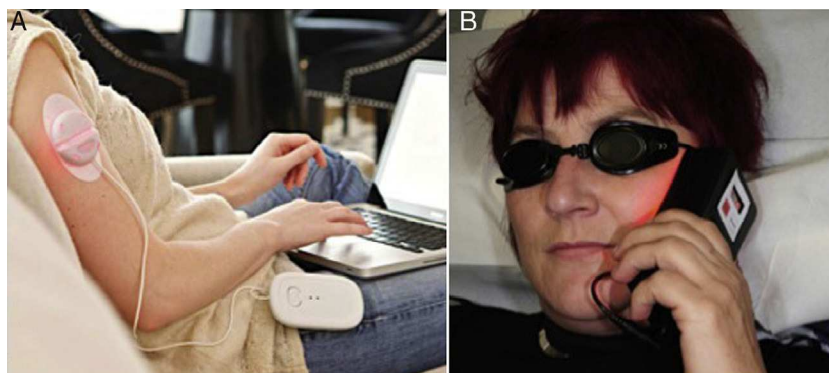


Figure 1 Ambulatory photodynamic therapy using portable light sources.⁵⁰ A, Ambulight (Ambicare Health Ltd, St Andrews, Fife, UK) (<http://www.ambicarehealth.com/ambulight-pdt/>). This device uses an adhesive patch with a red light emitting diode (LED)—peak emission 640 ± 25 nm—that delivers a dose of 75 J/cm^2 . Light intensity is low (7 mW/cm^2) and exposure lasts for 3 h.⁴⁹ Image used with the permission of Ambicare Health Ltd. B, AK-derm (Sellas GmbH, Ennepetal, Germany). High-intensity LED ($70\text{--}80 \text{ mW/cm}^2$) that emits 37 J/cm^2 in 8 min; peak emission is $630 \text{ nm} \pm 5 \text{ nm}$. Image used with permission of Dr Helger Stege (Klinikum Lippe, Detmold, Germany).

very different from that of northern Europe. The same conference brought together reports of other smaller trials of daylight PDT. In one study, Grinblat and colleagues used 1 to 3 sessions to treat 14 patients with grade I or II AKs. The setting was Brazil and exposure was performed between 9 AM and 11:30 AM for a period of 60 to 90 minutes. Most patients experienced improvement. In the Netherlands, Venema used daylight-mediated PDT to treat 2 patients with actinic cheilitis, observing good clinical and cosmetic results. Tolerance was excellent. Le Pillouer-Prost presented the findings of a French study of 17 patients with grade I to III AKs. Five of the patients had been pretreated with fractionated carbon dioxide laser therapy. After 1 or 2 sessions of daylight PDT, depending on lesion thickness, most AKs in the pretreated group had resolved. Lesions had also cleared in 10 of the 12 patients who had not been pretreated. Finally, Enk, described using this modality in 14 patients with nonulcerated cutaneous leishmaniasis in Israel. The patients were exposed to daylight in the hospital's garden for 2.5 hours immediately after application of MAL. The cure rate was 86% after an average of 5 weekly sessions. Scarring was minimal and the procedure was painless.

The main conclusions of the most important studies and a discussion of the details of the different approaches to this form of PDT can be found in a Euro-PDT consensus paper.⁵³

Treatment Protocol

The only treatment protocol currently available for daylight-mediated PDT was proposed by Wiegell and colleagues⁵⁷ and is summarized in Table 2. Considering that this PDT modality is at present off-label, the patient must be adequately informed about the procedure, its adverse effects, and efficacy. Written informed consent must be obtained. In order to assess the final outcome, baseline photographs of the area to be treated should be taken, and it may be useful to count and map the lesions in the field. Pretreatment with topical keratolytic agents may be advisable in some cases. Once the patient is in the treatment room, a sunscreen is applied to all exposed areas of the skin, even the area targeted for

treatment. The sunscreen should provide a sun protection factor (SPF) of at least 20 and not contain physical, or inorganic, filters. Approximately 15 minutes after sunscreen application, the lesions should be scraped with a curette. A layer of MAL cream approximately 1 mm thick is then spread on the field to be treated. Occlusion is not needed. The patient should be outdoors and start exposing the area to daylight within half an hour of MAL application. The recommended duration of exposure is 2 hours, after which the remaining photosensitizer is removed and the skin is cleaned. The treated field should be protected from sunlight the rest of the day. Sun protection measures should be continued for at least the next 48 hours.

Key Questions and Concerns

What Patients Are Candidates for Daylight-Mediated PDT?

This modality is mainly appropriate for cooperative patients who have multiple AKs (preferably grade I or II) or field cancerization in sun-exposed areas and who find conventional PDT to be very painful. Daylight PDT will probably gradually come to be used for skin diseases other than AK.

What Light Dose Is Needed for Effective Activation of PpIX?

The amount of irradiation received in 2 hours of direct sunlight at midday varies greatly according to geographic location, weather conditions, and season.⁶⁰ The threshold dose for PpIX activation (at which daylight PDT will be effective for destroying AKs) varies in studies published to date (8 , 6 , and 3.5 J/cm^2).^{53,57,58,60} Until the effective dose is established more precisely, a threshold of 8 J/cm^2 is currently considered adequate to ensure that therapy will be effective.⁶⁰ Using meteorological models and dosimeters installed at a number of geographic locations it has been possible to establish the effective light doses for activating PpIX in 2 hours of exposure at midday on the fifteenth day of each month at different latitudes.⁵³ Accordingly, it would be possible to reach daylight doses over 8 J/cm^2 in Spain in any month, depending on weather conditions; this

Table 2 Protocol for Daylight-Mediated PDT. ^a

Candidates for therapy	Patients with multiple AKs or field cancerization in sun-exposed areas.		
Treatment period	In Spain, all year long. ⁵³ In Nordic countries, April to October. ⁵⁷		
Weather conditions	Avoid rainy ⁵⁷ or very cloudy ⁶³ days.		
Procedure	Inside the hospital:	Apply a sunscreen (SPF \geq 15 on exposed skin). Scrape the lesions with a curette. Apply a photosensitizer (MAL), without occlusion, on the field to be treated. ^b	15 min
	Outside the hospital:	Expose skin to natural light. Remove remaining photosensitizer. Strict sun protection measures for 48 h.	2 h
No. of sessions	AK, 1 session; for other lesions, variable no. of sessions.		
Follow-up	Recommended: Examine the skin or contact the patient by telephone 24–48 h after treatment to check status; assess outcome 12 wk after treatment.		

Abbreviations: AK, actinic keratosis; MAL, methyl aminolevulinate; PDT, photodynamic therapy; SPF, sun protection factor.

^a Adapted from Wiegell et al.⁵⁷

^b The ideal thickness remains to be established. The prescribing information recommends a layer 1 mm thick. However Wulf and colleagues have reported using a thinner layer without loss of efficacy (Dr. H. C. Wulf, personal communication at the thirteenth annual conference of the European Society for Photodynamic Therapy in Dermatology [Euro-PDT], in Madrid, May 31 to June 1, 2013).

treatment could therefore be completed within the 2-hour time frame all year round⁵³ (Table 3).

How Should the Lesions Be Exposed to Daylight?

Exposure should take place outside in the middle of the day and last 2 hours.⁵⁷ However, Grinblat and colleagues (unpublished, Euro-PDT meeting) used shorter exposure times of 60 to 90 minutes and observed results that were similar to those of multicenter studies.^{57,58} Considering at the PpIX activation range corresponds to visible light, which passes through glass, Hospital Molholm in Vejle, Denmark, uses a glass structure to protect patients from certain weather conditions and increase comfort during exposure (Fig. 2).

What Period of the Year Is Most Appropriate for Daylight-Mediated PDT?

It seems to be possible to provide treatment at midday all year round in Spain unless there is a thick cloud cover.⁵³ Temperature may be a limiting factor, however, as studies in vitro and in mice suggest that low temperatures reduce PpIX production.^{60–62} Low temperatures also make it difficult for the patient to stay outside during exposure. A temperature range of 10 °C to 35 °C for daylight PDT has been recommended,⁶⁰ but there is room for variation according

to patient characteristics and exposure location. To date, no studies have demonstrated that there are differences in treatment efficacy outside this temperature range.

Wiegel and colleagues⁶⁰ a linear association between the UV index and the light dose that activates PpIX production during exposure at midday (11 AM to 1 PM) for 2 hours; when the UV index exceeds 3, patients receive over 8 J/cm² in this period. Weather conditions also play a part, as the effective daylight dose can decrease 25% on partly cloudy days, 50% on cloudy days, and 75% on rainy days.^{53,60} The exposure time required on such days has not been determined, and although some authors recommend not scheduling this modality of PDT on rainy⁵⁷ or very overcast⁶³ days, it would be useful to more precisely determine the required conditions for delivering the minimum effective light dose.

Why Is a Sunscreen Needed and What Sunscreen Is Appropriate for PDT?

The recommendation to use a sunscreen aims mainly to prevent the adverse effects of UV radiation during exposure to sunlight. Sunscreens used to date have varied in their SPF levels, ranging from SPF 15,⁵⁹ to SPF 20,^{53,57} to SPF 30 and SPF 50 (by Grinblat and colleagues and by Le Pillouer-Prost, respectively; unpublished reports, Euro-PDT meeting). Similar outcomes have been observed with all of

Table 3 Light Dose Received in 2 h of Exposure at Midday in the Middle of Each Month at the Range of Latitudes in Which Spain Is Included. ^a

Latitudes	Effective Light Dose in 2 h of Exposure on a Sunny Day, J/cm ²											
	Months											
	1	2	3	4	5	6	7	8	9	10	11	12
50 N	13	21	31	40	46	48	47	43	35	25	16	11
40 N	23	31	40	47	51	52	51	48	42	34	25	21
30 N	33	39	47	52	54	54	54	52	48	42	34	31

^a Spain extends from about the 30°N (Punta de Tarifa) to 43°47'N (Estaca de Bares). Columns show months by number. Months are expressed as numbers; 1 indicates January, 2 indicates February, etc. Adapted from Wiegell et al.⁵³



Figure 2 Greenhouse where the patient is exposed to daylight for photodynamic therapy at Hospital Molholm in Vejle, Denmark. Photograph kindly provided by Dr Peter Bjerring.

these sunscreens. It is important to use one that does not contain mineral filters, which might block the visible light necessary for PpIX activation in addition to UV radiation. A list of sunscreens appropriate for use in daylight-mediated PDT has been provided by the Spanish company Laboratorios Galderma SA. It includes the following products: from Laboratorios Uriage, Bariesun cream, SPF 30/50; from Laboratorios Ducray, Melascreen solar emulsion, SPF 50; from Laboratorios Eucerin, Sun Spray transparent, SPF 30/50; from Laboratorios Bioderma, AKN Mat SPF 30/UV-A 13, MAX cream, SPF 50+/UV-A 38 and AKN Spray SPF 30/UV-A13; and from Laboratorios ISDIN, a transparent SPF 30 gel-cream.

What Limitations Affect Daylight-Mediated PDT?

Daylight-mediated PDT is of great benefit for certain patients and for dermatologists who have neither the time nor the infrastructure for conventional PDT. However, there are certain limitations, such as the difficulty of scheduling sessions because of unpredictable weather and the constraints imposed by climate conditions in some geographic areas. At northern European latitudes, solar radiation is insufficient and temperatures are too low to accommodate sessions during some seasons (autumn and winter). Conditions in countries like Spain are different. It is still unclear whether very intense exposure for 2 hours at our latitudes might be risky for our patients, but the Australian clinical trial described above has shown that daylight-mediated PDT is effective and safe in countries with strong solar radiation. Another problematic issue is the lack of rigorous control

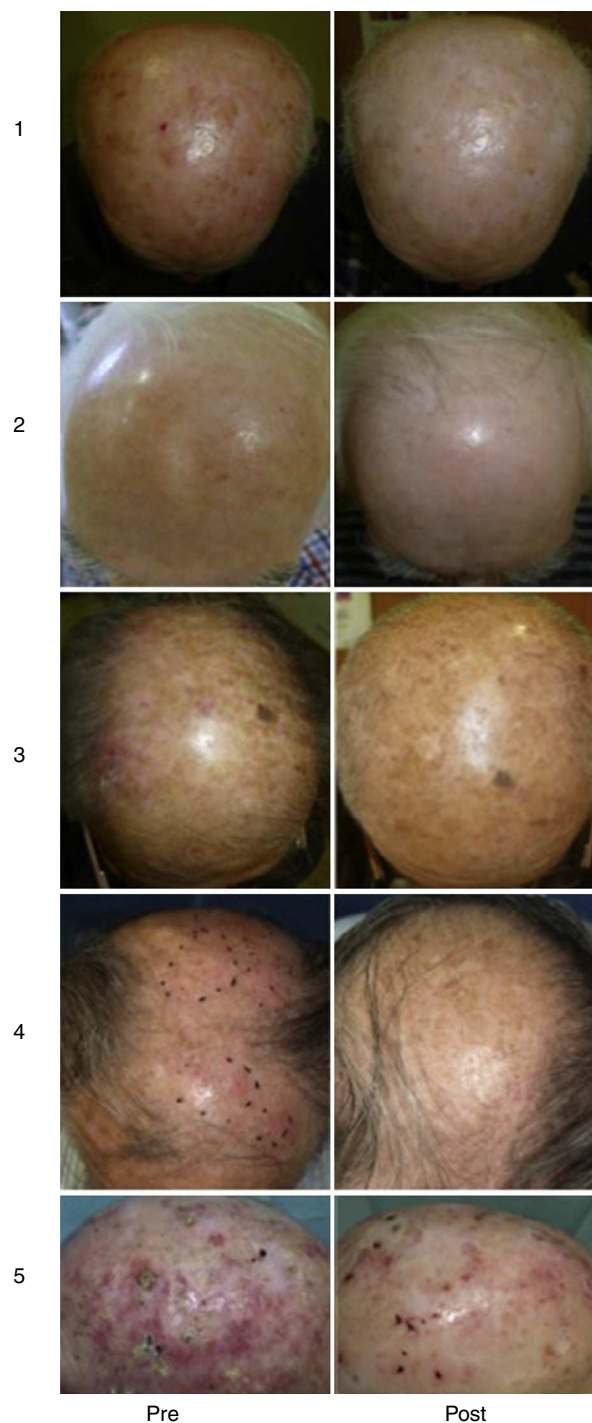

Figure 3 Results of treating multiple AKs with daylight photodynamic therapy (PDT). Photographs in the left column show lesions before treatment. Photographs on the right show the same lesions after treatment. Follow-up images in cases 1 to 3 (Complejo Hospitalario Universitario de Vigo, of the Integrated Management System in Vigo) were taken 3 mo after a single PDT session. Follow-up images in cases 4 and 5 (Hospital San Jorge, Huesca) were taken 8 mo after 1 PDT session and 4 mo after 2 PDT sessions, respectively.

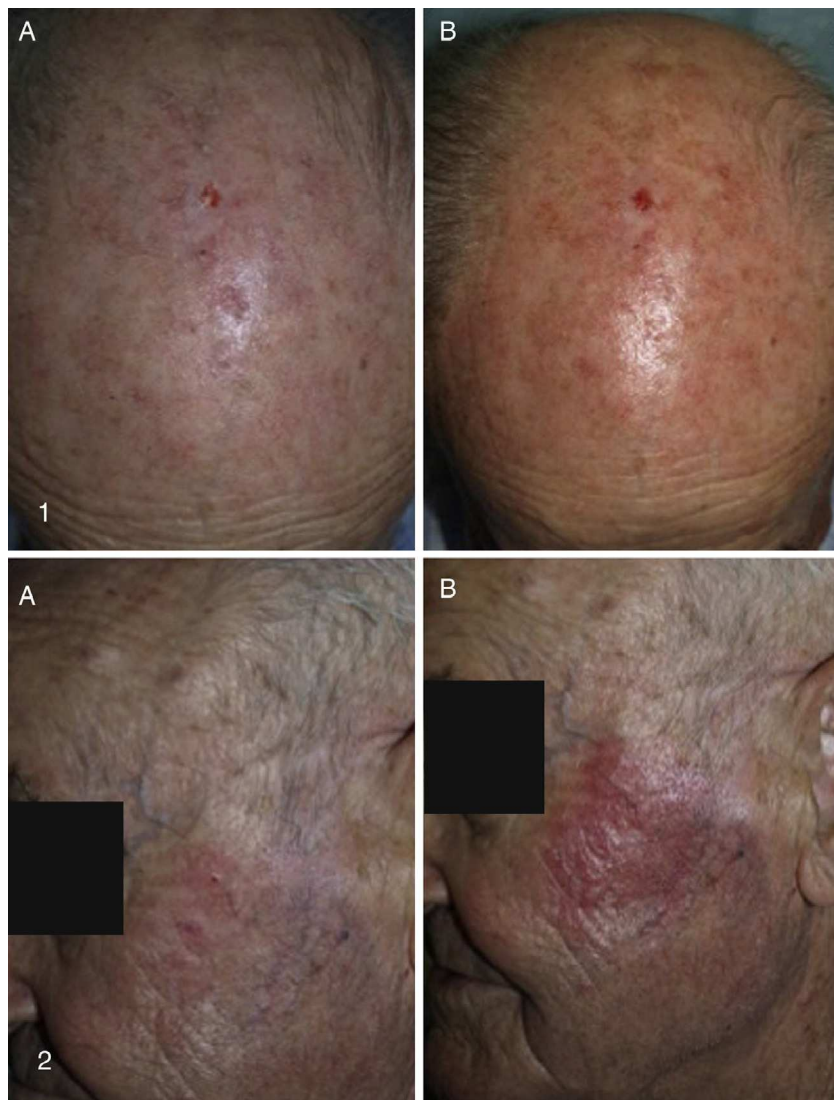


Figure 4 A, Baseline appearance of treated actinic keratosis lesions. B, Erythema and inflammation 3 h after treatment. The lesions in the upper photographs (1A and B) were treated with daylight photodynamic therapy (PDT). The lesions in the lower photographs (2A and B) were treated with conventional PDT. Photographs from Hospital San Jorge.

over therapy during the ambulatory outdoor period of the procedure, as the patient is the one who monitors illumination. To date, we still do not know the impact these possible differences might have on the effectiveness of therapy. In addition, daylight PDT seems to be less effective than conventional PDT for grade III AKs, and for the moment we lack sufficient evidence to support daylight-mediated PDT for other types of skin lesions. We expect to have new data in the future, however.

Our Hospital Departments' Experience

The dermatology services under the Integrated Management System in Vigo (at Complejo Hospitalario Universitario de Vigo [CHUVI] and Hospital San Jorge in Huesca [HSJ]) have used daylight-mediated PDT in 35 (CHUVI) and 9 (HSJ) patients with multiple grade I, II or III AKs, or field

cancerization. Lesions were located on the face and/or scalp (CHUVI and HSJ) or legs (HSJ). Most patients were treated in a single session, but some underwent 2 sessions (HSJ). The results (Fig. 3) were similar to those achieved with conventional PDT for grade I or II AKs but inferior for grade III AKs. The main adverse effects were inflammation and crusting in the treated area. These effects were less intense, however, than those usually seen after conventional PDT (Fig. 4). Patients treated in the CHUVI reported less pain (scores, 0–3 on a scale of 0 to 10) after daylight mediated PDT than after conventional PDT (scores, 6–10) Most patients who had previously undergone conventional PDT expressed a clear preference for the daylight-mediated modality. The use of this approach allowed us to schedule treatment more quickly and accommodate all of them. Daylight was particularly useful for treating CHUVI patients who lived outside the city, and this choice also considerably reduced the amount of time the CHUVI staff spent preparing and supervising therapy.

Conclusions

Daylight-mediated PDT is an important new modality in dermatology. It has proven to be as effective as conventional PDT for treating AK and is a technically simpler method. Tolerance of therapy has improved considerably with the use of natural light. Both patients and specialists often express a preference for daylight PDT because the ambulatory procedure is simple and easy to organize. However, important disadvantages are that it is difficult to schedule because of weather conditions at certain times of the year and because light exposure is difficult to control. Over time, this modality will probably begin to have applications in the treatment of skin conditions other than AK, as has occurred with conventional PDT in recent years.

Although a protocol for daylight-mediated PDT has been proposed⁵⁷ and an international consensus paper has been published,⁵³ many aspects remain speculative to a certain degree and need to be defined in the short-term so treatment can be fully standardized. Some of these aspects are the obligatory use of a sunscreen, the most appropriate SPF for this clinical use, the ideal amount and concentration of photosensitizer, whether occlusion is necessary, the effective daylight dose required for PpIX activation, the exact exposure time required at different times of day and in specific weather conditions, the real effect of ambient temperature on efficacy, and the possible use of photosensitizers other than MAL.

According to information available at this time, Spain has an ideal climate for providing daylight PDT all year round. Existing international treatment protocols are currently based on conditions in Nordic countries. In order to adapt them to other settings, a clinical trial is currently under way in several European countries, including Spain, and the results are expected to be available soon. The findings will help us establish optimal procedures for applying daylight PDT in Spain.

Conflicts of Interest

Dr Lidia Pérez has attended Spanish and international meetings about PDT at the invitation of Laboratorios Galderma SA; she was a speaker at the first meeting organized by that company on PDT in Galicia. Dr Yolanda Gilaberte has received consulting fees from Laboratorios Galderma SA; she has received fees for speaking for that company at various conferences.

Acknowledgments

We express thanks to Dr Stephen Schumack (St. George Dermatology and Skin Cancer Centre; Kogarah, Australia) for information about the Australian multicenter study on daylight-mediated PDT.

Thanks to Dr Beni Grinblat for information on results of his group's study of daylight-mediated PDT in Sao Paulo, Brazil.

Thanks to Dr Ann Le Pillouer-Prost for sending information about the study of daylight-mediated PDT in Marseille, France.

Thanks to Dr Helger Stege (Klinikum Lippe, Detmold, Germany) for providing information about the AK-Derm device and a photograph of it.

Thanks to Dr Peter Bjerring (Hospital Molholm, Vejle, Denmark) for his kind permission to use a photograph of the greenhouse used by his department.

References

- Morton CA, Szeimies RM, Sidoroff A, Braathen LR. European guidelines for topical photodynamic therapy part 1: Treatment delivery and current indications—actinic keratoses, Bowen's disease, basal cell carcinoma. *J Eur Acad Dermatol Venereol*. 2013;27:536–44.
- Morton CA, McKenna KE, Rhodes LE. British Association of Dermatologists Therapy Guidelines and Audit Subcommittee and the British Photodermatology Group. Guidelines for topical photodynamic therapy: Update. *Br J Dermatol*. 2008;159:1245–66.
- De Berker D, McGregor JM, Hughes BR. British Association of Dermatologists Therapy Guidelines and Audit Subcommittee, Guidelines for the management of actinic keratoses. *Br J Dermatol*. 2007;156:222–30.
- Braathen LR, Szeimies RM, Basset-Seguín N, Bissonnette R, Foley P, Pariser D, et al., International Society for Photodynamic Therapy in Dermatology. Guidelines on the use of photodynamic therapy for nonmelanoma skin cancer: An international consensus. *International Society for Photodynamic Therapy in Dermatology*, 2005. *J Am Acad Dermatol*. 2007;56:125–43.
- Gilaberte Y, Serra-Guillén C, de las Heras ME, Ruiz-Rodríguez R, Fernández-Lorente M, Benvenuto-Andrade C, et al. Terapia fotodinámica en dermatología. *Actas Dermosifiliogr*. 2006;97:83–102.
- Telfer NR, Colver GB, Morton CA. British Association of Dermatologists. Guidelines for the management of basal cell carcinoma. *Br J Dermatol*. 2008;159:35–48.
- Cox NH, Eedy DJ, Morton CA. Therapy guidelines and Audit Subcommittee, British Association of Dermatologists. Guidelines for management of Bowen's disease: 2006 update. *Br J Dermatol*. 2007;156:11–21.
- Tierney E, Barker A, Ahdout J, Hanke CW, Moy RL, Kouba DJ. Photodynamic therapy for the treatment of cutaneous neoplasia, inflammatory disorders, and photoaging. *Dermatol Surg*. 2009;35:725–46.
- Sidoroff A, Thaler P. Taking treatment decisions in non-melanoma skin cancer—the place for topical photodynamic therapy (PDT). *Photodiagnosis Photodyn Ther*. 2010;7:24–32.
- Christensen E, Warloe T, Kroon S, Funk J, Helsing P, Soler AM, et al. Guidelines for practical use of MAL-PDT in non-melanoma skin cancer. *J Eur Acad Dermatol Venereol*. 2010;24:505–12.
- Ulrich C. Topical treatment of field cancerization. *Cancer Treat Res*. 2009;146:439–46.
- Szeimies RM, Torezan L, Niwa A, Valente N, Unger P, Kohl E, et al. Clinical, histopathological and immunohistochemical assessment of human skin field cancerization before and after photodynamic therapy. *Br J Dermatol*. 2012;167:150–9.
- Morton CA. Can photodynamic therapy reverse the signs of photoaging and field cancerization? *Br J Dermatol*. 2012;167:2.
- Braathen LR, Morton CA, Basset-Seguín N, Bissonnette R, Geritsen MJ, Gilaberte Y, et al. Photodynamic therapy for skin field cancerization: An international consensus. *International Society for Photodynamic Therapy in Dermatology*. *J Eur Acad Dermatol Venereol*. 2012;26:1063–6.
- Morton CA, Szeimies RM, Sidoroff A, Braathen LR. European guidelines for topical photodynamic therapy part 2: Emerging indications—field cancerization, photorejuvenation and

- inflammatory/infective dermatoses. *J Eur Acad Dermatol Venereol.* 2013;27:672–9.
16. Morley S, Griffiths J, Philips G, Moseley H, O'Grady C, Mellish K, et al. Phase IIa randomized, placebo-controlled study of antimicrobial photodynamic therapy in bacterially colonized, chronic leg ulcers and diabetic foot ulcers: A new approach to antimicrobial therapy. *Br J Dermatol.* 2013;168:617–24.
 17. Calzavara-Pinton PG, Rossi MT, Sala R. Italian Group for Photodynamic Therapy. A retrospective analysis of real-life practice of off-label photodynamic therapy using methyl aminolevulinate (MAL-PDT) in 20 Italian dermatology departments. Part 2: Oncologic and infectious indications. *Photochem Photobiol Sci.* 2013;12:158–65.
 18. Aspiroz C, Fortuño-Cebamanos B, Rezusta A, Gilaberte Y. La terapia fotodinámica con metilaminolevulinato puede ser útil en el manejo de las infecciones por *Scytalidium*. *Actas Dermosifiliogr.* 2013;104:725–7.
 19. Gilaberte Y, Aspiroz C, Martes MP, Alcalde V, Espinel-Ingroff A, Rezusta A. Treatment of refractory fingernail onychomycosis caused by nondermatophyte molds with methylaminolevulinate photodynamic therapy. *J Am Acad Dermatol.* 2011;65:669–71.
 20. Calzavara-Pinton PG, Rossi MT, Aronson E, Sala R. Italian Group for Photodynamic Therapy. A retrospective analysis of real-life practice of off-label photodynamic therapy using methyl aminolevulinate (MAL-PDT) in 20 Italian dermatology departments. Part 1: Inflammatory and aesthetic indications. *Photochem Photobiol Sci.* 2013;12:148–57.
 21. Schweiger ES, Riddle CC, Aires DJ. Treatment of hidradenitis suppurativa by photodynamic therapy with aminolevulinic acid: Preliminary results. *J Drugs Dermatol.* 2011;10:381–6.
 22. Buggiani B, Troiano T, Rossi R, Lotti L. Photodynamic therapy: Off-label and alternative use in dermatological practice. *Photodiagnosis Photodyn Ther.* 2008;5:134–8.
 23. Guglielmetti A, Bedoya J, Acuna M, Leiva V, Gonzalez S. Successful aminolevulinic acid photodynamic therapy for recalcitrant severe hidradenitis suppurativa. *Photodermatol Photoimmunol Photomed.* 2010;26:110–1.
 24. Saraceno R, Teoli M, Casciello C, Chimenti S. Methyl aminolevulinate photodynamic therapy for the treatment of hidradenitis suppurativa and pilonidal cysts. *Photodermatol Photoimmunol Photomed.* 2009;25:164–5.
 25. Sotiriou E, Apalla Z, Maliamani F, Ioannides D. Treatment of recalcitrant hidradenitis suppurativa with photodynamic therapy: Report of five cases. *Clin Exp Dermatol.* 2009;34:e235–6.
 26. Fernández-Guarino M, Jaén-Olasolo P. Terapia fotodinámica en micosis fungoides. *Actas Dermosifiliogr.* 2013;104:393–9.
 27. Farias MM, Hasson A, Navarrete C, Nicklas C, Garcia-Huidobro I, Gonzalez S. Efficacy of topical photodynamic therapy for keratoacanthomas: A case-series of four patients. *Indian J Dermatol Venereol Leprol.* 2012;78:172–4.
 28. Nardelli AA, Stafinski T, Menon D. Effectiveness of photodynamic therapy for mammary and extra-mammary Paget's disease: A state of the science review. *BMC Dermatol.* 2011;11:13.
 29. Gold MH. Photodynamic therapy for cosmetic uses on the skin: An update 2010. *G Ital Dermatol Venereol.* 2010;145:525–41.
 30. Kohl E, Torezan LA, Landthaler M, Szeimies RM. Aesthetic effects of topical photodynamic therapy. *J Eur Acad Dermatol Venereol.* 2010;24:1261–9.
 31. Goldberg DJ. Photodynamic therapy in skin rejuvenation. *Clin Dermatol.* 2008;26:608–13.
 32. Wolfe CM, Green WH, Cognetta AB, Hatfield HK. A possible chemopreventive role for photodynamic therapy in Gorlin syndrome: A report of basal cell carcinoma reduction and review of literature. *Australas J Dermatol.* 2013;54:64–8.
 33. Wlodek C, Ali FR, Lear JT. Use of photodynamic therapy for treatment of actinic keratoses in organ transplant recipients. *Biomed Res Int.* 2013;2013:349526.
 34. Basset-Seguín N, Bissonnette R, Girard C, Haedersdal M, Lear JT, Paul C, et al. Consensus recommendations for the treatment of basal cell carcinomas in Gorlin syndrome with topical methylaminolevulinate-photodynamic therapy. *J Eur Acad Dermatol Venereol.* 2013 Apr 13. doi: 10.1111/jdv.12150.
 35. Basset-Seguín N, Baumann Conzett K, Gerritsen MJ, Gonzalez H, Haedersdal M, Hofbauer GF, et al. Photodynamic therapy for actinic keratosis in organ transplant patients. *J Eur Acad Dermatol Venereol.* 2013;27:57–66.
 36. Hasson A, Navarrete-Dechent C, Nicklas C, de la Cruz C. Topical photodynamic therapy with methylaminolevulinate for the treatment of actinic keratosis and reduction of photodamage in organ transplant recipients: A case-series of 16 patients. *Indian J Dermatol Venereol Leprol.* 2012;78:448–53.
 37. Halldin CB, Gonzalez H, Wennberg AM, Lepp M. Patients' experiences of pain and pain relief during photodynamic therapy on actinic keratoses: An interview study. *Acta Derm Venereol.* 2013;93:433–7.
 38. Attili SK, Dawe R, Ibbotson S. A review of pain experienced during topical photodynamic therapy—our experience in Dundee. *Photodiagnosis Photodyn Ther.* 2011;8:53–7.
 39. Ibbotson SH. Adverse effects of topical photodynamic therapy. *Photodermatol Photoimmunol Photomed.* 2011;27:116–30.
 40. Warren CB, Karai LJ, Vidimos A, Maytin EV. Pain associated with aminolevulinic acid-photodynamic therapy of skin disease. *J Am Acad Dermatol.* 2009;61:1033–43.
 41. Borroni RG, Carugno A, Rivetti N, Arbustini E, Brazzelli V. Risk of acute postoperative hypertension after topical photodynamic therapy for non-melanoma skin cancer. *Photodermatol Photoimmunol Photomed.* 2013;29:73–7.
 42. Miguélez A, Martín-Santiago A, Bauzá A, Gilaberte Y. Reacción urticariforme secundaria a terapia fotodinámica en 2 pacientes pediátricos. *Actas Dermosifiliogr.* 2013;104:727–9.
 43. Pastor-Nieto MA, Jiménez-Blázquez E, Sánchez-Herreros C, Belmar-Flores P. Dermatitis alérgica de contacto a metilaminolevulinato. *Actas Dermosifiliogr.* 2013;104:168–70.
 44. Buinauskaite E, Zalinkevicius R, Buinauskiene J, Valiukeviciene S. Pain during topical photodynamic therapy of actinic keratoses with 5-aminolevulinic acid and red light source: Randomized controlled trial. *Photodermatol Photoimmunol Photomed.* 2013;29:173–81.
 45. Serra-Guillen C, Hueso L, Nagore E, Vila M, Llombart B, Requena Caballero C, et al. Comparative study between cold air analgesia and supraorbital and supratrochlear nerve block for the management of pain during photodynamic therapy for actinic keratoses of the frontotemporal zone. *Br J Dermatol.* 2009;161:353–6.
 46. Halldin CB, Paoli J, Sandberg C, Gonzalez H, Wennberg AM. Nerve blocks enable adequate pain relief during topical photodynamic therapy of field cancerization on the forehead and scalp. *Br J Dermatol.* 2009;160:795–800.
 47. Zelickson B, Counters J, Coles C, Selim M. Light patch: Preliminary report of a novel form of blue light delivery for the treatment of actinic keratosis. *Dermatol Surg.* 2005;31:375–8.
 48. Attili SK, Lesar A, McNeill A, Camacho-Lopez M, Moseley H, Ibbotson S, et al. An open pilot study of ambulatory photodynamic therapy using a wearable low-irradiance organic light-emitting diode light source in the treatment of non-melanoma skin cancer. *Br J Dermatol.* 2009;161:170–3.
 49. Ibbotson SH, Ferguson J. Ambulatory photodynamic therapy using low irradiance inorganic light-emitting diodes for the treatment of non-melanoma skin cancer: An open study. *Photodermatol Photoimmunol Photomed.* 2012;28:235–9.
 50. Moseley H, Allen JW, Ibbotson S, Lesar A, McNeill A, Camacho-Lopez MA, et al. Ambulatory photodynamic therapy: A new concept in delivering photodynamic therapy. *Br J Dermatol.* 2006;154:747–50.

51. Batchelor RJ, Stables GI, Stringer MR. Successful treatment of scalp actinic keratoses with photodynamic therapy using ambient light. *Br J Dermatol.* 2007;156:779–81.
52. Wiegell SR, Haedersdal M, Philipsen PA, Eriksen P, Enk CD, Wulf HC. Continuous activation of PpIX by daylight is as effective as and less painful than conventional photodynamic therapy for actinic keratoses; a randomized, controlled, single-blinded study. *Br J Dermatol.* 2008;158:740–6.
53. Wiegell SR, Wulf HC, Szeimies RM, Basset-Seguín N, Bissonnette R, Gerritsen MJ, et al. Daylight photodynamic therapy for actinic keratosis: An international consensus: International Society for Photodynamic Therapy in Dermatology. *J Eur Acad Dermatol Venereol.* 2012;26:673–9.
54. Strasswimmer J, Grande DJ. Do pulsed lasers produce an effective photodynamic therapy response? *Lasers Surg Med.* 2006;38:22–5.
55. Marcus SL, Houlihan A, Lundahl S, Ferdon ME. Does ambient light contribute to the therapeutic effects of topical photodynamic therapy (PDT) using aminolevulinic acid HLC (ALA)? *Lasers Surg Med.* 2007;39:201–2.
56. Wiegell SR, Haedersdal M, Eriksen P, Wulf HC. Photodynamic therapy of actinic keratoses with 8% and 16% methyl aminolaevulinate and home-based daylight exposure: A double-blinded randomized clinical trial. *Br J Dermatol.* 2009;160:1308–14.
57. Wiegell SR, Fabricius S, Stender IM, Berne B, Kroon S, Andersen BL, et al. A randomized, multicentre study of directed daylight exposure times of 1½ vs 2½ h in daylight-mediated photodynamic therapy with methyl aminolaevulinate in patients with multiple thin actinic keratoses of the face and scalp. *Br J Dermatol.* 2011;164:1083–90.
58. Wiegell SR, Fabricius S, Gniadecka M, Stender IM, Berne B, Kroon S, et al. Daylight-mediated photodynamic therapy of moderate to thick actinic keratoses of the face and scalp: A randomized multicentre study. *Br J Dermatol.* 2012;166:1327–32.
59. Braathen LR. Daylight photodynamic therapy in private practice in Switzerland: Gain without pain. *Acta Derm Venereol.* 2012;92:652–3.
60. Wiegell SR, Fabricius S, Heydenreich J, Enk CD, Rosso S, Bäumlér W, et al. Weather conditions and daylight-mediated photodynamic therapy: Protoporphyrin ix-weighted daylight doses measured in six geographical locations. *Br J Dermatol.* 2013;168:186–91.
61. Juzeniene A, Juzenas P, Kaalhus O, Iani V, Moan J. Temperature effect on accumulation of protoporphyrin ix after topical application of 5-aminolevulinic acid and its methylester and hexylester derivatives in normal mouse skin. *Photochem Photobiol.* 2002;76:452–6.
62. Juzeniene A, Juzenas P, Bronshtein I, Vorobey A, Moan J. The influence of temperature on photodynamic cell killing in vitro with 5-aminolevulinic acid. *J Photochem Photobiol B.* 2006;84:161–6.
63. Wiegell SR, Heydenreich J, Fabricius S, Wulf HC. Continuous ultra-low-intensity artificial daylight is not as effective as red LED light in photodynamic therapy of multiple actinic keratoses. *Photodermatol Photoimmunol Photomed.* 2011;27:280–5.