

Pemphigus Herpetiformis With Progression to Pemphigus Foliaceus: A Case Report[☆]



Pénfigo herpetiforme con evolución a pénfigo foliáceo. Descripción de un caso

To the Editor:

Pemphigus herpetiformis (PH) is an uncommon variant of pemphigus that accounts for an estimated 6% to 7.2% of all cases of this skin disorder.^{1,2} The term *pemphigus herpetiformis* was coined by Jablonska et al.³ in 1975 to describe an entity that was clinically similar to dermatitis herpetiformis, showed acantholysis on biopsy, and responded to sulfapyridine. The authors considered that PH was a variant of pemphigus based on the direct immunofluorescence findings. PH typically presents with annular erythematous plaques, peripheral vesicles, and on occasions intense pruritus. Histologic features are highly variable and depend on the stage of the lesion. There have been reports of PH preceding or developing concurrently with pemphigus foliaceus (PF) or pemphigus vulgaris (PV).³⁻⁵ We present a case of PH that progressed to PF.

The patient, a 34-year-old woman with no relevant past history, consulted for erythematous papules and plaques with peripheral vesicles and blisters on the lower extremities, the abdomen, and the scalp (Fig. 1). The lesions had been present for 3 months. There was no mucosal involvement. Two biopsies revealed different degrees of neutrophilic and eosinophilic spongiosis (Fig. 2A) and acantholysis, with the formation of intraepidermal vesicles (Fig. 2B). Several eosinophils were also observed in the papillary dermis. Direct immunofluorescence showed intercellular immunoglobulin (Ig) G and C3 deposits, predominantly in the suprabasal layers of the epidermis. Anti-epithelial antibodies (titer, 1:40) and anti-desmoglein 1 (Dsg1) antibodies were positive (175 IU/mL; normal value, <20 IU/mL); the results for anti-Dsg1 antibodies were negative. A diagnosis of PH was made and treatment was started with prednisone 20 mg/d and topical clobetasol. The lesions improved, but 3 months later, erythematous scaling plaques started to reappear in the presternal, dorsal, and retroauricular areas and on the scalp (Fig. 3A). Biopsy of one of these plaques showed a subcorneal acantholytic vesicle (Fig. 3B). The anti-epithelial antibody titer was 1:80 and anti-Dsg1 antibody levels remained high at 161 IU/mL. Given the persistence of the lesions, treatment was started with dapson 50 mg/d, with dose increments up to 100 mg/d. The clinical response was favorable and the dose was progressively reduced to 12.5 mg every second day. Occasional flares consisting of minimal papules with scaling on the neckline, back, and scalp were observed.

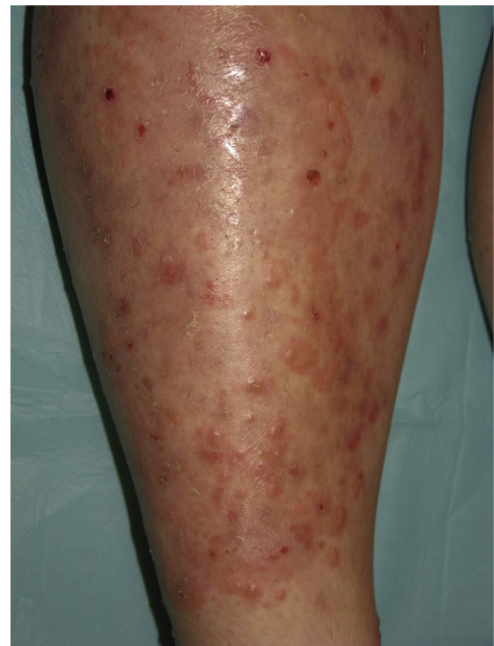

Figure 1 Erythematous papules and plaques with circinate borders and peripheral vesicles.

PH is a variant of pemphigus that generally has a good prognosis, and most patients respond to sulfones.⁵ PH has a wide spectrum of clinical and histologic findings and accordingly numerous autoimmune blistering disorders must be considered in the differential diagnosis, namely, dermatitis herpetiformis, linear IgA bullous dermatosis, PF, PV, and bullous pemphigoid.⁶ Histologic findings can vary according to the stage of the disease and the type of lesion biopsied. Varying degrees of neutrophilic and/or eosinophilic spongiosis, with or without acantholysis in the middle and/or subcorneal layer, are observed. Kuhn et al.⁷ found that the inflammatory infiltrate in patients with PH was 68% eosinophil-dominant, 16% neutrophil-dominant, and 16% mixed eosinophil/neutrophil. We would like to stress the importance of performing direct immunofluorescence to test for the presence of an autoimmune blistering disorder when histology reveals neutrophilic and/or eosinophilic spongiosis.

Anti-Dsg1 and/or anti-Dsg3 antibodies have been described in most cases of PH,^{5,8} but there have been isolated reports of negative results for both antibodies.⁹

We have described an atypical course of PH that has been previously reported by Maciejowska et al.¹ in 2 of 15 patients and by Santi et al.⁴ in 1 of 7 patients. There have also been reports of cases of PH developing after or at the same time as PF or PV.^{1,5} This possibility, together with the fact that anti-Dsg1 antibodies are detected in PH, has led to the hypothesis that PH and PF might be connected and that PH might actually be a variant of PF.⁴

It is not known why patients with PH, despite having anti-Dsg1 antibodies, have different clinical manifestations and histological findings to those with PF. Several hypotheses have been proposed. One is that in PH, IgG might cause keratinocytes to induce interleukin 8, whose chemotactic activity would explain the presence of a neutrophilic infiltrate.¹⁰ Another is that patients might develop anti-

[☆] Please cite this article as: Fuentes-Finkelstein P, Barnadas M, Gelpi C, Puig L. Pénfigo herpetiforme con evolución a pénfigo foliáceo. Descripción de un caso. *Actas Dermosifiliogr.* 2014;105:526-528.

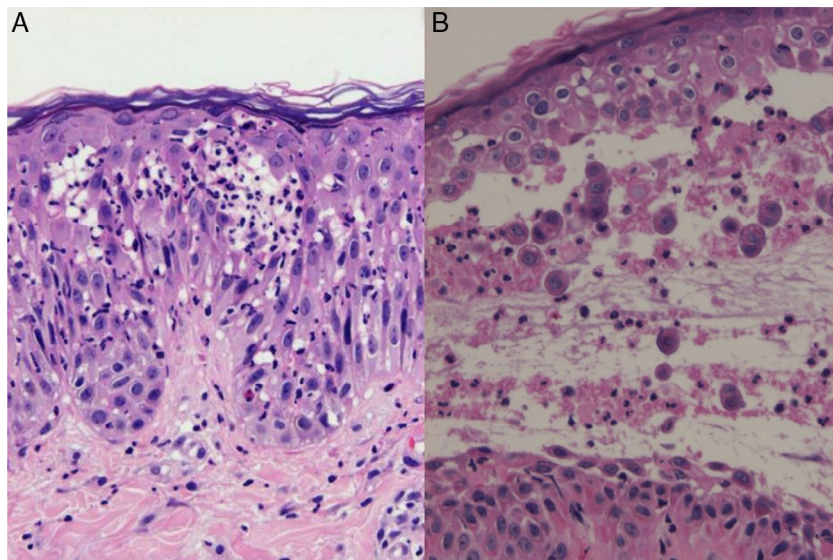


Figure 2 A, Neutrophilic spongiosis in the epidermis with isolated eosinophils (hematoxylin eosin, original magnification $\times 400$). B, Acantholytic vesicle in the middle layer of the epidermis accompanied by neutrophils and eosinophils.

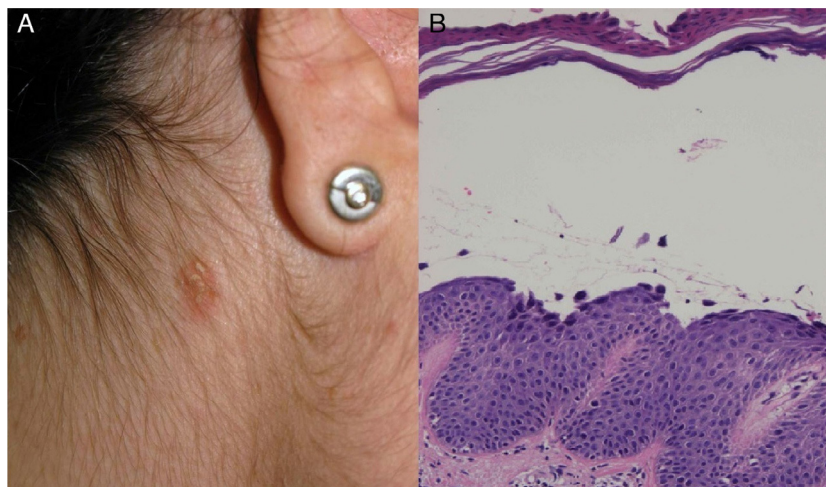


Figure 3 A, Erythematous scaling plaque in the retroauricular area. B, Acantholytic subcorneal vesicle (hematoxylin eosin, original magnification $\times 400$).

bodies that, despite their minimum acantholytic activity, could activate eosinophils and neutrophils through the Fc portion of IgG.⁵ Finally, it is possible that antibodies targeting epidermal antigens other than desmogleins or different epitopes might be responsible for the different phenotypic expression of pemphigus seen in PH.

References

1. Maciejowska E, Jablonska S, Chorzelski T. Is pemphigus herpetiformis an entity? *Int J Dermatol*. 1987;26:571–7.
2. Micali G, Musumeci ML, Nasca MR. Epidemiologic analysis and clinical course of 84 consecutive cases of pemphigus in eastern Sicily. *Int J Dermatol*. 1998;37:197–200.
3. Jablonska S, Chorzelski TP, Beutner EH, Chorzelska J. Herpetiform pemphigus a variable pattern of pemphigus. *Int J Dermatol*. 1975;14:353–9.
4. Santi C, Maruta C, Aoki V, Sotto M, Rivitti EA, Diaz LA. Pemphigus herpetiformis is a rare clinical expression of nonendemic pemphigus foliaceus, fogoselvagem and pemphigus vulgaris. *J Am Acad Dermatol*. 1996;34:40–6.
5. Lebeau S, Müller R, Masouyé I, Hertl M, Borradori L. Pemphigus herpetiformis: Analysis of the autoantibody profile during the disease course with changes in the clinical phenotype. *Clin Exp Dermatol*. 2010;35:366–72.
6. Robinson ND, Hashimoto T, Amagai M, Chan LS. The new pemphigus variants. *J Am Acad Dermatol*. 1999;40:649–71.
7. Huhn KM, Tron VA, Nguyen N, Trotter MJ. Neutrophilic spongiosis in pemphigus herpetiformis. *J Cutan Pathol*. 1996;23:264–9.

8. Ishii K, Amagai M, Komai A, Ebihara T, Chorzelski TP, Jablonska S, et al. Desmoglein 1 and desmoglein 3 are the target autoantigens in herpetic pemphigus. *Arch Dermatol.* 1999;135:943–7.
9. Nakashima H, Fujimoto M, Watanabe R, Ishiura N, Yamamoto AI, Hashimoto T, et al. Herpetiform pemphigus without anti-desmoglein 1/3 autoantibodies. *J Dermatol.* 2010;37:264–8.
10. O’Toole EA, Mak LL, Guitart J, Woodley DT, Hashimoto T, Amagai M, et al. Induction of keratinocyte IL-8 expression and secretion by IgG autoantibodies as a novel mechanism of epidermal neutrophil recruitment in a pemphigus variant. *Clin Exp Immunol.* 2000;119:217–24.

P. Fuentes-Finkelstein,^{a,*} M. Barnadas,^a C. Gelpi,^b L. Puig^a

^a *Servicio Dermatología, Hospital de la Santa Creu i Sant Pau, Barcelona, Spain*

^b *Servicio de Inmunología, Hospital de la Santa Creu i Sant Pau, Barcelona, Spain*

* Corresponding author.

E-mail address: pfuentesf@santpau.cat

(P. Fuentes-Finkelstein).

Onychomadesis and Pyogenic Granulomas After Postoperative Upper-Limb Immobilization[☆]



Onicomadesis y granulomas piogénicos tras inmovilización posquirúrgica de la extremidad superior

Numerous reports of nail disorders resulting from surgery can be found, particularly when prolonged limb immobilization is involved. We report the case of a patient with onychomadesis and pyogenic granulomas after immobilization of an arm with a plaster cast.

The only finding of note in the medical history of this 35-year-old man was allergy to penicillin and its derivatives. He attended the dermatology outpatient clinic because of a nail lesion that had first presented 2 months earlier. The physical examination revealed erythematous nodules with a vascular appearance in the proximal nail folds of the second and fourth fingers of the left hand, and complete proximal detachment from the nail plate on the second to fifth fingers of the same hand (Fig. 1). No contralateral lesions were present. Fever, pain, increased sweating, paresthesia, and other associated symptoms were absent. He had not had any previous infectious diseases or started taking new drugs. The patient had undergone surgery for distal detachment of the biceps brachii tendon and had had a plaster cast from halfway up the arm to the metacarpal joint. The lesions appeared approximately 2 weeks after removal of the plaster cast. The lesions resolved after 3 months without treatment. The patient was diagnosed with pyogenic-granuloma-associated onychomadesis after postoperative immobilization of his arm.

A range of nail disorders have been reported after surgery, particularly when the limb has been immobilized. In most cases, lesions can be considered a form of reflex sympathetic dystrophy, and can range from leukonychia, trachyonychia, Beau lines, edema, and watch-crystal nails.¹

Onychomadesis is the complete loss of the nail plate due to detachment at the proximal zone. It is usually the result of trauma, fever, infections, drugs, surgery, or peripheral ischemia.

Pyogenic granuloma is a benign eruptive hemangioma. When it appears in the nail apparatus, it is usually caused by mild penetrative lesions, friction, immobilization, or drugs such as antiretrovirals, cyclosporin, and chemotherapy.

The association of onychomadesis and pyogenic granuloma after limb immobilization with a plaster cast after surgery was reported in a series of 9 patients by Tosti et al.² in 2001. No other reports have been published in the literature to date. The authors believed that the nail disorders were caused by mild damage to the peripheral nerve after immobilization. All patients were men between 15 and 42 years old with a bone fracture requiring plaster-cast immobilization for 1 to 3 months. The lesions appeared between 7 and 30 days after removing the cast. Similar changes have been reported in patients with reflex sympathetic dystrophy.^{3,4} This condition is also accompanied by other clinical manifestations such as pain, vascular changes, excessive sweating, edema, and functional limitation.⁵ Atrophy and even skin ulcers may also be seen.⁶ These findings

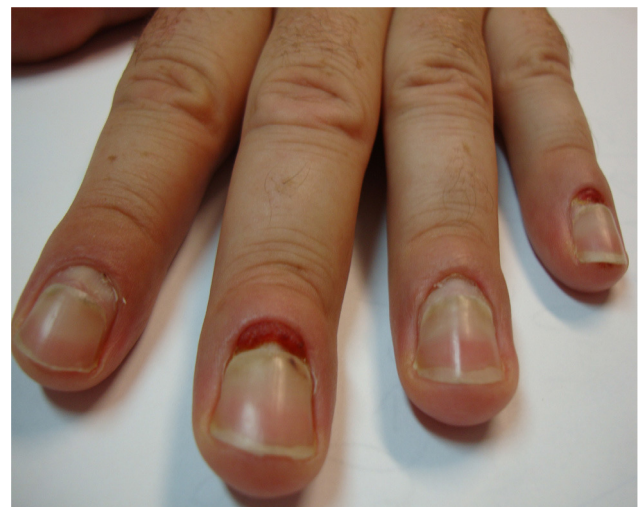

Figure 1 Pyogenic granulomas in the proximal nail fold of the second and fourth finger of the right hand and detachment of the nails of the second to fifth fingers.

[☆] Please cite this article as: Pampín A, Sanz-Robles H, Feltes RA, López-Estebanz JL. Onychomadesis y granulomas piogénicos tras inmovilización posquirúrgica de la extremidad superior. *Actas Dermosifiliogr.* 2014;105:528–529.