




ACTAS Derma-Sifiliográficas

Full English text available at
www.actasdermo.org



CASE AND RESEARCH LETTERS

Condyloma Acuminata in Male Patients. Are There Differences Between the Immigrant and Autochthonous Populations?☆



Condilomas acuminados en varones. ¿Existen diferencias entre población inmigrante y autóctona?

Immigration is a reality that cannot be ignored and that provides new professional challenges.¹ As a result, the number of publications related to immigration has increased markedly.^{2–7}

Among the skin conditions affected by immigration are sexually transmitted diseases, with some articles reporting a greater incidence of carriers of condyloma acuminata among immigrants.^{3–5}

The aim of this study was to answer the question posed by the title of this article, though any conclusions are clearly limited to the population actually studied.

We retrospectively included male patients with a clinical and histologic diagnosis of condyloma acuminata who were seen in the dermatology clinic of our hospital between February 18, 2008 and December 31, 2011.

We undertook chart review of these patients, and noted the following information: autochthonous or immigrant (including country of origin in the latter case), age, site/number/duration of lesions, presence of human papillomavirus (HPV) in skin lesions (using CLART Clinical Arrays from GENOMICA), associated sexually transmitted diseases, risky sexual practices, treatments received, and outcome.

In total, the medical records from 113 patients were retrieved. Of these patients, 93 (82%) were autochthonous and the rest were immigrants who had been living in Spain for at least 6 months. The origin of these patients was extremely varied (Table 1).

The remaining demographic information is presented in Table 2. There were no significant differences in terms of genital or perianal site of lesions. Two autochthonous patients had oral mucosal lesions.

☆ Please cite this article as: Díaz Díaz RM, Garrido Gutiérrez C, Navarro Cantero A, Ruiz Bravo-Burguillos E. Condilomas acuminados en varones. ¿Existen diferencias entre población inmigrante y autóctona? Actas Dermosifiliogr. 2014;105:519–520.

Table 1 Number and Country of Origin of Patients.

Year	Autochthonous Patients (Number of Patients)	Immigrant Patients (Number of Patients) and Country of Origin
2008	10	1 (Russia)
2009	18	3 (Ecuador 1, Paraguay 1, and Peru 1)
2010	42	8 (Bulgaria 2, Colombia 2, Morocco 2, Portugal 1, Rumania 1)
2011	23	8 (Morocco 4, Ecuador 1, Peru 1, Dominican Republic 1, Russia 1)

We did not find any differences between groups in terms of the presence of HPV as determined by the Clinical Arrays (GENOMICA) assay. The most frequent HPV serotypes were 6 and 11. An immigrant patient was positive for HPV 6 and an autochthonous patient was positive for HPV 61 and 81.

We found no differences in the type of treatment needed to control the lesions or whether monotherapy or combination therapy was administered. In both groups, the treatments used, from most frequent to least frequent, were cryotherapy, podophyllin, and topical imiquimod. Likewise, no differences were observed in terms of outcome for the 2 groups.

The analysis of articles related to an increase in sexually transmitted diseases in the immigrant population in Spain points to greater frequency of HPV infections among female immigrant prostitutes.³ However, this observation is not well established in male immigrants.^{4,6} Albares et al.,^{4,5} in studies in Spain, did not find any significant differences in patients with condyloma acuminata among immigrant and autochthonous populations, but they did not analyze men and women separately.

In our series, no differences were found between immigrant and autochthonous populations on comparing the characteristics of patients with condyloma acuminata, although immigrants tended to wait longer before seeking medical attention. This finding could be explained by a possible lack of awareness of the health system or cultural taboos concerning sexually transmitted diseases among male immigrants.

Table 2 Clinical and Epidemiological Characteristics.

	Autochthonous Population	Immigrant Population
Age at time of visit (most frequent 10-year age range)	19-65 years (20-30 and 30-40 years old)	19-53 years (20-30 and 30-40 years old)
Number of lesions	Single: 29 patients	Single: 3 patients
Duration of lesions	1 month to 7 years (6 patients more than 1 year)	1 month to 2 years (5 patients more than 1 year)
Risky sexual practices	28 patients (partner with condyloma, 7 cases)	5 patients (partner with condyloma, 1 case)
Associated STD	HIV ⁺ status in 1 patient Gonococcal urethritis, 1 patient Latent syphilis, 1 patient Active hepatitis B, 1 patient	Gonococcal urethritis, 1 patient Residual syphilis, 2 patients Previous hepatitis B, 2 patients

Abbreviations: HIV, human immunodeficiency virus; STD, sexually transmitted disease.

References

- Jansà JM, Garcia de Olalla P. Salud e inmigración: nuevas realidades y nuevos retos. *Gac Sanit.* 2004;18 Supl 1:207–13.
- De Eusebio Murillo E, Zambrano Centeno B, Jaén Ollaso P. Patología dermatológica en inmigrantes. *SEMERGEN.* 2004;30:345–55.
- Postigo C. Enfermedades de transmisión sexual e inmigración en España. *Actas Dermosifiliogr.* 2007;98:513–7.
- Porta N, San Juan J, Simai E, Baldellou R, Ara M, Zubiri ML. Análisis de la demanda asistencial de dermatología en la población inmigrante del área de salud del Hospital Miguel Servet de Zaragoza. *Actas Dermosifiliogr.* 2008;99:127–33.
- Albares Tendero MP, Belinchón Romero I, Ramos Rincón JM, Sánchez Payá J, Lucas Costa A, Pérez Crespo M, et al. Dermatosis en Latin American immigrants seen in a tertiary hospital. *Eur J Dermatol.* 2009;19:157–62.
- Taberner R, Nadal C, Llambrich A, Vila A, Torné I. Motivos de consulta dermatológica en la población inmigrante y española del área de salud del Hospital Son Llàtzer (Mallorca). *Actas Dermosifiliogr.* 2010;101:323–9.
- Albares MP, Belinchón I, Ramos JM, Sánchez Payá J, Betloch I. Estudio epidemiológico de la patología cutánea en la población inmigrante de Alicante. *Actas Dermosifiliogr.* 2012;103:214–22.

R.M. Díaz Díaz,^{a,*} C. Garrido Gutiérrez,^a
A. Navarro Cantero,^b E. Ruíz Bravo-Burguillos^b

^a Sección de Dermatología Hospital Universitario Infanta Sofía, San Sebastián de los Reyes, Madrid, Spain

^b Sección de Anatomía Patológica, Hospital Universitario Infanta Sofía, San Sebastián de los Reyes, Madrid, Spain

* Corresponding author.

E-mail addresses: rmaria.diaz@salud.madrid.org,
roadiadiaz@terra.es (R.M. Díaz Díaz).

Unresectable Angiosarcoma Treated With Bevacizumab and Paclitaxel[☆]



Angiosarcoma irresecable tratado con bevacizumab y paclitaxel

To the Editor:

Angiosarcoma is an aggressive tumor of endothelial origin that is associated with a poor prognosis. The effectiveness of new treatments such as bevacizumab is based on their ability to inhibit angiogenesis; specifically, bevacizumab acts on vascular endothelial growth factor (VEGF), which has been implicated in the pathogenesis of angiosarcoma.^{1,2}

[☆] Please cite this article as: Nespereira-Jato MV, Peña-Panabad C, Quindós-Varela M, García-Silva J. Angiosarcoma irresecable tratado con bevacizumab y paclitaxel. *Actas Dermosifiliogr.* 2014;105:520–522.

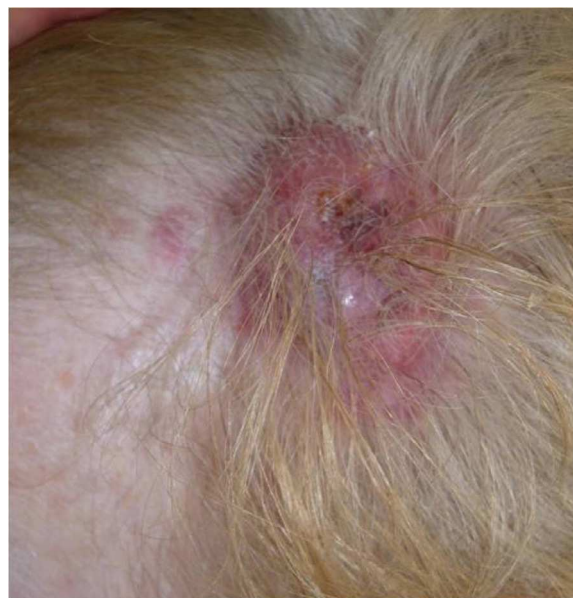

Figure 1 Erythematous violaceous tumor with a 4-cm diameter and peripheral macular lesions.