

5. Rubio Ruiz JM, Pérez Mena MA, Cirujano Pita F, Nieto Clemente IM, Marín-Blázquez MF, Salcedo Joven V. Atypical presentations of primary hypothyroidism in primary care. *Aten Primaria*. 1992;10:617–9.
6. Doshi DN, Blyumin ML, Kimball AB. Cutaneous manifestations of thyroid disease. *Clin Dermatol*. 2008;26:283–7.
7. Jabbour SA. Cutaneous manifestations of endocrine disorders: A guide for dermatologists. *Am J Clin Dermatol*. 2003;4:315–31.

M. Salazar-Nievas,^a S. Arias-Santiago^{b,*}

^a *Servicio de Dermatología, Hospital Universitario San Cecilio, Granada, Spain*

^b *Servicio de Dermatología, Hospital Virgen de las Nieves, Granada, Spain*

* Corresponding author.

E-mail address: salvadorarias@hotmail.es (S. Arias-Santiago).

Dyshidrosiform Linear Immunoglobulin A Dermatitis[☆]

Dermatitis Inmunoglobulina A lineal dishidrosiforme

Dyshidrosiform eruptions have a broad differential diagnosis.¹ Linear immunoglobulin (Ig) A dermatosis is a rare, autoimmune blistering disease that can be idiopathic or drug-induced,² and is characterized by a linear deposit of IgA in the epidermal basement membrane.^{3,4} We describe a case of linear IgA dermatosis that began as a dyshidrosiform eruption.

A 56-year-old woman presented at the emergency room with palmoplantar blisters and vesicles (Fig. 1) that were very painful and itchy and had appeared 24 hours previously. She was diagnosed with dyshidrosis. Several days later she developed blisters on the trunk and extremities, without mucosal involvement. A biopsy of one of the lesions was performed. Three weeks previously the patient had been treated for a urinary tract infection with oral fosfomicin, and had experienced diarrhea secondary to the antibiotic treatment. Laboratory tests, including indirect immunofluorescence analysis of antinuclear, antitransglutaminase, anti-intercellular adhesion, and anti-basement membrane antibodies, were normal. Histopathology revealed subepidermal blisters that contained a papillary dermal infiltrate consisting of abundant neutrophils and formed noneosinophilic microabscesses at the tips of the papillary ridges. Direct immunofluorescence (DIF) revealed linear

IgA deposition in the epidermal basement membrane, but no deposits of IgG or C3 (Fig. 2). Based on these findings the patient was diagnosed with linear IgA dermatosis. She responded well to treatment with oral prednisone with no recurrence within 6 months of stopping treatment.

While the initial appearance of palmoplantar vesicles and blisters suggested a diagnosis of dyshidrotic eczema, the subsequent appearance of lesions on the trunk and extremities was indicative of a blistering disease. Histopathology and the results of the DIF led to a diagnosis of linear IgA dermatosis.

Linear IgA dermatosis can be clinically and histologically similar to bullous pemphigoid and dermatitis herpetiformis.³ These 3 entities are characterized by subepidermal blister formation, an inflammatory infiltrate, and immunoglobulin deposition in the epidermal basement membrane. They can be distinguished by histological analysis and DIF. In dyshidrosiform pemphigoid the inflammatory infiltrate is composed mainly of eosinophils, and DIF shows a linear deposition of IgG and C3.⁵ Cases of IgA pemphigoid involving linear deposition of IgA and C3⁶ have also been reported. In dermatitis herpetiformis abundant neutrophils are observed at the tips of the dermal papillae and DIF shows granular deposition of IgA.⁵ In linear IgA dermatosis the inflammatory infiltrate is composed mainly of neutrophils, and DIF reveals linear IgA deposition in the epidermal basement membrane.⁵

It should be noted that although dyshidrosiform linear IgA dermatosis is rare, several cases have been reported.^{7,8}

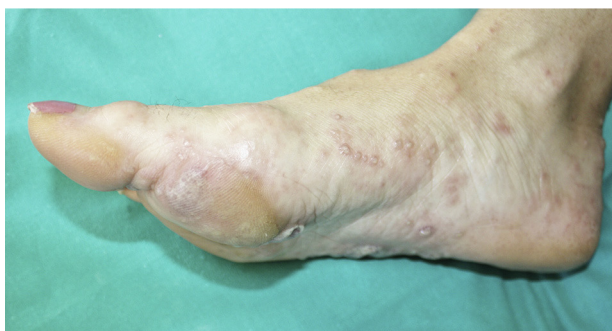

Figure 1 Palmoplantar vesicles of 24 hours duration.

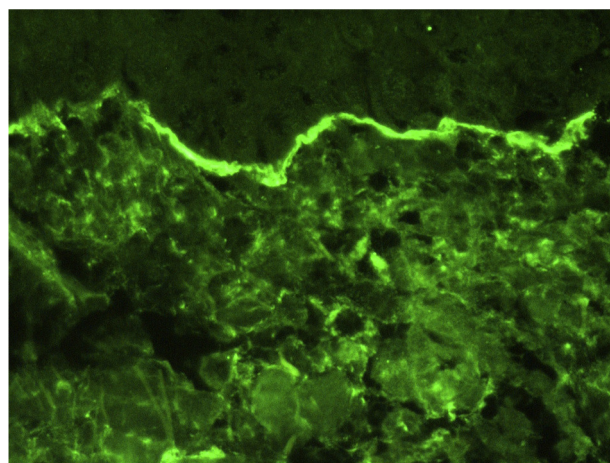


Figure 2 Direct immunofluorescence showing linear and homogeneous immunoglobulin A deposition.

[☆] Please cite this article as: Borja-Consigliere H, Ormaechea-Pérez N, Lobo-Morán C, Tuneu-Valls A. Dermatitis Inmunoglobulina A lineal dishidrosiforme. 2014;105:429–430.

Table 1 Differential Diagnosis of Dyshidrosiform Eruptions.

Infantile acropustulosis	Fixed drug eruption
Adult T-cell lymphoma	Friction blisters
Bullous impetigo	Pemphigus vulgaris
Dyshidrosiform pemphigoid	Polymorphic eruption of pregnancy
Linear immunoglobulin A dermatosis	Pustular psoriasis
Epidermolysis bullosa	SAPHO (Synovitis, Acne, Pustulosis, Hyperostosis, Osteitis) syndrome
Erythema multiforme	Scabies
Hand-foot-mouth syndrome	Subcorneal pustular dermatosis
Herpes infection	Small vessel vasculitis

Adapted from Wollina,¹ 2010.

This clinical form was first described in 1988 by Barth and coworkers,⁷ who reported 3 cases. Another case was later described by Duhra and colleagues.⁸ All 4 cases featured palmar involvement. Dyshidrosiform linear IgA dermatosis can be induced by drugs, most commonly vancomycin.^{2,9,10} While no association between fosfomicin and linear IgA dermatosis has been described, we cannot rule out the possibility that fosfomicin acted as a trigger in the present case. Treatment involves the administration of dapsone, together with corticosteroids in refractory cases.⁴

We have presented this case so that linear IgA dermatosis can be included within the broad differential diagnosis of dyshidrosiform eruptions (Table 1).¹

References

1. Wollina U. Pompholyx: A review of clinical features, differential diagnosis, and management. *Am J Clin Dermatol.* 2010;11:305–14.
2. Montagnac R, Reguiaï Z, Méhaut S, Bressieux JM, Schillinger F. Drug induced linear IgA bullous dermatosis. *Nephrologie.* 2003;24:287–92.

3. Chorzelski TP, Jablonska S. Diagnostic significance of the immunofluorescent pattern in dermatitis herpetiformis. *Int J Dermatol.* 1975;14:429–36.
4. Ingen-Housz-Oro S, Bernard P, Bedane C, Prost C, Joly P. Centres de référence des maladies bulleuses auto-immunes. Société Française de Dermatologie. Linear IgA dermatosis. Guidelines for the diagnosis and treatment. *Ann Dermatol Venerol.* 2011;138:267–70.
5. Campos-Domínguez M, Suárez-Fernández R, Lázaro-Ochaita P. Métodos diagnósticos en las enfermedades ampollas subepidérmicas autoinmunes. *Actas Dermosifiliogr.* 2006;97:485–502.
6. Mihályi L, Kiss M, Dobozy A, Kemény L, Husz S. Clinical relevance of autoantibodies in patients with autoimmune bullous dermatosis. *Clin Dev Immunol.* 2012;2012:369546.
7. Barth JH, Venning VA, Wojnarowska F. Palmo-plantar involvement in auto-immune blistering disorders-pemphigoid, linear IgA disease and herpes gestationis. *Clin Exp Dermatol.* 1988;13:85–6.
8. Duhra P, Charles-Holmes R. Linear IgA disease with haemorrhagic pompholyx and dapsone-induced neutropenia. *Br J Dermatol.* 1991;125:172–4.
9. Nousari HC, Kimyai-Asadi A, Caeiro JP, Anhalt GJ. Clinical, demographic, and immunohistologic features of vancomycin-induced linear IgA bullous disease of the skin. Report of 2 cases and review of the literature. *Medicine (Baltimore).* 1999;78:1–8.
10. Fortuna G, Salas-Alanis JC, Guidetti E, Marinkovich MP. A critical reappraisal of the current data on drug-induced linear immunoglobulin A bullous dermatosis: A real and separate nosological entity. *J Am Acad Dermatol.* 2012;66:988–94.

H.A. Borja-Consigliere,^{a,*} N. Ormaechea-Pérez,^a
C. Lobo-Morán,^b A. Tuneu-Valls^a

^a *Sección de Dermatología, Hospital Universitario Donostia, San Sebastián, Spain*

^b *Servicio de Anatomía Patológica, Hospital Universitario Donostia, San Sebastián, Spain*

* Corresponding author.

E-mail addresses: hborja@uc.cl, hernanborja@hotmail.com (H.A. Borja-Consigliere).

Allergic contact dermatitis due to acrylates in acrylic gel nails: a report of 3 cases[☆]

Dermatitis alérgica de contacto a acrilatos por uñas artificiales acrílicas: estudio de 3 casos

To the Editor:

Acrylates in artificial nails are a well-known cause of allergic contact dermatitis (ACD).¹ The recent emergence of photo-

bonded acrylic gel nails has resulted in a growing number of cases of ACD in both manicurists and clients.² As the number of beauty salons offering these new type of nails in Spain is increasing, we might soon see an increase in the incidence of ACD due to acrylates. We describe the case of 3 women, 2 manicurists and a client, with ACD induced by acrylic gel nails. The clinical presentation was different for each patient. Interestingly, 1 of the manicurists experienced an airborne reaction to nail sanding dust.

The epidemiological data, clinical manifestations, and patch test results are summarized in Table 1.

Patch tests were performed according to the International Contact Dermatitis Research Group criteria using the Spanish baseline series (T.R.U.E. TEST and allergEAZE) and an extended series of acrylates (Chemotechnique Diagnostics AB). Positive reactions were observed for 2-hydroxyethyl methacrylate (2-HEMA) and ethylene glycol dimethacrylate

[☆] Please cite this article: Vázquez-Osorio I, Espasandín-Arias M, García-Gavín J, Fernández-Redondo V. Allergic contact dermatitis due to acrylates in acrylic gel nails: a report of 3 cases. *Actas Dermosifiliogr* 2014;105:430–432.