

CASE AND RESEARCH LETTERS

Unilesional Mycosis Fungoides: 3 Different Clinical Presentations[☆]

Micosis fungoide unilesional: 3 formas clínicas de presentación

Mycosis fungoides (MF) is the most common cutaneous T-cell lymphoma, and accounts for more than half of all primary cutaneous T-cell lymphomas. Diagnosis of this condition is based on clinical and histopathological criteria. MF is one of several dermatological conditions that can mimic other diseases; its many clinical presentations include the unilesional form, first described by Jones and Chu.¹ Here, we

describe 3 different clinical manifestations of unilesional MF: a red scaly plaque, a purpuric lesion, and a tumor of elastic consistency.

The first patient was a 75-year-old woman with a history of hypothyroidism, endometrial adenocarcinoma, ovarian cyst, hypertension, cataracts, and bipolar disorder. She was being treated with levothyroxine sodium, lamotrigine, venlafaxine, and lithium carbonate. She presented with a round, erythematous plaque of about 5 cm in diameter with fine scales. The plaque was located in the interscapular area and had appeared about 6 months previously.

Skin biopsy showed a prominent band-like lymphocytic infiltrate with atypical cells exhibiting marked epidermotropism. Immunohistochemical staining was positive for

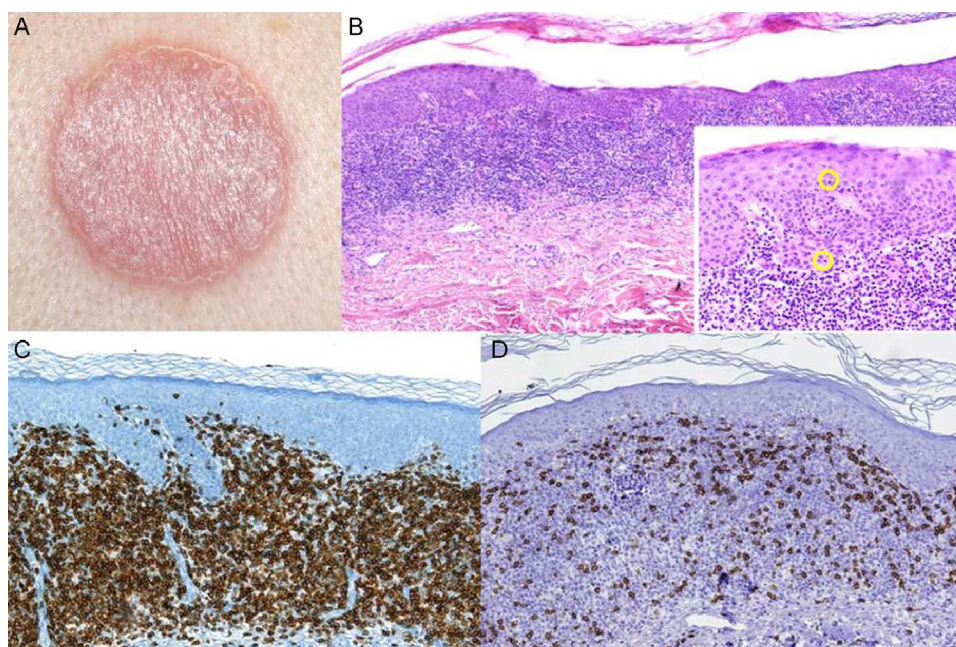


Figure 1 A, Erythematous plaque in the interscapular region. B, Skin biopsy revealed a band-like lymphocytic infiltrate with clear epidermotropism (hematoxylin-eosin, original magnification $\times 4$). Lymphocytes with halos can be seen permeating the epidermis (hematoxylin eosin, original magnification $\times 20$). C and D, Immunohistochemical staining demonstrating the predominance of CD4+ T lymphocytes.

[☆] Please cite this article as: Otero Rivas MM, Sánchez Sambucety P, Valladares Narganes LM, Rodríguez Prieto MA. Micosis fungoide unilesional: 3 formas clínicas de presentación. Actas Dermosifiliogr. 2014;105:420–424.

Table 1 Main Conditions Included in the Differential Diagnoses of Unilesional Mycosis Fungoides.

	Unilesional Mycosis Fungoides	Woringer-Kolopp Disease	Cutaneous T-Cell Lymphoid Hyperplasia	Cutaneous CD4 ⁺ Small/Medium-Sized Pleomorphic T-Cell Lymphoma	Indolent CD8 ⁺ Lymphoid Proliferation of Acral Sites
Clinical features	Single erythematous plaque on chest or abdomen	Violaceous and hyperkeratotic acral plaque	Single nodule Idiopathic/secondary to drug administration, arthropod bites, or vaccination	Plaque or tumor on the neck, face, or trunk	Single nodule on the face
Histology	Atypical lymphoid infiltrate with marked epidermotropism Possible adnexal involvement	Psoriasiform hyperplasia of the epidermis Atypical lymphoid cells with disproportionate epidermotropism Few lymphoid cells in the dermis	Two variants: nodular and mycosis fungoides-like Increased number of histiocytoid cells Epidermotropism is absent (nodular form) or less intense No loss of T-cell markers detected	Nodular infiltrate of small T cells (fewer than 30% large cells) Can affect subcutaneous tissue Epidermotropism uncommon Some cases involve abundant accompanying B cells	Monomorphic lymphocytic infiltrate in the dermis. Fewer than 5% large cells
Most common phenotype	CD4 ⁺ , CD8 ⁻	CD8 ⁺ , CD4 ⁻ Some cases of CD8 ⁻ CD4 ⁻	Mycosis fungoides-like: CD4 ⁺ , CD8 ⁻ Nodular pattern: CD4 ⁺ with accompanying CD8 ⁺ and CD20 ⁺ population	CD4 ⁺ , CD8 ⁻	CD8 ⁺ , CD4 ⁻
Clonality Treatment	Mostly monoclonal TCR Radiotherapy, surgery, topical therapy (e.g., corticosteroids, imiquimod, nitrogen mustards, carmustine)	Mostly monoclonal TCR Radiotherapy, surgery	Usually polyclonal TCR Elimination of trigger, surgery, topical corticosteroids	Mostly monoclonal TCR Surgery and/or adjuvant radiotherapy	Mostly monoclonal TCR Radiotherapy, surgery
Prognosis	Indolent course, good prognosis Local recurrence in some cases	Indolent course, good prognosis	Good prognosis, disappears after elimination of trigger	Generally indolent course with local recurrence Cases of spontaneous resolution described	Local recurrence in some cases No systemic spread

Abbreviations: TCR, T-cell receptor.

Adapted from Ally et al., 2012.⁷

CD4⁺ lymphocytes. Gene rearrangement analysis identified monoclonal populations of T-cell receptor (TCR) γ and TCR β . Analysis of tumor spread by laboratory tests, flow cytometry, and chest x-ray was negative. After diagnosis of unilesional MF it was decided to treat the patient with topical steroids (0.05% clobetasol propionate ointment 2 times per day for 2 months) and phototherapy. Follow-up over 16 months revealed postinflammatory hyperpigmentation with no signs of recurrence (Fig. 1).

The second patient was a 60-year-old man who was being treated for hypertension with valsartan. The patient presented with an asymptomatic, purpuric plaque measuring 2 \times 3 cm that had been present in the lumbosacral region for over a year. Skin biopsy showed an atypical lymphocytic infiltrate that was arranged in a band beneath an orthokeratotic epidermis and mixed with abundant extravasated erythrocytes. The infiltrate was clearly epidermotropic; numerous lymphocytes with halos were observed permeating the epidermis. These lymphocytes were identified by immunohistochemistry as CD4⁺; no loss of other T-cell markers (CD3⁺, CD5⁺, CD7⁺) was observed. As in the previous case, analysis of tumor spread was negative. The patient was diagnosed with unilesional purpuric MF. Clonality analysis was not performed. The patient was prescribed local treatment with 0.05% clobetasol propionate ointment daily for 2 months with subsequent clinical follow-up. The lesion resolved completely with no recurrence detected during 12 months of follow-up (Fig. 2).

The third patient was a 53-year-old woman with no relevant past medical history. She consulted for an asymptomatic, fleshy tumor with an elastic consistency on her left shoulder. Skin biopsy revealed an infiltrate of atypical lymphocytes along the dermal-epidermal junction and the follicular epithelium, with epidermotropism and folliculotropism. Immunohistochemistry was positive for CD20 and CD4; no loss of other T-cell markers was detected. Analysis of tumor spread confirmed that the disease was localized. The final diagnosis was follicular unilesional MF with intense B-cell infiltration. Gene rearrangement analysis revealed the presence of monoclonal populations of TCR γ and TCR β cells. Given the poor prognosis of patients with MF and folliculotropism who are treated with topical therapy, it was decided to excise the lesion with margins. No recurrence was observed during 12 months of follow-up (Fig. 3).

We have reported 3 cases of unilesional MF, a condition that is well described in the literature but often overlooked in the clinic due to its unremarkable clinical presentation. It is characterized by a single lesion covering less than 5% of the total body surface area² and its clinical features are as heterogeneous as those of the classical form; the literature describes purpuric, hypopigmented, follicular, and granulomatous forms, and patches of desquamative erythema, among other manifestations.³ However, its histopathological features are comparable with those of the classical form. Prognosis is excellent due to the low tumor burden; only 2

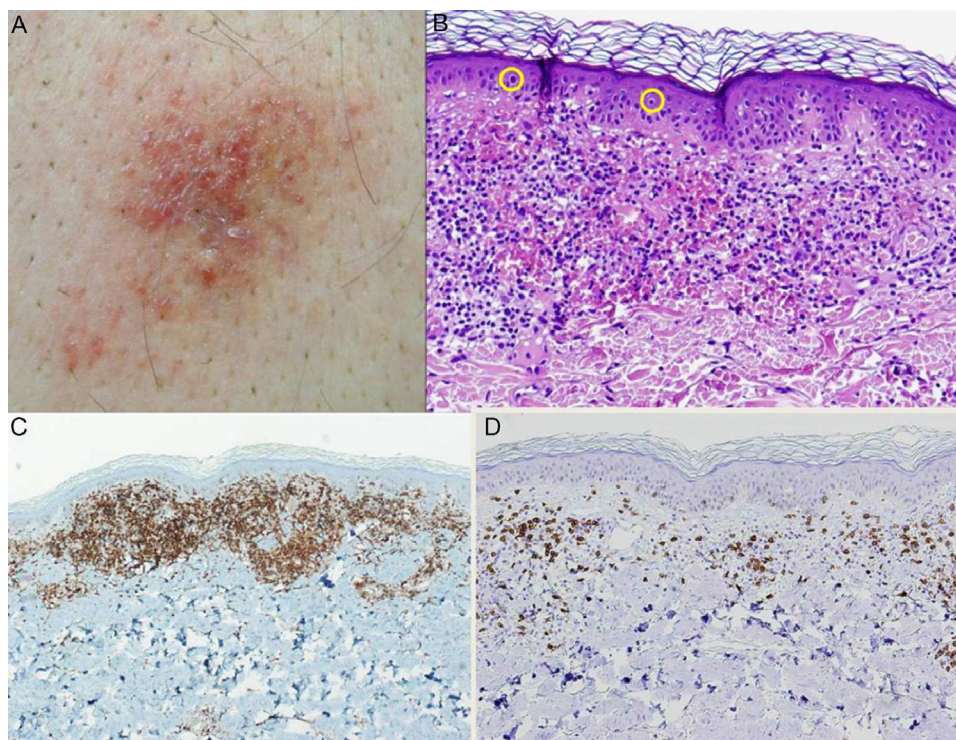


Figure 2 A, Purpuric plaque in the lumbosacral region. B, Staining with hematoxylin-eosin (original magnification $\times 20$) showed significant erythrocyte extravasation and numerous lymphocytes with halos in the epidermis. C, Predominance of CD4⁺ lymphocytes in the inflammatory infiltrate (original magnification $\times 10$). D, Note the scarcity of CD8⁺ lymphocytes (original magnification $\times 10$).

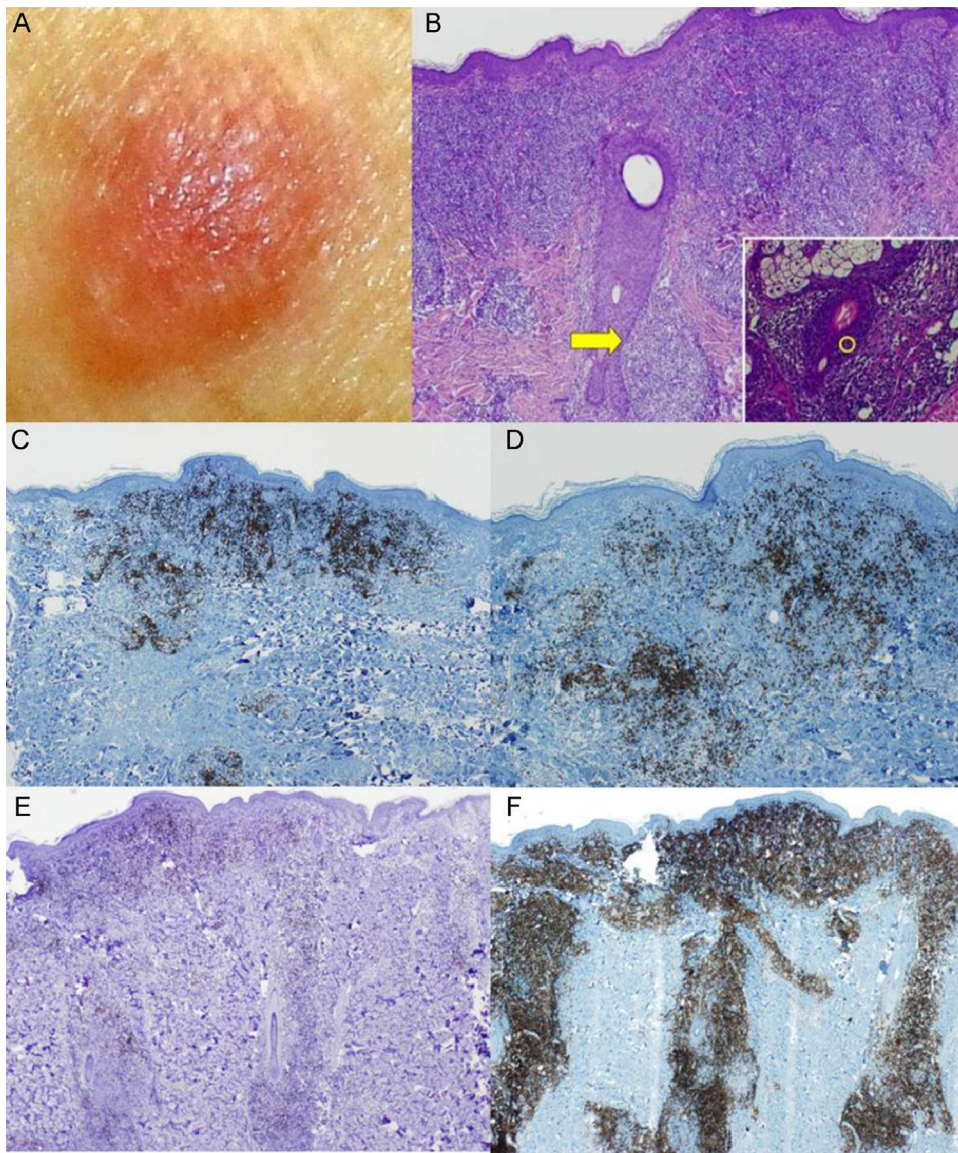


Figure 3 A, Fleshy, skin-colored tumor. B, Biopsy showed an epidermal folliculotropic infiltrate (hematoxylin eosin, original magnification $\times 4$) and lymphocytes permeating the follicle (inset: hematoxylin eosin, original magnification $\times 40$). C and D, Immunohistochemical staining showed abundant B cells (CD20⁺ and CD79⁺; original magnification $\times 4$). E and F, The lymphocytic infiltrate was composed almost entirely of CD4⁺ lymphocytes that surrounded the hair follicles.

cases of tumor progression are described in the literature, both involving follicular variants.²

The differential diagnosis should include Kolopp Woringer disease (a variant of MF also known as pagetoid reticulosis), cutaneous lymphoid hyperplasia, cutaneous CD4⁺ small/medium-sized pleomorphic T-cell lymphoma, and the recently described indolent CD8⁺ lymphoid proliferation of acral sites.⁴ All are entities that require a close clinicopathologic correlation, and immunohistochemistry is essential (Table 1).

In addition to an initial staging examination to rule out minimally symptomatic cutaneous T-cell lymphoma, appropriate clinical follow-up with periodic skin tests is required to assess the possible progression to classic MF.

There are various therapeutic approaches to unilesional MF, all of which target the skin with curative intent. Fractionated radiotherapy is the treatment best supported by the literature, and is well tolerated with few adverse effects.^{5,6} Surgical excision is a good alternative.⁷ Topical treatments range from potent corticosteroids to calcineurin inhibitors, imiquimod, carmustine, and nitrogen mustards.

In conclusion, we have presented 3 cases of unilesional MF, a frequently underdiagnosed clinicopathologic entity. Despite the excellent prognosis of this condition, an appropriate tumor staging analysis should be performed and the patient monitored to rule out progression to more extensive forms.

References

1. Jones RR, Chu A. Pagetoid reticulosis and solitary mycosis fungoides: distinct clinicopathological entities. *J Cutan Pathol.* 1981;8:40–51.
2. Kempf W, Kazakov DV, Schermesser M, Buechner SA, Parmentier L, Wysocki A, et al. Unilesional follicular mycosis fungoides: Report of two cases with progression to tumor stage and review of the literature. *J Cutan Pathol.* 2012;39:853–60.
3. Sáenz de Santa María MC, Zubiri ML, Yus C. Micosis fungoide granulomatosa unilesional. *Actas Dermosifiliogr.* 2002;93:178–80.
4. Petrella T, Maubec E, Cornillet-Lefebvre P, Willemze R, Pluot M, Durlach A, et al. Indolent CD8-positive lymphoid proliferation of the ear: A distinct primary cutaneous T-cell lymphoma? *Am J Surg Pathol.* 2007;31:1887–92.
5. Micaily B, Miyamoto C, Kantor G, Lessin S, Rook A, Brady L, et al. Radiotherapy for unilesional mycosis fungoides. *Int J Radiat Oncol Biol Phys.* 1998;42:361–4.
6. Chan DV, Aneja S, Honda K, Carlson S, Yao M, Katcher J, et al. Radiation therapy in the management of unilesional primary cutaneous T-cell lymphomas. *Br J Dermatol.* 2012;166:1134–7.
7. Ally MS, Pawade J, Tanaka M, Morris S, Mitchell T, Child F, et al. Solitary mycosis fungoides: A distinct clinicopathologic entity with a good prognosis. *J Am Acad Dermatol.* 2012;67:737–44.

M.M. Otero Rivas,* P. Sánchez Sambucety, L.M. Valladares Narganes, M.Á. Rodríguez Prieto

Servicio de Dermatología, Complejo Asistencial Universitario de León, León, Spain

* Corresponding author.

E-mail addresses: motero@aedv.es, acuviel@hotmail.com

(M.M. Otero Rivas).

Squamous cell carcinoma in an immunosuppressed patient on voriconazole[☆]

Carcinoma espinocelular en un paciente inmunosuprimido en tratamiento con voriconazol

To the Editor:

Voriconazole is a second-generation triazole antifungal agent that inhibits the enzyme cytochrome P450, which is required for the synthesis of ergosterol, a sterol that maintains the integrity of the fungal cell wall.^{1,2} In 2002 voriconazole was approved by the US Food and Drug Administration for the treatment of serious fungal infections including those caused by *Fusarium* and *Aspergillus* species.¹ The main adverse effects of voriconazole are visual disturbances, elevated transaminase levels, gastrointestinal upset, and skin rashes, including photosensitivity, cheilitis, and xerosis.^{3,4} Prolonged use has been associated with the development of liver spots, actinic keratoses, squamous cell carcinoma (SCC), and even cutaneous melanoma.¹ Most of the patients who develop SCC are immunocompromised (bone marrow, stem cell, or lung transplant recipients).^{5,6}

We describe the case of a 30-year-old man with Fitzpatrick skin phototype II and low sun exposure who had been diagnosed with cystic fibrosis. In 1998, at the age of 17, he underwent a double lung transplant. He was prescribed immunosuppressive therapy with tacrolimus, prednisone, and mycophenolate mofetil. In 2007, the patient underwent a right lower lobectomy for tuberculosis and pulmonary

aspergillosis and began antifungal treatment with voriconazole. In 2011, after 3 years of treatment with voriconazole, he developed a fast-growing nodule in the left parietal region and multiple actinic keratoses on the rest of the scalp (Fig. 1). The tumor was excised by Mohs micrographic surgery and closed using a full-thickness skin graft. Histology revealed a moderately differentiated SCC (Fig. 2) with tumor-free margins. Voriconazole treatment was discontinued once the diagnosis was confirmed. Three months later, the patient developed a recurrence in the left parietal region, near the skin graft (Fig. 3). As tumor adhesion to the cortex was observed during resection of the lesion, the periosteum was excised and an osteotomy of the outer table performed. Weeks later, the patient developed left and right

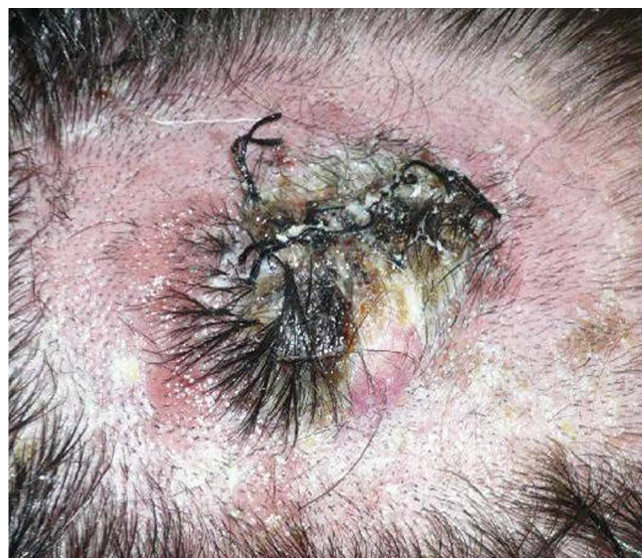


Figure 1 Fast-growing tuberous lesion in the left parietal region.

[☆] Please cite this article as: Carrascosa R, Solano-López GE, Vargas E, Fraga J. Carcinoma espinocelular en un paciente inmunosuprimido en tratamiento con voriconazol. *Actas Dermosifiliogr.* 2014;105:424–426.