




ACTAS Derma-Sifiliográficas

Full English text available at
www.actasdermo.org



VIDEOS OF SURGICAL PROCEDURES IN DERMATOLOGY

Partial Nail Matricectomy with Carbon Dioxide Laser[☆]



Matricectomía ungueal parcial con láser de CO₂

H.A. Cocunubo-Blanco,^{*} B. González-Sixto, G. Pérez-Paredes, M.Á. Rodríguez-Prieto

Servicio de Dermatología, Complejo Asistencial Universitario de León, León, Spain

Introduction

Onychocryptosis is a very common disorder. It carries a high morbidity due to the associated pain and inflammation that interfere with normal daily activities. Its treatment can be conservative, which often does not achieve the desired result, or surgical, which is more effective as it is designed to eliminate the part of nail matrix that produces the ingrowing nail plate.¹ One of the surgical techniques used is partial matricectomy with carbon dioxide (CO₂) laser, first described in 1980. This technique produces accurate, targeted ablation of the nail matrix.²

We describe the case of a middle-aged woman with no past history of interest. She presented longstanding ingrowth of the medial border of the nail of the right great toe. The associated pain limited her mobility and she reported recurrent episodes of inflammation.

Description of the Procedure

Antisepsis is performed with 0.5% chlorhexidine.

The toe is anesthetized by nerve block of the digital nerves, which run laterally, with the injection of 2 mL of 2% mepivacaine without epinephrine to each side of the toe.

The patient is left for 15 to 20 minutes for the anesthesia to take effect.

A tourniquet is applied. The nail fold and the ingrown nail plate are then incised using a CO₂ laser in superpulse mode at 5 watts (Fig. 1).

The incised nail fragment is detached and removed with the aid of artery forceps. The area of the nail matrix and nail bed corresponding to the ingrown nail is photocoagulated with the same laser in continuous mode at 2.5 watts.

Two hemostatic sponges are placed on the surgical wound and covered with mupirocin ointment and a sterile gauze dressing.

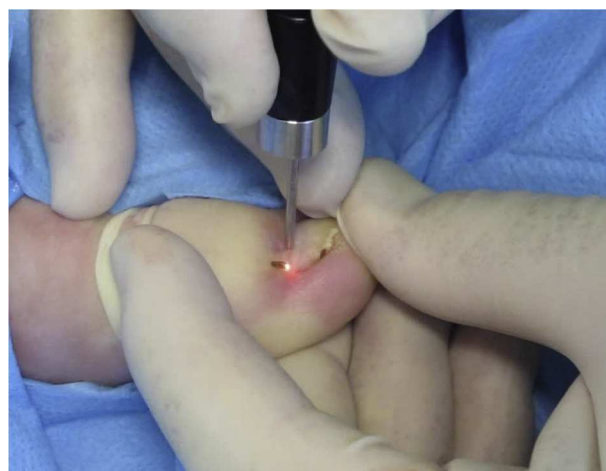

Figure 1 Partial nail matricectomy with carbon dioxide laser.

[☆] Please cite this article as: Cocunubo-Blanco H, González-Sixto B, Pérez-Paredes G, Rodríguez-Prieto M. Matricectomía ungueal parcial con láser de CO₂. 2014;105:418–419.

^{*} Corresponding author.

E-mail address: hacb27@hotmail.com (H.A. Cocunubo-Blanco).

Finally, it must not be forgotten to remove the tourniquet.

Indications

This technique is indicated for the treatment of nail deformities such as ingrown nail (onychocryptosis), onychogryphosis, pincer nail, and poor nail alignment.

Contraindications

Absolute: None.

Relative: Peripheral arterial disease and infections.

Benefits

This is a rapid technique with minimal risks and there is little pain or inflammation. The need for sutures is avoided and the technique can be used in patients with pacemakers and those on anticoagulant therapy.

Complications

The complications include wound infection, recurrence, and permanent nail changes due to a poor technique.

Alternatives

Alternative techniques are lateral matricectomy with/without phenolization,³ lateral matricectomy with electrocoagulation, and en bloc excision of the lateral part of nail plate.

Conclusions

CO₂ laser has been widely used for the treatment of dermatological conditions, including alterations of the nail unit. Its

use in partial matricectomy provides a rapid technique that is easy to perform and has practically no contraindications. Damage to surrounding tissues is minimal, and there is little bleeding or inflammation. In addition, the antiseptic effect of CO₂-laser photocoagulation reduces the risk of infection, thus favoring healing and early reinitiation of the patient's usual activities.⁴ The rates of recurrence and of the appearance of spicules reported in the literature are below 7%.^{4,5} We therefore consider that partial matricectomy with CO₂ laser is a suitable option for the treatment ingrown nail and that it offers good functional and cosmetic results.

Conflicts of Interest

The authors declare that they have no conflicts of interest.

Appendix A. Supplementary data

Supplementary data associated with this article can be found, in the online version, at <http://dx.doi.org/10.1016/j.adengl.2013.11.005>.

References

1. Eekhof JA, Van Wijk B, Knuistingh Neven A, Van der Wouden JC. Interventions for ingrowing toenails. *Cochrane Database Syst Rev*. 2012;18:4.
2. Ozawa T, Nose K, Harada T, Muraoka M, Ishii M. Partial matricectomy with a CO₂ laser for ingrown toenail after nail matrix staining. *Dermatol Surg*. 2005;31:302–5.
3. Fernández I, Blázquez N, de Troya M. Matricetomía química con fenol. *Actas Dermosifiliogr*. 2013;104:79–80.
4. Orenstein A, Goldan O, Weissman O, Tamir J, Winkler E, Klatzkin S, et al. Comparison between CO₂ laser surgery with and without lateral fold vaporization for ingrowing toenails. *J Cosmet Laser Ther*. 2007;9:97–100.
5. Andre P. Ingrowing nails and carbon dioxide laser surgery. *J Eur Acad Dermatol Venereol*. 2003;17:288–90.