




ACTAS Derma-Sifiliográficas

Full English text available at
www.actasdermo.org



VIDEOS OF SURGICAL PROCEDURES IN DERMATOLOGY

Auricular Chondro-Perichondrial Graft in the Reconstruction of the Lower Eyelid[☆]



Injerto condro-pericóndrico auricular en la reconstrucción del párpado inferior

M.M. Otero Rivas,* H.A. Cocunubo Blanco, B. González Sixto, M.Á. Rodríguez Prieto

Servicio de Dermatología, Complejo Asistencial Universitario de León, León, Spain

Introduction

The most common tumor of the eyelids is basal cell carcinoma. At this site, excision can be performed using Mohs micrographic surgery. Reconstruction of the upper or lower eyelids is a challenge due to their structural complexity and their important function.

The eyelid has classically been divided into the anterior lamella, comprising skin, subcutaneous cellular tissue, and the orbicularis oculi muscle, and the posterior lamella, comprising the tarsus and the palpebral conjunctiva. In the posterior lamella, the tarsus provides fibrous and cartilaginous support to the eyelid as it is anchored to the periosteum of the orbit medially and laterally by the canthal ligaments. Successful eyelid reconstruction requires the repair of both subunits.¹

At the present time, the techniques most widely used for the reconstruction of full-thickness defects of the posterior lamella of the lower eyelid are divided into tarsoconjunctival flaps, chondromucosal grafts, and chondroperichondrial

grafts. All these can be combined with skin flaps or grafts for reconstruction of the anterior lamella.²

The classic Hughes flap, a tarsoconjunctival flap, merits special mention. This transposition flap from the upper eyelid is indicated for $\frac{1}{2}$ to $\frac{3}{4}$ defects of the lower eyelid. Larger defects would lead to unacceptable morbidity of the upper eyelid. In lateral or medial defects of the lower eyelid, a semicircular myocutaneous advancement flap or Tenzel flap can be used; by releasing the lateral canthus, this method allows direct closure of the defect with identical tissue. Neither of the above flaps would have been flaps of choice in our case due to the size and site of the defect.³

In the case of chondromucosal grafts, possible donor sites are the nasal septum and the hard palate, though both options are technically more complex and carry a higher morbidity.¹

The auricular chondroperichondrial graft, using tissue obtained from the concha of the ear (from the posterior aspect of the concha in our case), is a relatively simple surgical technique and produces minimal morbidity at the donor site. Furthermore, the auricular cartilage is easily shaped and it prevents to some extent the postsurgical retraction of the skin flap that is chosen.²

Technique

We describe the case of a 67-year-old patient with no past medical history of interest, who presented recurrence of

[☆] Please cite this article as: Otero Rivas M, Cocunubo Blanco H, González Sixto B, Rodríguez Prieto M. Injerto condro-pericóndrico auricular en la reconstrucción del párpado inferior. Actas Dermosifiliogr. 2014. 105:307–309.

* Corresponding author.

E-mail address: motero@aedv.es (M.M. Otero Rivas).

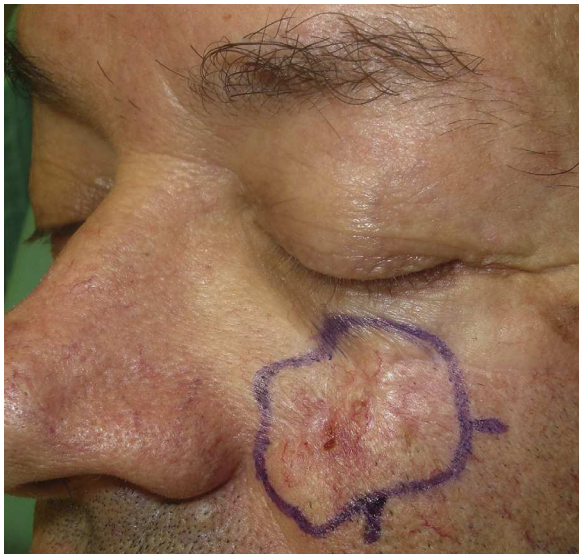

Figure 1 A recurrent sclerodermiform basal cell carcinoma on the scar of a previous operation.

a basal cell carcinoma affecting the malar region and left lower eyelid. Physical examination revealed a sclerotic, infiltrated plaque with poorly defined borders located in the upper left malar region, adjacent to the ala nasi and to the lower eyelid (Fig. 1).

Eight stages of Mohs micrographic surgery left a surgical defect involving the mid cheek, a large part of the lower eyelid, including the tarsus, and the left side of the dorsum of the nose (Fig. 2). The medial canthus and the lacrimal apparatus were preserved.

The video shows the reconstruction of the defect under local anesthesia. After placement of the auricular chondroperichondral graft, the anterior lamella of the eyelid and the rest of the surgical defect were reconstructed using a labial advancement flap.

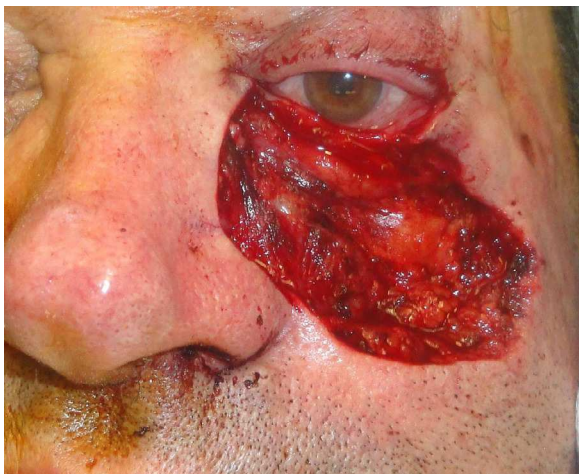

Figure 2 Surgical defect after 8 stages of Mohs micrographic surgery. Despite the absence of the tarsus, it was possible to preserve part of the palpebral conjunctiva, the medial canthus, and the lacrimal apparatus.

Indications

This technique is indicated for the reconstruction of full-thickness defects of the lower eyelid that cannot be closed by direct suture.

Contraindications

A relative contraindication is when the conjunctiva is not preserved. Even though this type of chondroperichondral graft shows rapid re-epithelialization, troublesome corneal irritation can develop, though it is usually transitory.

Complications

- Surgical wound infection affecting the eyelid or ear (chondritis).
- Necrosis of the cartilaginous graft.
- Edema, hematoma, or distal necrosis of the advancement flap on the cheek.
- Postsurgical ectropion due to unpredictable wrapping of the cartilage.

Alternatives

- The Hughes tarsoconjunctival flap. This requires a second operation, with the eye remaining covered in the interval between operations. It must be combined with a graft or flap for reconstruction of the anterior lamella. The defect in our patient was too large to use tissue from the upper eyelid.
- The Mustardé cheek rotation flap. As in our case, the posterior lamella must be reconstructed with a cartilage graft or a tarsoconjunctival flap.⁴
- Mucosal plus periosteal/perichondrial graft from the hard palate/nasal septum. These are both excellent options, but obtaining the material is laborious and there is considerable postoperative pain. There are certain significant risks, such as iatrogenic perforation or nasal collapse.
- Island nasal chondromucosal flaps. These are relatively complex techniques. The blood supply to the flap comes from a terminal branch of the dorsal nasal artery. Septal chondromucosal flaps have also been described. After dissection of the flaps, they are tunneled to their final position on the lower eyelid. Despite donor site morbidity, it is true that these flaps provide a sufficient quantity of similar tissue for full-thickness reconstruction without damaging the upper eyelid. Their main disadvantages, apart from those mentioned, are a trap door effect of the flap that can affect functional and cosmetic outcomes, and the need for a second operation.⁵
- Autologous/homologous fascia lata. Homologous fascia lata carries a risk of transmission of infectious diseases (human immunodeficiency virus, hepatitis, Creutzfeld-Jacob disease).³ In the case of autologous fascia lata, the main problems come from the difficulty of obtaining the tissue.⁴

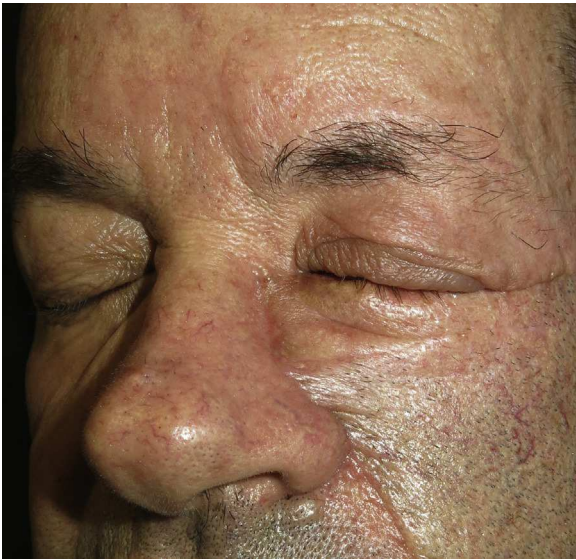

Figure 3 Two months after surgery. Function was good and there was an acceptable cosmetic appearance.

Conclusions

There are certain sites in the body that can be a challenge to the dermatologic surgeon; the eyelids are one of these sites. The need to provide adequate support to this structure requires complex techniques that may not always be familiar to the surgeon.

In our case, through a laborious reconstruction using a known and simple technique that required a single surgical intervention,² we performed reconstruction of the lower eyelid with a good functional and cosmetic outcome (Fig. 3).

We believe it useful to publish a description of the use of conchal cartilage for full-thickness defects of the lower

eyelid as, after completing the oncologic surgery, in our opinion it should be the dermatologist who performs the reconstruction.

Conflicts of Interest

The authors declare that they have no conflicts of interest.

Acknowledgments

We would like to thank José Lavigne Pérez for the audiovisual production.

Appendix A. Supplementary data

Supplementary data associated with this article can be found in the online version at <http://dx.doi.org/10.1016/j.adengl.2013.11.001>.

References

1. Sassoan EM, Codner MA. Eyelid reconstruction. *Operative techniques in plastic and reconstructive surgery*. 1999;6:250–64.
2. Parodi PC, Faini G, de Biasio F, Rampino Cordaro E, Guarneri GF, et al. Full-thickness lower eyelid reconstruction with a conchal chondro-perichondral graft and local coverage with myocutaneous flaps—our divisional experience. *J Oral Maxillofac Surg*. 2008;66:1826–32.
3. Chandler DB, Gausas RE. Lower eyelid reconstruction. *Otolaryngol Clin North Am*. 2005;38:1033–42.
4. Alghoul M, Pacella SJ, McClellan WT, Codner MA. Eyelid reconstruction. *Plast Reconstr Surg*. 2013;132:288e–302e.
5. Zhao Z, Li S, Yan Y, Li Y, Yang M, Li D, et al. The septal chondromucosal island pedicle flap: Anatomic study and clinical application. *Plast Reconstr Surg*. 1999;103:1355–60.