

with eyedrops producing better cosmetic results and less destruction of limbal stem cells.<sup>10</sup>

While we found no mention of this treatment in the dermatological literature, several ophthalmologic publications describe the effectiveness of topical IFN alfa-2b in cases of viral warts, intraepidermal carcinomas, and even melanomas on the eyelids and ocular surface, although these results are described in small series or isolated cases and should thus be interpreted with caution. We found no other cases in which IFN alfa-2b eyedrops have been used in the management of BCC of the eyelid. BCC is an accepted indication for IFN alfa-2b, and our findings point to a new potential route of administration. In our case the volume of the tumor decreased considerably, and the patient remains clinically stable after 3 years. However, we have no objective evidence of resolution, which requires close monitoring in a clinical setting. Our isolated experience should in no way change the standard accepted approaches used for the management of nonmelanoma skin cancer. Controlled clinical trials will be necessary to definitively determine the effectiveness of this treatment. However, given its ease of administration and its few, mild side effects, we propose the use of IFN alfa-2b eyedrops as a neoadjuvant therapy in selected cases to reduce tumor size before microscopically controlled surgical excision.

## References

1. Lee BJ, Nelson CC. Intralesional interferon for extensive squamous papilloma of the eyelid margin. *Ophtal Plast Reconstr Surg.* 2012;28:e47-8.
2. Shields CL, Kancherla S, Bianciotto CG, Lally SE, Shields JE. Ocular surface squamous neoplasia (squamous cell carcinoma) of the socket: Management of extensive tumors with interferon. *Ophtal Plast Reconstr Surg.* 2011;27:247-50.
3. Fenton S, Kennedy S, Moriarty P. The role of interferon alpha 2b as an adjunctive treatment in the management of aggressive basal cell carcinoma of the eyelids. *Acta Ophthalmol Scand.* 2002;80:674-5.
4. Schechter BA, Rand WJ, Velazquez GE, Williams WD, Starasoler L. Treatment of conjunctival papillomata with topical interferon alfa-2b. *Am J Ophtalmol.* 2002;134:268-70.
5. Finger PT, Sedeeek RW, Chin KJ. Topical interferon alfa in the treatment of conjunctival melanoma and primary acquired melanosis complex. *Am J Ophtalmol.* 2008;145:124-9.
6. Galor A, Karp CL, Chhabra S, Barnes S, Alfonso EC. Topical interferon alpha 2 b eye-drops for treatment of ocular surface squamous neoplasia: A dose comparison study. *Br J Ophtalmol.* 2010;94:551-4.
7. Schechter BA, Schrier A, Nagler RS, Smith EF, Velazquez GE. Regression of presumed primary conjunctival and corneal intraepithelial neoplasia with topical interferon alpha-2b. *Cornea.* 2002;21:6-11.
8. Shields CL, Kaliki S, Kim HJ, Al-Dahmash S, Shah SU, Lally SE, et al. Interferon for ocular surface squamous neoplasia in 81 cases: Outcomes based on the American Joint Committee on Cancer Classification. *Cornea.* 2013;32:248-56.
9. Verdaguer P, Fideliz de la Paz M, Álvarez de Toledo JP, Barraquer RI. Interferón alfa-2b, queratectomía parcial y trasplante de membrana amniótica para el tratamiento de un carcinoma escamoso conjuntival recidivante. *Arch Soc Esp Oftalmol.* 2011;86:154-7.
10. Huerva V. Interferón alfa-2b tópico o escisión quirúrgica como tratamiento primario de la neoplasia conjuntival intraepitelial. *Arch Soc Esp Oftalmol.* 2009;84:5-6.

V.M. Leis-Dosil,\* I. Prats-Caelles, C. Rubio-Flores

*Sección de Dermatología, Hospital Universitario Infanta Sofía, San Sebastián de los Reyes, Madrid, Spain*

\* Corresponding author.

*E-mail address: vmanuel.leis@salud.madrid.org (V.M. Leis-Dosil).*

## Aseptic and Alopecic Nodules of the Scalp<sup>☆</sup>

### Nódulos asépticos y alopécicos del cuero cabelludo

*To the Editor:*

Alopecic and aseptic nodules of the scalp (AANS), also known as pseudocyst of the scalp, is a new, little known, and probably underdiagnosed entity.

AANS was first described in the Japanese literature in 1992.<sup>1</sup> The condition was described as pseudocyst of the scalp because histologic examination revealed cyst-like cavities lacking a true cystic wall.<sup>1</sup> The first cases in Western populations were reported by Chevallier and coworkers<sup>2</sup> in 1998, who described the lesions as non-infectious and

alopecic scalp abscesses. In 2009, Abdennader and colleagues introduced the term "alopecic and aseptic nodules of the scalp", as they failed to consistently find the cystic cavities described in the Japanese studies.<sup>3,4</sup> About 70 cases have been described to date; these are listed in [Table 1](#).

## Case Description

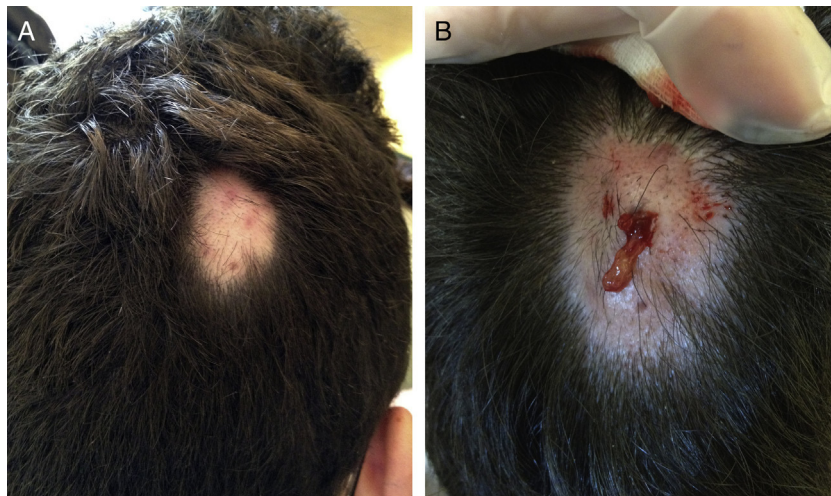
We report the case of a 16 year-old male with an asymptomatic alopecic plaque on the right parietal region of the scalp. A soft, domed, erythematous, and slightly alopecic nodule of 3 cm in diameter surrounded by normal scalp was palpable on examination ([Fig. 1](#)). Biopsy showed an inflammatory lesion in the mid and deep dermis composed of granulation tissue, edema, reactive angioproliferation, and non-confluent granulomas, some with giant cells and others with central abscess formation ([Fig. 2](#)). Specific staining for microorganisms with Periodic acid Schiff (PAS), silver, Giemsa, and Ziehl-Neelsen was negative, as were mycological and bacteriological cultures. Treatment was initiated

<sup>☆</sup> Please cite this article as: Fischer-Levancini C, Iglesias-Sancho M, Collgros H, Sánchez-Regaña. M. Nódulos asépticos y alopécicos del cuero cabelludo. *Actas Dermosifiliogr.* 2014;105:208-211.

**Table 1** Summary of the Main Features of this Entity Described in the Literature.

Authors	Number of cases	Age	Gender	Race/ethnicity	Number of nodules	Location	Histopathology	Treatment
Iwata et al., <sup>1</sup> 1992	19	18-40	14 M 5 F	Asian	1	Parietal and frontal	Pseudocyst+ granuloma	Aspiration+ intralesional corticosteroid injection (10/19)
Chevallier, <sup>2</sup> 1998	3	17-35	2 M 1 F	White	1	NS	Follicular cyst+ granuloma	Repeated puncture
Tsuruta et al., <sup>8</sup> 2005	4	20-29	2 M 1 F	Asian	1	Parietal and vertex	Pseudocyst+ granuloma	Surgical excision
Tsuruta, <sup>9</sup> 2009	2	15 36	1 M 1 F	Asian	5 3	NS	NS	Improvement after biopsy (1) Intralesional corticosteroid injection (1)
Abdennader and Reygagne, <sup>3</sup> 2009	18	12-38	18 M	White	≤ 2	Vertex and superior occipital	Inflammatory infiltrate in reticular and deep dermis +deep dermal granulomas	Doxycycline, 100 mg/d
Abdennader et al., <sup>4</sup> 2011	15	18-49	14 M 1 F	11 White 4 Black	1 (6) 2 (5) 3 (3) 6 (1)	Occipital and vertex	Inflammatory infiltrate in reticular and deep dermis, with deep dermal granulomas in < 50% of patients	Doxycycline, 100 mg/d for 3 months
Sang Sing et al. <sup>6</sup> 2011	1	72	F	Asian	1	Temporal	Pseudocyst	Surgical excision
Eisenberg, <sup>5</sup> 2012	11	16-48	3 F 8 M	5 White 1 Hispanic 2 Arab 2 Black 1 Asian	1 (10) 2 (1)	Vertex (10) Occipital (1)	NS	Puncture and corticosteroid infiltration (triamcinolone acetonide, 2.5 mg/mL)

We are aware of the following 3 articles published in the Japanese literature, the originals of which are unavailable: Nukaga Y, Matsuura K, Matsushima Y. A case of pseudocyst of the scalp. *Hifu Rinsho* (Tokyo). 1995;37:1772-1773; Shibagaki N, Sugiyama H, Ohtake N, Furue M, Shimada S. Analysis of 3 cases of inflammatory granulomatous nodule with pseudocyst associated with follicular occlusion triad -Pseudocystic granuloma of skin. *Jpn J Clin Dermatol*. 1996, 50:105-110; Aiba S, Mukai H. Pseudocyst of the scalp. *Pract Dermatol*. 2002;24:893-6. Abbreviation: NS, Not specified.

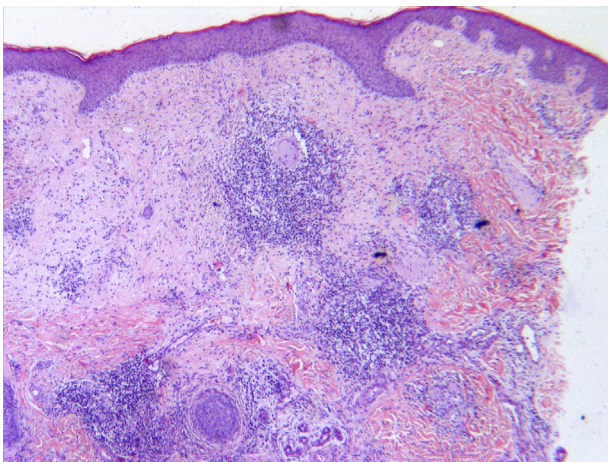


**Figure 1** A, Clinical appearance of alopecic nodule of the scalp. B, Drainage of yellowish material after puncture.

with doxycycline (100 mg/d). Puncture of the lesion 2 weeks later revealed a yellowish orange material. After completing 2 months of treatment, the lesion resolved without scarring alopecia. No recurrence was observed after 5 months.

### Comments and Conclusions

This condition most often affects young males and presents as alopecic, dome-shaped nodules surrounded by normal skin; it can be asymptomatic or cause occasional discomfort.<sup>2,4</sup> Hair loss coincides with the formation of the nodules, which are located mainly at the vertex, but can occur in any area of the scalp. Usually 1 to 2 nodules develop as an isolated event, although some cases involve recurring nodules<sup>5</sup>; the nodules heal without causing scarring alopecia.



**Figure 2** Histopathology: inflammatory lesion in the mid and deep dermis consisting of granulation tissue, edema, reactive angioproliferation, and mixed inflammatory infiltrate, with non-confluent granulomas, some with giant cells and others with central abscess formation (hematoxylin eosin, original magnification  $\times 20$ ).

When material is obtained on puncturing the nodule, it can be serous, purulent, or yellowish, depending on the characteristics of the infiltrate and the type of vessel eroded by the infiltrate; yellow indicates erosion of a lymph vessel, as in the present case; pink indicates erosion of a blood vessel; and purulent material indicates the predominance of polymorphonuclear infiltrate.<sup>4</sup> Cultures are negative in all cases.

Histologically these nodules exhibit mixed inflammatory infiltrates (lymphocytes, histiocytes, and giant cells) and in most cases granulomas in the deep dermis or pseudocyst-like architecture without a true wall. Histological differences are thought to be due to race-related differences in hair type or the comparison of superficial with nonsuperficial samples.<sup>4</sup>

These nodules respond well to treatment with doxycycline (100 mg/d),<sup>4</sup> intralesional corticosteroids,<sup>5</sup> and aspiration or drainage of the nodule.<sup>2</sup> Cases of spontaneous regression have been described,<sup>5</sup> and in general surgical excision is not necessary.

While the etiology of AANS is unknown, it is considered to be a type of deep folliculitis secondary to follicular occlusion or a foreign body reaction. It is characterized by a granulomatous reaction with inflammatory infiltrate composed of lymphocytes, histiocytes, and giant cells. Subsequent central necrosis and erosion of blood and lymph vessels results in exudate production and pseudocyst formation. Some authors have suggested that AANS may lie within the spectrum of diseases associated with follicular occlusion, although immunological processes cannot be ruled out.<sup>3,6</sup>

Differential diagnosis with superinfected trichilemmal cyst, alopecia areata, bacterial and dermatophyte folliculitis, metastasis, and dissecting cellulitis should be established. Dissecting cellulitis, unlike AANS, presents clinically as multiple, painful, erythematous nodules, which form abscesses that fistulize and cause scarring alopecia.<sup>7</sup>

We agree with Abdennader and coworkers that alopecic and aseptic nodules of the scalp and pseudocyst of the scalp are the same entity, the former being a more appropriate name, as the nodules are always alopecic, the material obtained on puncturing the nodule is sterile, and



histopathology does not always reveal pseudocysts.<sup>4</sup> However, Sang Sing and coworkers<sup>6</sup> argue that the 2 are distinct conditions, as biopsies reveal pseudocysts in the latter but not in the former.

In conclusion, AANS is an emerging entity in the literature, is relatively unknown, and thus is likely underdiagnosed. It is diagnosed by the presence of alopecic, aseptic nodules on the scalp and the absence of scarring alopecia. In general, it is easily managed and responds well to treatment. A better understanding of this condition is necessary for proper treatment and to avoid unnecessary interventions.

## Acknowledgements

We thank Dr. Roger Llatjos and Dr. Valeri Novell of the Pathology Laboratory, BCN Patòlegs, Barcelona.

## References

1. Iwata T, Hashimoto T, Niimura M. A pseudocyst with inflammatory granulation tissue on scalp -pseudocyst of scalp. *Jpn J Clin Dermatol.* 1992;46:9–16.
  2. Chevallier J. Abcès non infectieux et alopéciques du cuir chevelu: nouvelle entité? *Nouv Dermatol.* 1998;17:181.
  3. Abdennader S, Reygagne P. Alopecic and aseptic nodules of the scalp. *Dermatology.* 2009;218:86.
  4. Abdennader S, Vignon-Pennamen MD, Hatchuel J, Reygagne P. Alopecic and aseptic nodules of the scalp (pseudocyst of the scalp): a prospective clinicopathological study of 15 cases. *Dermatology.* 2011;222:31–5.
  5. Eisenberg EL. Alopecia-associated pseudocyst of the scalp. *J Am Acad Dermatol.* 2012;67:e114–6.
  6. Lee SS, Kim SY, Im M, Lee Y, Seo YJ, Lee JH. Pseudocyst of the scalp. *Ann Dermatol.* 2011;23:s267–9.
  7. Gutierrez Rodriguez MC, Marino Harrison JM. Nódulos inflamatorios y alopecia en el cuero cabelludo. *Piel.* 2003;18:270–2.
  8. Tsuruta D, Hayashi A, Kobayashi H, Nakagawa K, Furukawa M, Ishii M. Pseudocyst of the scalp. *Dermatology.* 2005;210:333–5.
  9. Tsuruta D. Reply letter. *Dermatology.* 2009;218:87.
- C. Fischer-Levancini,\* M. Iglesias-Sancho, H. Collgros, M. Sánchez-Regaña.
- Servicio de Dermatología, Hospital Universitari Sagrat Cor, Unidad Docente de la Universidad de Barcelona, Barcelona, Spain*
- \*Corresponding author.  
E-mail address: [cfischer2@hotmail.com](mailto:cfischer2@hotmail.com)  
(C. Fischer-Levancini).

## Oral Hyperpigmentation Associated With Interferon-Alpha and Ribavirin Therapy for Hepatitis C Virus Infection<sup>☆</sup>

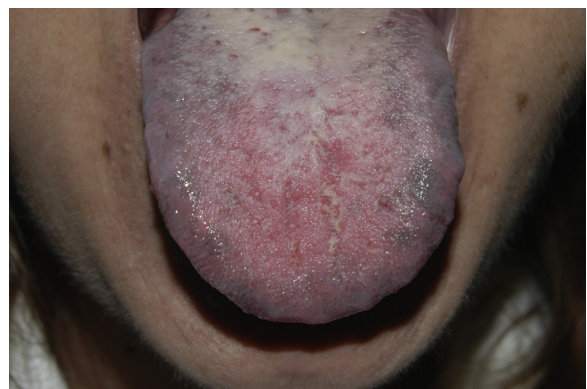### Pigmentación oral asociada al tratamiento con alfa-interferón y ribavirina para la hepatitis c

To the Editor:

Since 2003, there have been reports of oral hyperpigmentation associated with interferon alfa and ribavirin therapy for hepatitis C. We report a new case of oral pigmentation associated with this therapy in a white woman who also developed genital mucosal lesions. The patient was 49 years old and had a history of allergy to acetylsalicylic acid, depressive disorder, and chronic hepatitis C genotype 1 infection, diagnosed in 2007. In May 2008, she started treatment with pegylated interferon alfa and ribavirin with suboptimal therapeutic adherence until November 2009. The virus was not eradicated. In June 2010, the patient presented with leukocytoclastic vasculitis and arthralgia associated with cryoglobulinemia, and received treatment with colchicine and pulses of oral prednisone. From April 2011, she underwent 5 sessions of plasmapheresis and treatment with pegylated interferon alfa (180 µg/week) and ribavirin (1000 mg/d) was restarted. In July 2011, she received treatment with rituximab (2 doses) with resolu-

tion of the leukocytoclastic vasculitis. In April 2011, 1 month after the start of the second course of pegylated interferon alfa and ribavirin, the patient presented with a burning sensation on the tongue and noted pigmentation of the oral and genital mucosa. In the examination, pigmented grey-blue macules were seen located mainly on the lateral areas of the dorsum of the tongue (Fig. 1). Pigmentation was also observed on both cheek mucosae (Fig. 2) and similar lesions were detected on the vulvar mucosa. The patient did not have any hyperpigmented cutaneous lesions, and no systemic symptoms were apparent at the time. Withdrawal of treatment was not required and the lesions have remained stable until present, despite continuing with treatment.

Hyperpigmentation of oral mucosa associated with interferon alfa and ribavirin combination therapy for hepatitis C



**Figure 1** Pigmented grey-blue macules, located mainly on the lateral areas of the dorsum of the tongue.

<sup>☆</sup> Please cite this article as: Marcoval J, Notario J, Martín C, Gómez S. Pigmentación oral asociada al tratamiento con alfa-interferón y ribavirina para la hepatitis c. *Actas Dermosifiliogr.* 2014;105:211–212.