

CASE AND RESEARCH LETTERS

Papular Mycosis Fungoides on the Legs: A Case Report[☆]

Micosis fungoide papular en las piernas, a propósito de un caso

We present the case of a 55-year-old man who came to our clinic with asymptomatic lesions on the legs that had appeared gradually over the previous year. The patient had no personal history of interest and was not taking medication. Physical examination revealed nonfollicular erythematous papules measuring 1 to 2 mm that were distributed symmetrically on the anterior and internal aspects of the legs (Fig. 1). Some were covered with fine whitish scale (Fig. 2). The lesions were isolated and did not coalesce to form plaques.

The lesions on the anterior surface of the legs were biopsied, and the results revealed lymphocyte aggregates in the superficial dermis (Fig. 3A) interspersed with infiltrate-free areas. The infiltrate was composed of atypical small-to-medium lymphocytes, with an irregular nucleus. There was marked epidermotropism (Fig. 3B and C), and isolated areas of the basement membrane had been destroyed. Immunohistochemistry (Fig. 3D) revealed a particularly intense infiltrate composed of CD3⁺ and CD4⁺ cells, with less intense staining of CD8⁺ cells and CD30⁻ cells. The hair follicles and eccrine glands were not involved, and no dermal mucin deposits were found. Polymerase chain reaction assay of gene rearrangement in the T-cell receptor from the skin biopsy revealed monoclonal T-cell proliferation. These findings confirmed a diagnosis of papular mycosis fungoides.

Laboratory tests disclosed mild hypercholesterolemia; the remaining values, including lactate dehydrogenase and β 2-microglobulin were within the reference range. There were no palpable lymph nodes in the groin or axillas. Chest radiograph and abdominal ultrasound findings were normal.

The patient was treated with high-potency local topical corticosteroids (clobetasol cream 0.05%) once daily for 3 weeks. Since his condition improved only slightly, treatment with psoralen-UV-A (PUVA) (18 sessions) was started (oral methoxsalen at 20 mg before PUVA). The cutaneous symptoms disappeared almost completely with this treatment.

[☆] Please cite this article as: Santamarina-Albertos A, Muñoz-Martínez R, Alvarez-Gago T, Miranda-Romero A. Micosis fungoide papular en las piernas, a propósito de un caso. Actas Dermosifiliogr. 2014;105:87–89.

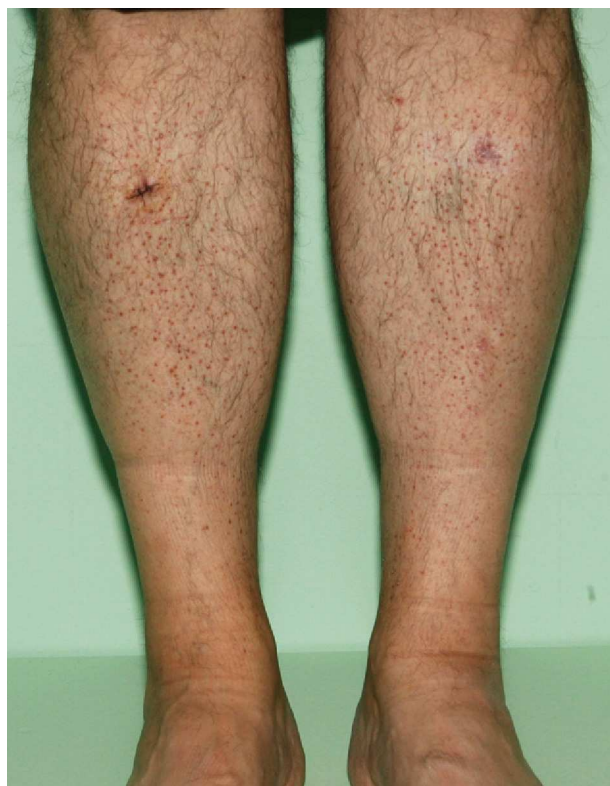

Figure 1 Reddish papules distributed symmetrically on the legs.

Today, 18 months later, the patient is free of lesions and other signs of mycosis fungoides.

Mycosis fungoides is considered to be the most common form of cutaneous T-cell lymphoma. It tends to take the form of blotches that appear on areas of the body usually not exposed to sunlight. However, the clinical manifestations of mycosis fungoides vary considerably,¹ and up to 50 variants have been described.² One such variant is papular mycosis fungoides, an uncommon entity first described by Kodama et al.³ in 2005; only 11 cases have been published in the literature.

Mycosis fungoides usually presents as an asymptomatic persistent eruption of reddish papules generally affecting the trunk in middle-aged patients. The clinical, histopathological, and immunohistochemical findings in our case are similar to those reported for previously published cases.^{3–7} All those authors^{3–6} concur that this presentation of mycosis

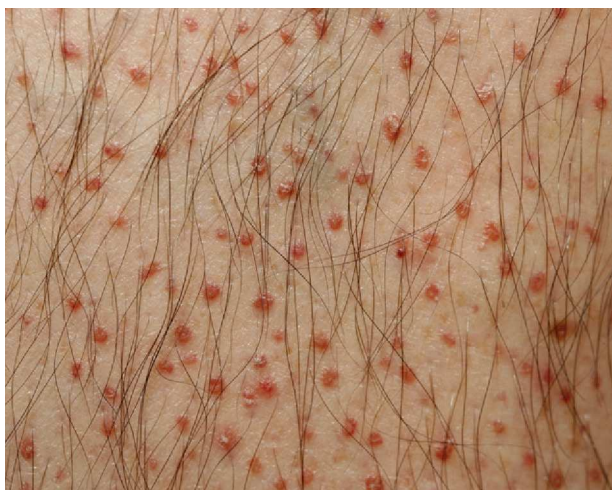

Figure 2 Detail of the skin surface showing red papules, some of which are covered with scales.

fungoides is not very aggressive but also agree that patients should be followed up, because in 1 case it has been reported to progress to plaque-phase mycosis fungoides.³ Prognosis is favorable in this subtype, except in patients with previous symptoms of mycosis fungoides, in whom it indicates disease progression.⁵

The differential diagnosis can be made with lymphomatoid papulosis, especially type B,^{3-5,8} which usually manifests with ulcerated and crusted lesions that tend to resolve spontaneously. It can also be made with pityriasis lichenoides et varioliformis acuta and pityriasis lichenoides chronica, both of which usually yield intraepidermal neutrophils and necrotic keratinocytes⁵ in the histopathology study. Diagnosis can even be made with follicular mycosis fungoides, which is characterized by infiltrate in the follicular epithelium, a certain degree of syringotropism, or both.⁹ Neri et al.⁷ proposed a differential diagnosis with aggressive epidermotropic CD8 cytotoxic T-cell lymphoma, after detecting an infiltrate composed of CD8⁺CD4⁻ cells in the case of papular mycosis fungoides they report.

The main therapeutic option for papular mycosis fungoides is PUVA, which is generally successful.^{3,5} Other options that have been applied in the initial stages¹⁰ include coadjuvant topical retinoids,⁷ UV-B radiation,⁴ and topical corticosteroids in monotherapy.⁶ Given the good response with PUVA in the present case and the evidence provided by previously published cases (improvement in 8 out of 12 patients treated), we propose PUVA as the most appropriate alternative, although we do recognize that the small population could limit interpretation of our results.

Finally, we would like to highlight the wide clinical variability of mycosis fungoides, an entity that can go unnoticed and present in an unremarkable manner over several months as a papular eruption, which is often asymptomatic.

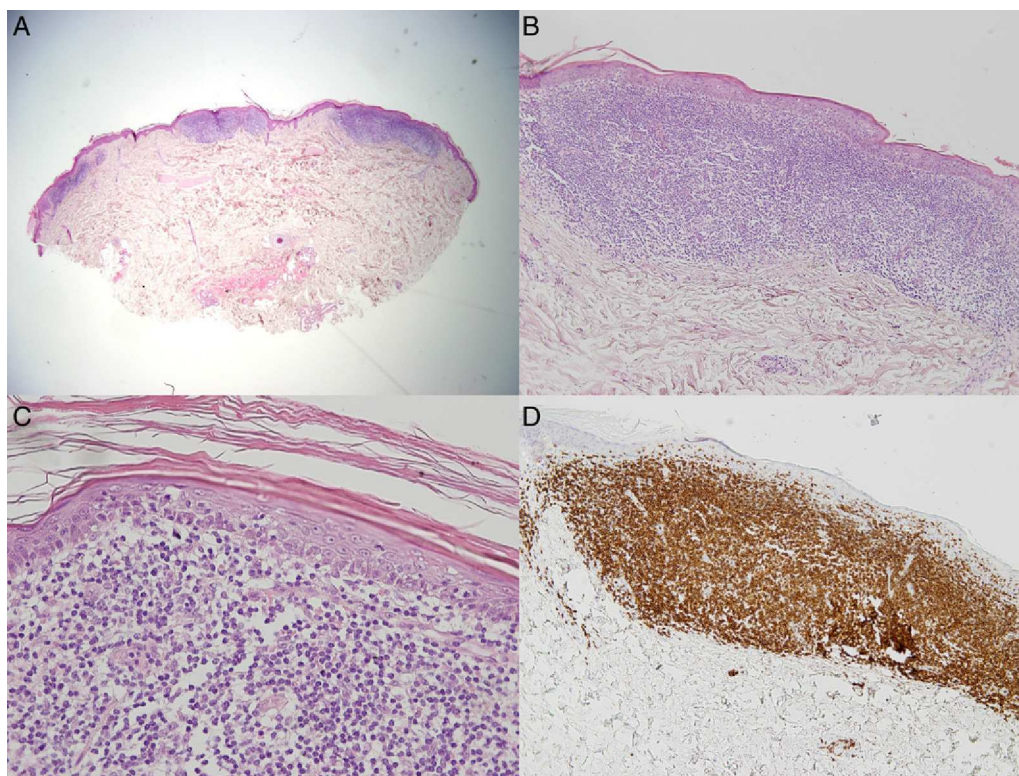


Figure 3 A, Focal lymphocytic infiltrates in the superficial dermis interspersed with infiltrate-free hypodermis and dermis (hematoxylin-eosin [H-E], original magnification $\times 2$). B, Detail of well-defined lymphocytic infiltrate in the dermis (H-E, original magnification $\times 10$). C, Small and medium atypical lymphocytes and visible epidermotropism (H-E, original magnification $\times 40$). D, CD3⁺ cells are visible throughout the infiltrate (CD3, original magnification, $\times 10$).

References

1. Kazakov DV, Burg G, Kempf W. Clinicopathological spectrum of mycosis fungoides. *J Eur Acad Dermatol Venereol*. 2004;18:397–415.
 2. Nashan D, Faulhaber D, Ständer S, Luger TA, Stadler R. Mycosis fungoides: A dermatological masquerader. *Br J Dermatol*. 2007;156:1–10.
 3. Kodama K, Fink-Puches R, Massone C, Kerl H, Cerroni L. Papular mycosis fungoides: a new clinical variant of early mycosis fungoides. *J Am Acad Dermatol*. 2005;52:694–8.
 4. Uddin A, Bennett M, Nayeem K, Marren P, Abushaira H. A case of papular mycosis fungoides: New clinical variant of early mycosis fungoides. *J Eur Acad Dermatol Venereol*. 2007;21:685–7.
 5. Martorell-Calatayud A, Botella-Estrada R, Sanmartín-Jimenez O, Requena C, Guillén-Barona C, Sangüeza OP. Papular mycosis fungoides: Two new cases of a recently described clinicopathological variant of early mycosis fungoides. *J Cutan Pathol*. 2010;37:330–5.
 6. Ze-Hu L, Yi-Ling W, Shu-Yue C, Jun-Hui Z, Gang Q, Hong S, et al. Papular mycosis fungoides: A new clinic variant of early and benign mycosis fungoides? *J Clin Oncol*. 2011;29:e381–3.
 7. Neri I, D'acunto C, Pileri A, Reggiani C, Patrizi A. Papular mycosis fungoides: a new case expanding the spectrum of phenotypical and clinical findings. *G Ital Dermatol Venereol*. 2011;146:505–7.
 8. Ackerman AB, Niven J, Grant-Kels JM. Lymphomatoid papulosis vs mycosis fungoides plaque stage. In: Ackerman AB, Niven J, Grant-Kels JM, editors. *Differential diagnosis in dermatopathology*. Philadelphia: Lea and Febiger; 1982. p. 158–65.
 9. Gómez-Diez S, Maldonado C, Fueyo A, Vázquez-López F, Fresno MF, Pérez-Oliva N. Micosis fungoide folicular. Estudio de cuatro casos. *Actas Dermosifiliogr*. 2007;98:486–90.
 10. Izu-Belloso RM, García-Ruiz JC. Actualización terapéutica en los linfomas cutáneos. *Actas Dermosifiliogr*. 2012;103:694–707.
- A. Santamarina-Albertos,^{a,*} R. Muñoz-Martínez,^a
T. Alvarez-Gago,^b A. Miranda-Romero^a
- ^a *Servicio de Dermatología, Hospital Clínico Universitario de Valladolid, Valladolid, Spain*
^b *Servicio de Anatomía Patológica, Hospital Clínico Universitario de Valladolid, Valladolid, Spain*
- *Corresponding author.
E-mail address: alba.santamarina@gmail.com
(A. Santamarina-Albertos).

Lichenoid Chronic Graft-vs-Host Disease Following Blaschko Lines[☆]

Enfermedad del injerto contra el huésped crónica liquenoide con patrón blaschkoide

Graft-vs-host disease (GVHD) is a clinical syndrome that occurs when immunocompetent donor cells attack various host tissues, with the skin, gastrointestinal tract, and liver being the main target organs.¹ The onset of skin involvement in chronic GVHD is usually more than 100 days posttransplant. Signs basically consist of lichenoid eruptions and sclerodermoid manifestations, although many other patterns have also been described.² We report a new case of lichenoid chronic GVHD following Blaschko lines.

A 16-year-old boy was seen for a pruritic, linear rash on his left upper limb and the trunk that had appeared 2 weeks earlier. The patient had previously been diagnosed with a blastic plasmacytoid dendritic cell neoplasm, which was in complete remission following chemotherapy and an allogeneic bone marrow transplant with complete hematopoietic chimerism. He also had a history of acute cutaneous and intestinal GVHD. At the time of consultation, 20 months after the transplant, the patient was on low doses of methylprednisolone and ciclosporin and reported no history of herpes zoster.

Physical examination revealed 2 linear eruptions on the left upper limb—1 posterointernal and 1

posteroexternal—extending from the shoulder to the distal part of the dorsum of the first, third, fourth, and fifth fingers, respectively, of the left hand. The patient also had 3 similar S-shaped lesions on the left hemithorax that followed Blaschko lines (Fig. 1, A-C). The lesions consisted of flat, erythematous-violaceous papules measuring 1 to 3 mm that tended to coalesce. The physical examination was otherwise unremarkable.

Biopsy of a papule revealed features suggesting lichenoid dermatitis (Fig. 2). The patient was diagnosed with lichenoid chronic GVHD following Blaschko lines and, because no extracutaneous involvement was present, high-potency topical corticosteroids were prescribed. The lesions resolved after 1.5 months, leaving a slight hyperpigmentation.

Given the presence of an acquired linear lichenoid eruption along Blaschko lines, we considered the following differential diagnoses: linear lichen planus, lichen striatus, inflammatory linear verrucous epidermal nevus, linear porokeratosis, and linear psoriasis.^{1,3–6} Nevertheless, given the patient's history of allogeneic bone marrow transplantation, localized lichenoid chronic GVHD was the first option.

Chronic cutaneous GVHD can follow 2 main patterns: lichenoid eruptions and sclerodermoid manifestations. Other, less frequent manifestations include xerosis, poikiloderma, keratosis pilaris, ichthyosis, psoriasiform lesions, palmoplantar eczema, erythroderma, exfoliative dermatitis, and manifestations that mimic other annular dermatoses such as pityriasis rosea, centrifugal annular erythema, erythema multiforme, and subacute lupus. Most patients present generalized lesions but localized linear lesions, both lichenoid and sclerodermoid, have also been reported. Some lesions follow Blaschko lines, whereas others—with or without a history of herpes zoster in the same area—follow a metamereric pattern.^{1–10}

[☆] Please cite this article as: Kennedy FE, Hilari H, Ferrer B, García-Patos V. Enfermedad del injerto contra el huésped crónica liquenoide con patrón blaschkoide. *Actas Dermosifiliogr*. 2014;105:89–92.